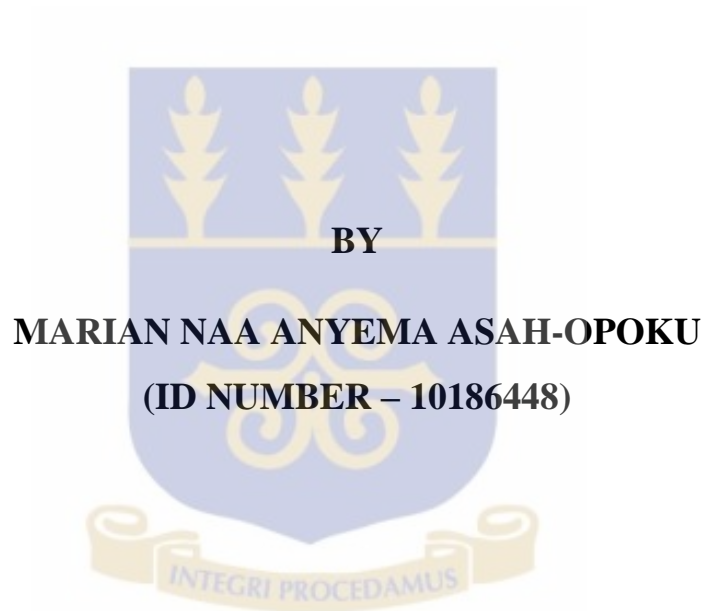


**UNIVERSITY OF GHANA
COLLEGE OF HEALTH SCIENCES**

**RENAL HISTOLOGY AND FUNCTION IN GENTAMICIN-
INDUCED ACUTE KIDNEY INJURY (AKI) IN RATS GIVEN
NATURAL COCOA**



**THIS THESIS IS SUBMITTED TO THE UNIVERSITY OF GHANA,
LEGON IN PARTIAL FULFILLMENT OF THE REQUIREMENT
FOR THE AWARD OF MPhil. ANATOMY DEGREE**

DEPARTMENT OF ANATOMY

JULY, 2015

DECLARATION BY CANDIDATE

This is a study based on my own research which I carried out at the Animal Experimentation Unit, Korle-Bu Campus and under supervision in accordance with regulations of the School of Research and Graduate Studies, University of Ghana. I hereby declare that having duly acknowledged the references to works of other researchers, this study is original to me and has not been submitted either in whole or part for the award of any other degree in this or another University.

Signature: Date:
 Marian Naa Anyema Asah-Opoku (Mrs.)

DECLARATION BY SUPERVISORS

We declare that the practical work and presentation of this thesis were supervised by us in accordance with guidelines on supervision of thesis laid down by the University of Ghana.

Principal Supervisor:

..... Date:
 Prof. Frederick K. Addai

Co-Supervisors:

..... Date:
 Rev'd Prof. Seth A. Ayettey

..... Date:
 Dr. John Ahenkorah

DEDICATION

This thesis is dedicated to my lovely husband, Dr. Kwaku Asah-Opoku and my very supportive mum, Mrs. Comfort Okine.



ACKNOWLEDGEMENTS

I thank God Almighty for His grace and mercies bestowed on me throughout the period of study. I am very grateful to the Head of Department, Prof. Frederick K. Addai and the entire Anatomy Department for the immense financial support as well as monthly allowances granted me to be able to complete this study.

My sincerest thanks go to my Academic Supervisors, Prof. Frederick K. Addai, Rev'd Prof. Seth Ayettey and Dr. John Ahenkorah for their directions and inputs to ensure a good job was done. I am greatly indebted to Drs. Vincent Boima, a Consultant Nephrologist at the Renal Dialysis Unit, Korle-Bu Teaching Hospital and Benjamin Ako-Boham for their immense contributions from the time of developing my proposal to the completion of this thesis. I am also very grateful to Dr. George Asare (Major Rtd) of the Chemical Pathology Department, University of Ghana, for his tremendous help throughout my preliminary study and teaching me how to perform cardiac puncture. To my colleague, Mr. Ernest Asiamah, I say a very big thank you for the sleepless nights we spent together in the laboratory to complete this study. God bless you.

I wish also to express my profound gratitude to the technologists at the Anatomy Department, Oral Pathology Unit, School of Medicine and Dentistry and Animal Experimentation Unit: Mr. Armah, Mr. Samuel Mensah, Mr. Paul Atiah, Mrs. Sethina Adjete, Mr. Samuel deGraft Mensah and Miss Linda Azuyie for giving me all the assistance I needed to carry out the laboratory works.

Finally, to all my friends and loved ones whose prayers and support saw me through, I say God richly bless you.

TABLE OF CONTENTS

| | |
|---|------|
| DECLARATION BY CANDIDATE | i |
| DEDICATION | ii |
| ACKNOWLEDGEMENTS | iii |
| TABLE OF CONTENTS | iv |
| LIST OF TABLES | viii |
| LIST OF ABBREVIATION | x |
| ABSTRACT | 1 |
| CHAPTER ONE | 3 |
| 1.0 INTRODUCTION | 3 |
| 1.1 Background to study | 3 |
| 1.2 Problem Statement | 11 |
| 1.3 Justification | 13 |
| 1.4 Working Hypothesis | 13 |
| 1.5 Aim | 13 |
| CHAPTER TWO | 15 |
| 2.0 LITERATURE REVIEW | 15 |
| 2.1 Gross structure of the human kidney | 15 |
| 2.2 Gross structure of rat kidney | 16 |
| 2.3 Histomorphometry of the nephron | 17 |
| 2.4 Functions of the kidney | 19 |
| 2.5 Risk of kidney injury | 20 |
| 2.6 Types of kidney injury | 21 |
| 2.6.1 Acute kidney injury - definition | 21 |
| 2.6.2 Incidence of AKI | 22 |
| 2.6.3 Causes of AKI | 22 |
| 2.6.3.1 Pre-renal | 22 |
| 2.6.3.2 Intrinsic or intrarenal | 23 |
| 2.6.3.3 Post-renal | 23 |
| 2.7 Clinical presentation of AKI | 24 |

| | | |
|--------|---|----|
| 2.8 | Management of AKI | 24 |
| 2.9 | Nephrotoxicity as a cause of AKI | 25 |
| 2.10 | Drugs as cause of nephrotoxicity | 25 |
| 2.11 | Aminoglycosides | 26 |
| 2.11.1 | Gentamicin as a common cause of nephrotoxicity | 27 |
| 2.11.2 | GM-induced nephrotoxicity as a model of AKI | 28 |
| 2.12 | Reactive oxygen species (ROS), free radicals and oxidative stress as a cause of tissue damage | 28 |
| 2.13 | GM induces production of ROS | 29 |
| 2.14 | Gentamicin (GM) induces free radical production | 29 |
| 2.15 | Mechanism of GM uptake and renal damage | 30 |
| 2.16 | Effects of nephrotoxic injury on renal compartments | 31 |
| 2.17 | Recovery of renal function in AKI | 31 |
| 2.18 | Induction of AKI in rats with gentamicin | 32 |
| 2.19 | Antioxidants role in GM nephrotoxicity | 32 |
| 2.19.1 | Sources of antioxidants | 33 |
| 2.19.2 | <i>Theobroma cacao</i> – Novel source of powerful antioxidants | 34 |
| 2.19.3 | Bioavailability of cocoa | 35 |
| 2.19.4 | Health benefits of natural cocoa | 36 |
| 3.0 | MATERIALS AND METHODS | 38 |
| 3.1 | PILOT STUDY | 38 |
| 3.2 | EXPERIMENTAL PROTOCOL FOR MAIN STUDY | 40 |
| 3.2.1 | Study design | 40 |
| 3.2.2 | Study population | 40 |
| 3.2.3 | Inclusion and exclusion criteria | 40 |
| 3.2.4 | Acquisition and acclimatization of animals | 40 |
| 3.3 | Blood sampling for kidney function test | 41 |
| 3.4 | Preparation of 2% (w/v) natural cocoa suspension (NCS) | 42 |
| 3.5 | Gentamicin (GM) dosage for acute kidney injury (AKI) | 43 |
| 3.6 | Grouping and Treatment of animals | 44 |
| 3.7 | Harvesting of rat kidneys | 46 |

| | | |
|-------|--|----|
| 3.8 | Determination of weight and volume of kidneys | 47 |
| 3.9 | Sampling of kidney tissues | 47 |
| 3.10 | Histological preparation | 48 |
| 3.11 | Stereological assessment of rat kidney | 49 |
| 3.12 | STATISTICAL ANALYSIS | 51 |
| | CHAPTER FOUR | 55 |
| 4.0 | RESULTS | 55 |
| 4.1 | Behavioural changes | 55 |
| 4.2 | Mortality | 55 |
| 4.3 | Body weight | 56 |
| 4.4 | GM and weight | 56 |
| 4.5 | Cocoa and weight | 60 |
| 4.6 | Fluid intake | 61 |
| 4.8 | Selected biochemical indicators of kidney function | 64 |
| 4.8.1 | Blood urea nitrogen (BUN) level | 64 |
| 4.8.2 | Serum creatinine (SCr) level | 64 |
| 4.9 | Stereological assessments | 68 |
| 4.9.1 | Glomerular volume | 68 |
| 4.9.2 | number-weighted volume fraction of proximal tubular epithelial cells | 69 |
| 4.10 | Histological features of kidneys sections of rats of various experimental groups | 70 |
| | CHAPTER FIVE | 78 |
| 5.0 | DISCUSSIONS | 78 |
| 5.1 | General | 78 |
| 5.1.1 | Mortality | 81 |
| 5.1.2 | Effect of cocoa on fluid consumption | 81 |
| 5.1.3 | Body weight | 81 |
| 5.1.4 | Effect of GM on selected biochemical markers | 82 |
| 5.2 | Histopathologic changes | 83 |
| 5.3 | Effects of regular consumption of cocoa as opposed to discontinuous intake | 85 |
| 5.4 | Summary of key findings | 87 |

| | |
|------------------------------|-----|
| 5.5 Conclusion | 88 |
| 5.6 Limitations of the study | 88 |
| 5.7 Recommendations | 89 |
| REFERENCES | 90 |
| APPENDIX I | 108 |
| APPENDIX II | 109 |
| APPENDIX III | 112 |

LIST OF TABLES

| | |
|---|----|
| Table 1: Experimental Interventions | 45 |
| Table 2: Summary on mortality for experimental period | 56 |
| Table 3: Summary of statistics on mean body weight (g) at various treatment points | 58 |
| Table 4: Summary of weight analysis of cocoa and non-cocoa (NNCS) treated groups (6 weeks post NCS treated) | 60 |
| Table 5: Summary of Kruskal Wallis analysis of daily fluid intake (mL) per rat in each group | 61 |
| Table 6: Summary of post HOC test for median fluid intake | 62 |
| Table 7: Summary of statistics on biochemical analysis | 65 |
| Table 8: Summary of absolute glomerular volume among treatment groups | 68 |
| Table 9: Summary of post HOC analysis for glomerular volume | 68 |
| Table 10: Summary of ANOVA test of PCT volume. | 69 |
| Table 11: Post HOC analysis of PCT volume | 69 |

LIST OF FIGURES

| | | |
|----------------------|--|----|
| Figure 1 : | A diagram showing gross appearance of the kidney in longitudinal section | 16 |
| Figure 2: | Micrographs of H & E (Haematoxylin and Eosin) stained kidney section showing cortical tissue. | 19 |
| Figure 3: | Picture showing a rat in a dessicator being anaesthetized by inhalation of chloroform. A – dessicator (without dessicant), B - rat | 52 |
| Figure 4: | Picture of a rat being perfused. | 53 |
| Figure 5: | A picture of stereological grid (0.5cm × 0.5 cm) superimposed on kidney section to count PCT epithelial cells | 54 |
| Figure 6: | A picture of stereological grid (1 cm × 1 cm) superimposed on kidney section to estimate glomerular volume | 54 |
| Figure 7: | Bar chart of rat weight at different times of experiment (weeks 0, 6 and 7) | 59 |
| Figure 8: | Line graph showing daily median fluid intake (mL) of experimental groups | 63 |
| Figure 9: | Line graph showing mean blood urea nitrogen (BUN) levels of experimental groups at weeks 0, 6 and 7 | 66 |
| Figure 10: | Line graph showing serum creatinine (SCr) levels at weeks 0, 6 and 7 | 67 |
| Figure 11(G1 – G5): | Micrographs of PAS stained kidney sections showing proximal tubular necrosis. (See legend to Figure 13 on next page). | 70 |
| Figure 12(G1 – G5): | Micrographs of PAS stained kidney sections showing mononuclear cell infiltration in GM treated groups. (See legend on next page). | 72 |
| Figure 13 (G1 – G4): | Micrographs of PAS stained kidney sections showing colloidal material in renal tubules of GM treated rats (G1, G2 and G4). | 74 |
| Figure 14(G3 – G4): | Micrograph of PAS stained kidney sections of GM only (G4) and control group (G3) showing glomerular shrinkage (g) in G4 and normal glomerulus (G) in G3. | 75 |
| Figure 15(G1 – G5): | Micrographs of PAS stained kidney sections showing loss of brush border in GM treated groups (See legend on next page). | 76 |

LIST OF ABBREVIATION

| | |
|-------|--|
| AKI | acute kidney injury |
| AKIN | Acute Kidney Injury Network |
| ARF | acute renal failure |
| ATN | acute tubular necrosis |
| BUN | blood urea nitrogen |
| CKD | chronic kidney disease |
| DCT | distal convoluted tubules |
| DPX | distyrene plasticizer xylene |
| GM | gentamicin sulphate |
| GMT | Greenwich Mean Time |
| i.p | intraperitoneal |
| ICU | intensive care unit |
| NCS | natural cocoa suspension |
| PAS | periodic acid Schiff reagent |
| PCT | proximal convoluted tubules |
| RIFLE | Risk Injury Failure Loss of function and End-stage renal disease |

| | |
|-----|---------------------------|
| ROS | reactive oxygen species |
| RRT | renal replacement therapy |
| SCr | serum creatinine |

ABSTRACT

Background: Gentamicin (GM) administration generates reactive oxygen species that have long been identified with nephrotoxicity. Cocoa flavanols are powerful antioxidants that have free radical scavenging capacity in reactive oxygen species (ROS) -mediated inflammatory processes such as from GM usage.

Aim: This study investigated whether regular ingestion of natural cocoa would protect renal structure and function in rats with GM-induced acute kidney injury (AKI).

Methodology: Thirty-two male Sprague Dawley rats of 5 groups (G1, G2, G3, G4, and G5) with 7 animals each in G1 to G4 and 4 in G5 were used for the study. Rats in G1, G2 and G5 groups were fed on 2 % w/v of natural cocoa suspension (NCS) for 6 weeks in addition to their rat chow. Rats in G3 and G4 were not given cocoa but were also fed on rat chow. At the end of 6 weeks, rats in G1 were taken off NCS and given 100 mg/kg GM intraperitoneally (i.p) for 5 days. G2 rats continued NCS intake for another 5 days with 100 mg/kg GM i.p. G3 and G5 rats received 100 mg/kg of normal saline (0.9 % N/S) as placebo while G4 rats were injected with 100 mg/kg of GM i.p. Body weights, serum creatinine (SCr) and blood urea nitrogen (BUN) were measured at weeks 0, 6 and 7 for all groups. Histomorphometric assessment was conducted on volumes of renal glomeruli and proximal convoluted tubular (PCT) cells as a quantitative measure of altered renal morphology.

Results: GM treated rats had elevated SCr and BUN (ANOVA, $p = 0.032$) levels and decreased weight. Stereologic assessments also showed reduced volumes of glomeruli

(Kruskal Wallis, $p = 0.006$) and PCTs in GM treated groups (ANOVA, $p = 0.000$) compared to control (G3) and regularly fed cocoa groups (G2).

Conclusion: GM-induced renal structural and functional damage was minimized in NCS fed G2 rats compared to G4 rats

CHAPTER ONE

1.0 INTRODUCTION

1.1 Background to study

The kidneys are a pair of organs in mammals and other non-mammalian vertebrates essential for life. They perform functions including osmoregulation, excretion of end products including urea and creatinine, synthesis of hormones such as rennin and erythropoietin and for the metabolism of vitamin D. By this, the kidneys maintain water and electrolyte balance as well as pH to regulate metabolic activities. To perform their function well, the kidneys have the richest blood supply per unit weight of tissue in the body. Blood supply to the kidneys are by the renal arteries and venous drainage is by the renal veins (Young et al., 2006). The renal vessels are of such high caliber that the vascular bed receives a large volume of toxin-borne blood (about 20 – 25% of resting cardiac volume) (Kumar & Clark, 2001; Alchi et al., 2005, Ferguson et al., 2008). Thus, by their functional role, the cells of the kidneys (particularly the cells of the proximal convoluted tubules) are prone to injury from natural or synthetic agents such as antimicrobials, immunosuppressants, chemotherapeutic agents and analgesics. These injuries may be repaired or compensated for by the kidneys without signs of injury or may be evident through renal function tests and analyses of blood chemistry. This amenable state of injury is referred to as acute kidney injury (AKI).

Mehta et al. (2007) reported that the Acute Kidney Injury Network (AKIN) defined AKI as functional and structural abnormalities of markers of kidney damage including abnormalities in blood, urine, or tissue tests or imaging studies present for less than three months. He further states that AKI has a diagnostic criteria as an abrupt (within 48 hours) reduction in kidney function with an elevation in serum creatinine levels of either ≥ 0.3 mg/dL or $\geq 50\%$ or a documented reduction in urine output (oliguria of < 0.5 mL/kg/hr for > 6 hours) and the need for renal replacement therapy (RRT – dialysis). Thus, early detection and intervention is most likely to restore kidney structure and function. Continuous injury to the cells of the kidneys coupled with late or non-detection may result in a chronic kidney injury with an unsuccessful recovery by the kidneys.

In both developed and underdeveloped states, AKI is common with high cost of care, morbidity and mortality (Kellum & Lamiere, 2013). The functional design of the kidneys exposes them to injury on daily basis. These injuries could be compounded by other risk factors such as liver disease, hypovolaemia and pre-existing renal disease making AKI common with high morbidity. Additionally, because renal replacement therapy is often required in the management of AKI, the cost of care is high especially for a low income earning country like Ghana.

Currently, the cost of dialysis per session is GH¢200 with the patient requiring at least three (3) sessions per week. Additionally, there is the cost of care as well as renal function tests and drugs. Besides, the sudden onset and abrupt reduction in renal function coupled with late detection and intervention may explain the high mortality associated with AKI. According to Hoste & Schurgers (2008), 2-3 cases of AKI are estimated per 1000 persons. Nash et al. (2002) estimated that 7% of hospitalized patients and about

two-thirds ($\frac{2}{3}$) of intensive care unit (ICU) cases develop AKI, often as a part of multiple organ dysfunctions (Hoste & Kellum, 2006). Furthermore, AKI develops in 10-30% of patients in ICUs with 30-70% mortality rates and a significant number requiring long term renal replacement therapy (Levy et al., 2009).

Unpublished data gathered from the Renal Dialysis Unit of the Korle-Bu Teaching Hospital, Accra, Ghana, indicate that the number of patients with acute renal toxicity on dialysis rose from 6 in the year 2001 to 111 in 2012. This may be attributed to more knowledge gained with respect to nephrology and probably the identification of more cases due to advances made in technology. The causes of AKI are clinically divided into three categories. These are pre-renal (caused by volume depletion resulting in decreased renal perfusion), intrinsic renal (results from a structural or functional defect within the substance of the kidneys) and post-renal (results from the obstruction of urinary flow distal to the kidneys) (Rahman et al., 2012).

Clinical presentation of AKI is dependent on severity and cause of the injury (Rahman et al., 2012). Patients with mild to moderate AKI are often asymptomatic and are therefore identified on laboratory findings (Rahman et al., 2012). On the other hand, severe cases may present with confusion, fatigue, anorexia, weight gain, uremic encephalopathy, anaemia, oliguria (urine output of less than 400 mL/day), anuria (less than 100 mL of urine per day) or with even normal urine outputs (Meyer & Hostetter, 2007; Rahman et al., 2012).

Drug-induced nephrotoxicity is an important cause of renal failure (Padmini & Kumar, 2012). Among causes of AKI, are decreased kidney perfusion, acute glomerulonephritis,

vasculitis and urinary obstruction. Drug-induced nephrotoxicity has been found to cause approximately 20% of community and hospital acquired episodes of AKI (Kaufman et al., 1991; Nash et al., 2002; Bellomo, 2006). Drug cause of nephrotoxicity can be classified as an intrinsic renal cause of kidney injury.

Nephrotoxicity is characterized by any adverse functional or structural change in the kidney due to the effect of chemical or biological product, that is inhaled, ingested or absorbed or which yields metabolite with an identifiable toxic effect on the kidney (Aslam et al., 2013). By extension, the concept of nephrotoxins is occasionally applied clinically to the renal effects of physiological substances circulating in abnormal concentration such as may occur in hypercalcaemia, hyperuricaemia or hypokalaemic nephrotoxicity (Aslam et al., 2013). The usage of certain drugs in the long run may lead to nephrotoxicity as these drugs tend to get accumulated in the form of by-products which lead to renal failure or nephropathy (Aslam et al., 2013).

Nephrotoxic drugs include antiretrovirals (example, tenofovir), antimicrobials (example, aminoglycosides) and chemotherapeutic agents (example, cisplatin) (Perazella, 2009). These drugs induce their nephrotoxicity on the tubular, glomerular, interstitial or vascular components of the kidneys (Perazella, 2009).

The effects of toxicants on the kidneys vary with varying dosages of compounds and mechanisms of injury. Injury may occur secondary to altered renal haemodynamics, direct cellular damage to the tubular epithelium, tubular obstruction of urinary flow due to the precipitation of toxins or their metabolites, interstitial inflammation, and/or thrombotic microangiopathy (Ferguson et al., 2008). Initially, injury is often manifested

by subtle changes in tubular function, including altered urine concentrating ability and/or electrolyte handling (Ferguson et al., 2008). In the absence of judicious monitoring, injury may evade detection until a significant decline in renal functional capacity occurs (Ferguson et al., 2008).

Renal tubular cells, in particular, proximal convoluted tubules (PCT) are vulnerable to the toxic effects of drugs because their role in concentrating the drugs and reabsorption of glomerular filtrate expose them to high levels of circulating toxins (Perazella, 2005).

Toxicity of drugs on renal tubular cells is enhanced by the impairment of mitochondrial function, tubular transport interference, increase in oxidative stress and formation of free radicals (Zager, 1997). In addition, toxic agents cause inflammatory changes in the glomeruli and surrounding interstitium leading to fibrosis and renal scarring. These are manifested histomorphologically by desquamation of the PCT, epithelial edema, cortical tubular necrosis, glomerular atrophy, tubular epithelial necrosis, lymphocytic infiltration around PCT and interruption of tubular basement membrane (Padmini & Kumar, 2012; Aslam et al., 2014).

In sub-Saharan Africa where poverty is a canker, poor settlements, environmental sanitation and inadequate health infrastructure highly predispose many people to microbial (especially bacterial) infections with subsequent recurrence. This results in frequent usage of both prescribed and unprescribed antibiotics subsequently leading to drug resistance. It is for this reason that aminoglycoside antibiotics such as gentamicin (GM) continue to be used in spite of their widely known nephrotoxic tendencies.

Aminoglycosides remain dependable antibactericidal agents for severe gram-negative infections (Bolisetty & Agarwal, 2007; Shu-Hui et al., 2007). Gentamicin (GM) is an aminoglycoside antibiotic discovered in 1963 from micromonospora (Bolisetty & Agarwal, 2007). This drug has been widely studied and is of great clinical significance because of its reduced resistance (Martinez-Salgado et al., 2007). Gentamicin has also shown efficacy in the treatment of serious and life-threatening gram negative bacterial infections (Shu-Hui et al., 2007) caused by *Pseudomonas*, *Proteus*, and *Serratia* (Tavafi et al., 2012). Moreover, it is cheap (Shu-Hui et al., 2007; Salem et al., 2010; Veljkovic et al., 2015) compared to other aminoglycosides such as amikacin, netilmicin and tobramycin. The long term use of GM is however limited by the development of nephrotoxicity and ototoxicity even at therapeutic doses (Riff & Jackson, 1971; Shu-Hui et al., 2007; Veljkovic et al., 2015). In addition, Khan et al. (2011) reported that GM has hepatotoxic effects. Oral administration of the drug limits its effectiveness due to poor absorption in the intestinal tract (Ali & Goetz, 1997). It is therefore recommended that the drug is administered intravenously, intramuscularly, intraperitoneally or topically (Ali & Goetz, 1997). Gentamicin is excreted by the kidneys without degradation and about 5-10 % is concentrated in the PCT, highly exceeding serum levels (Costa et al., 1987) and causing acute renal failure with acute tubular necrosis in about 20 % of patients treated with the drug (Shu-Hui et al., 2007). Karahan et al., (2005) also reported that GM causes 10 – 20 % of drug-induced dose-dependent nephrotoxicity of therapeutic courses. Due to their highly basic charge, aminoglycosides poorly penetrate cell membranes (Erdem et al., 2000). The proximal tubular cells of the renal cortex have a much higher ability to concentrate aminoglycosides several folds more than plasma levels (Erdem et al., 2000).

The selective accumulation of GM in the renal cortex can induce oxidative stress resulting in lipid peroxidation as well as generation of reactive oxygen species (ROS) (Cuzzocrea et al., 2002; Kadkhodae et al., 2005) leading to renal inflammatory cascades and consequently, renal dysfunction (Kaul et al., 1993). Erdem et al. (2000), support the fact that the accumulation of aminoglycosides within the renal cortex is known to be related intimately to the pathogenesis of nephrotoxicity.

Aminoglycoside-induced nephrotoxicity is clinically manifested as non-oliguric renal failure with a slow rise in serum creatinine (SCr) and a hypo-osmolar urinary output developing several days post treatment (Mingeot-Leclercq & Tulkens, 1999).

Reactive oxygen species and free radicals have been implicated in the pathophysiology of GM-induced nephrotoxicity such as super oxide anions, hydroxyl radicals, hydrogen peroxide and reactive nitrogen species in the kidney (Yaman & Balikci, 2010; Tavafi et al., 2012). The effects of ROS and free radicals in inflammatory processes however, have been experimentally prevented or minimized with the use of high antioxidant containing substances. Chemicals and medicinal plants with high antioxidant levels such as selenium (Tavafi et al., 2012) and *Sonchus asper* (Khan et al., 2011), have therefore been explored to attenuate the nephrotoxic effects of ROS generated by the use of GM. Many of these have posed potential protection of tissues at high risk for injury and damage resulting from the effects of free radicals and ROS.

Antioxidants are naturally occurring chemicals (that is, enzymes and metabolites) that have free radical scavenging properties and also limit the formation of free radicals by reducing membrane fluidity which stabilizes the membrane (Aror et al., 2000; Kromhout

et al., 2002). Glutathione catalase and superoxide dismutase are some antioxidant enzymes. The metabolites include vitamins A, B and E (Affram et al, 2008). Antioxidants have been shown to have anti-inflammatory, anticarcinogenic and cardio-protective effects (Sokpor et al., 2012). Black tea, green tea, red wine and cocoa are high in phenolic phytochemicals which play chemopreventive roles based on their antioxidant capacities (Lee et al., 2003).

Cocoa is derived from the *Theobroma cacao* tree and contains high levels of polyphenols particularly catechins and proanthocyanidins (Wollgast & Anklam, 2000). Among plants known to contain antioxidants, it has been established that cocoa has the highest antioxidant content (Lee et al., 2003). These polyphenols include catechins, epicatechins and procyanidins (Hopper et al., 2008; Sokpor et al., 2012) and are known to have anti-inflammatory effects (Min-Hsiung et al., 2010; Pen et al., 2010). The effects of cocoa and cocoa products as well as isolated flavanols have been widely studied in many experimental models. The health benefits of cocoa ingestion have primarily been attributed to the high levels of antioxidants in cocoa (Lee et al., 2003; Hollenberg, 2006; Addai, 2010). Long term feeding studies of flavanol-rich cocoa showed an increase in total plasma antioxidant capacity and a reduction in susceptibility to oxidative injuries (Keen et al., 2005; Etse, 2009).

Many local and international research have established that the high antioxidant content of cocoa as well as its anti-inflammatory properties have prevented and minimized tissue damage in cardiovascular disease, Type II diabetes, chronic alcohol toxicity, malaria and cancer in both humans and animal models (Hollenberg, 2006; Addai, 2010; Sokpor et al., 2012). Natural cocoa and its potential health benefits can therefore not be over-stated.

Ghana is the second leading producer of cocoa in the world (COCOBOD, 2015). Hence, cocoa is abundant, easily accessible and relatively cheap for the average Ghanaian. It is therefore, of great interest to determine whether regular consumption of natural cocoa has any nephroprotective effect in GM-induced AKI. This would promote cocoa consumption which may not only have protective potential against GM-induced nephrotoxicity but also boost the capacity of tissues to withstand other forms of ROS mediated injuries.

1.2 Problem Statement

The structural and functional design of the kidneys makes them highly vulnerable to damage from circulating toxic naturally occurring and synthetic substances. These include metabolites such as urea and creatinine as well as drugs including gentamicin.

It has been indicated that the risk of AKI attributable to aminoglycosides is sufficiently frequent and many authors have recommended the elimination of aminoglycosides as a clinical treatment option (KDIGO, 2012). Gentamicin is an aminoglycoside antibiotic commonly used for its efficacy against gram negative bacterial infections and cost effectiveness (Tavafi et al., 2012). Its usage is however limited by its nephrotoxic effect which may occur in about 13-30 % of treated patients (Matthew, 1992) and can lead to acute kidney injury (AKI).

Gentamicin has been found to induce the generation of ROS and free radicals which have been implicated in the pathophysiology of GM-induced AKI (Yaman & Balikci, 2010;

Tavafi et al., 2012). Although renal tissues may recover from GM-induced injury, frequent insult to the cells of the kidney is more likely to result in diminished ability to repair such damage with time. Acute kidney injury (AKI) may result, which may subsequently progress to a chronic kidney failure with delayed or no intervention, requiring renal replacement therapy.

As at the time of carrying out this research, the cost of dialysis per session at the Renal Dialysis Unit at the Korle-Bu Teaching Hospital was GH¢200.00. This excluded cost of other medications. A patient needs a minimum of three (3) sessions per week and this is very expensive for many people in Ghana. However, studies have been conducted extensively which suggest that consumption of substances with high antioxidant content have protection against GM-induced renal toxicity (Maldonado et al., 2003; Yanagida et al., 2004; Kalava & Menon, 2012).

Cocoa which is a high antioxidant-containing medicinal plant is fortunately abundant and relatively cheap in Ghana, one of the leading producers of high quality cocoa and cocoa products in the world.

It is therefore of great value to explore the nephroprotective effect of regular consumption of natural cocoa (especially as an alternative) to ease the burden of AKI. This is because, in a low income country such as Ghana, GM and other drugs with nephrotoxic effects continue to be used as they remain effective and cheap in treatment of bacterial infections.

1.3 Justification

In low income countries and communities where health care cost is of major concern, there is the need to explore the possibility of building cell and tissue capacity to withstand the toxic effects of otherwise useful but cheap drugs such as gentamicin. The burden of managing AKI could be reduced if circulating toxins that damage kidneys could be scavenged regularly from the body.

Ghana is one of the largest cocoa producing countries and is therefore expected that Ghanaians would have the full benefits of this food product that is known to be beneficial in disease conditions. Moreover, cocoa is not a new product on the market and many people are already consuming it for its health benefits.

It is therefore of scientific and economic interest to find out whether regular consumption of natural cocoa would also ameliorate GM-induced nephrotoxicity and build up the capacity of capacity to withstand damage from other forms of circulating toxins.

1.4 Working Hypothesis

The regular consumption of natural cocoa has protective effect on kidney microstructure and function in gentamicin-induced acute kidney injury.

1.5 Aim

To determine the protective effect of regular consumption of natural cocoa on kidney structure and function in gentamicin-induced AKI.

1.5.1 Objectives

The specific objectives are use of stereology to do the following on kidneys of rats with GM-induced AKI and given cocoa or not.

1. To measure the volume density of glomeruli
2. To measure volume of PCT epithelial cells

CHAPTER TWO

2.0 LITERATURE REVIEW

2.1 Gross structure of the human kidney

The kidneys are a pair of reddish-brown bean-shaped organs lying in the upper retroperitoneal area. A human kidney has a lateral convex surface and a medial concave surface with an indentation known as the hilum which is the site of entry and exit of the renal blood vessels and the ureter (Landau, 1980; Young et al., 2006).

The archetypal kidney of lower mammals consists of a single lobe made up of a medullary pyramid (actually cone-shaped), the base of which is enveloped by the cortex containing the renal corpuscles and the proximal and distal parts of the tubules (Young et al., 2006).

The basic functional units of the kidneys (nephrons) arise in the cortex, loop down into the medulla and return to the cortex (Young et al., 2006). From the loop (ascending limb), they drain into collecting ducts that descend again into the medulla to discharge urine from the apex of the medullary pyramid (Young et al., 2006). The apical part of the pyramid (known as the renal papilla) is enveloped by a funnel-shaped renal pelvis, which represents the dilated proximal part of the ureter as shown in Figure 1 (Young et al., 2006).

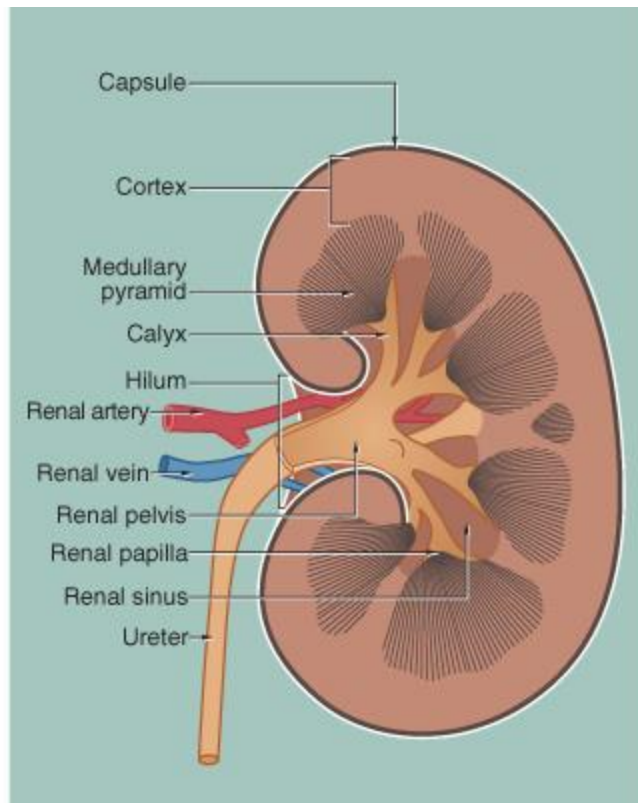


Figure 1 : A diagram showing gross appearance of the kidney of a lower mammal in longitudinal section

Source: (Young et al., 2006)

2.2 Gross structure of rat kidney

The paired rat kidneys (in vivo) are reddish-brown in colour, much like the human kidney. They have a medial concavity and a lateral convexity of the typical normal kidney shape. The cranial pole of the right kidney lies at the level of L1 vertebra and therefore within the thoracic cage. The caudal pole is at the level of L3. The left kidney is shifted by about $\frac{1}{4}$ to $\frac{1}{2}$ of its length in relation to the right one. Both lie almost equidistant from the

midline and their long axes converge cranially. The kidney is 20 (± 5) mm long, 10 -15 mm wide and measures about 10 mm dorsoventrally. In 180 – 280 g rats, the kidney weighs 0.73 – 1.2 g (Hebel & Stromberg, 1976).

2.3 Histomorphometry of the nephron

The nephron is functionally and histologically composed of the renal corpuscle, the proximal convoluted tubules, loop of Henle, distal convoluted tubule and the collecting tubules and ducts. Each renal corpuscle is about 200 μm in diameter and consists of a tuft of capillaries, the glomerulus, surrounded by a double-walled epithelial capsule called glomerular (Bowman's) capsule. Each renal corpuscle has a vascular pole, where the afferent arteriole enters and the efferent arteriole leaves, and a urinary pole, where the proximal convoluted tubule begins (Junquiera & Carneiro, 2005).

The epithelial cells of the proximal convoluted tubules (PCT) are cuboidal with acidophilic cytoplasm and numerous elongated mitochondria. The apex of the cell has abundant microvilli about 1 μm in length, which forms a brush border (Junquiera & Carneiro, 2005). Due to the large sizes of the cells each transverse section of a proximal tubule contains only three to five spherical nuclei (Junquiera & Carneiro, 2005).

The loop of Henle is U-shaped with thick and thin descending limbs and thin and thick ascending limbs. The thin limbs are lined by simple squamous epithelium and the thick ascending limbs by low cuboidal epithelium (Junquiera & Carneiro, 2005; Young et al., 2006).

The distal convoluted tubules (DCT) are lined with simple cuboidal epithelium. The distal convoluted tubules differ from the proximal convoluted tubules (both found in the cortex) because they have no brush border, no apical canaliculi, and smaller cells (Junquiera & Carneiro, 2005). Distal tubule cells are flatter and smaller than those of the proximal tubule. Hence, more nuclei are seen in DCT than in the PCT (Junquiera & Carneiro, 2005). Cells of the DCT have elaborate basal membrane invaginations and associated mitochondria indicative of their ion-transporting function (Junquiera & Carneiro, 2005).

The smaller collecting tubules are lined with cuboidal epithelium and have a diameter of approximately 40 μm (Junquiera & Carneiro, 2005). As they penetrate deeper into the medulla, their cells increase in height until they become columnar. The diameter of the collecting duct reaches 200 μm near the tips of the medullary pyramids (Junquiera & Carneiro, 2005).

The bulk of the cortex is occupied by the proximal and distal convoluted tubules (Figure 2). The cortex consists mainly of proximal convoluted tubules lined by more eosinophilic epithelial cells, with smaller numbers of distal convoluted tubules and collecting tubules whereas the renal medulla consists of closely packed tubules of two types: the loop of Henle and the collecting tubules and ducts as well as the vasa recta (Young et al., 2006).

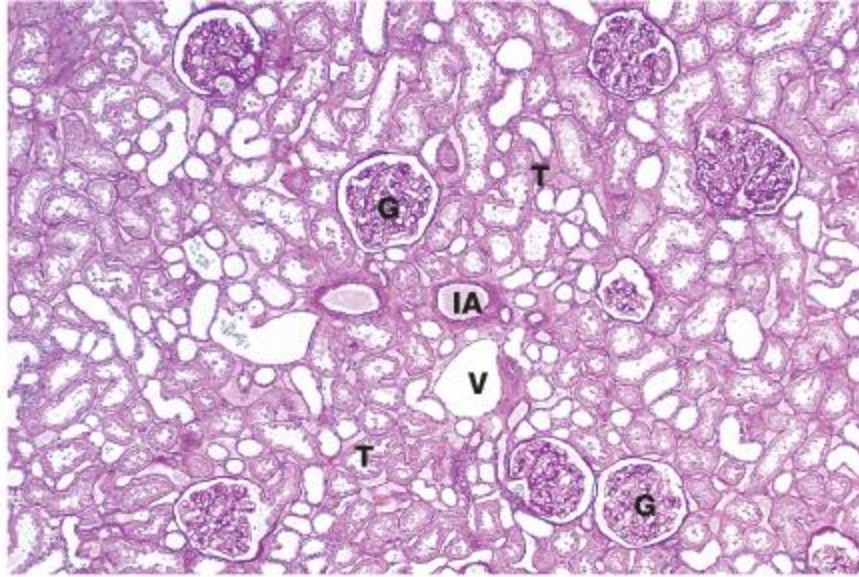


Figure 2: Micrograph of H & E (Haematoxylin and Eosin) stained kidney section showing cortical tissue.

G – Glomerulus, T – Renal Tubules, V – Renal Vein, I – Interlobular Artery

Source: (Young et al., 2006)

2.4 Functions of the kidney

The principal function of the urinary system is the maintenance of water, electrolyte and acid-base homeostasis and excretion of toxic metabolic waste products such as urea and creatinine (Young et al., 2006). The kidneys have hormonal and metabolic functions which include the control of blood pressure by the synthesis of rennin which is involved in the renin-angiotensin-aldosterone mechanism, synthesis of erythropoietin which stimulates the production of erythrocytes and the regulation of calcium balance by the synthesis of vitamin D (Young et al., 2006).

2.5 Risk of kidney injury

High risk factors associated with the development of AKI include invasive surgical procedures, underlying kidney disease and therapeutic interventions such as androgen deprivation therapy in patients with prostate cancer (Lapi et al., 2013) and administration of aspirin or clonidine during perioperative periods (Garg et al., 2014).

Humans are exposed to a variety of potential nephrotoxic substances on a rather frequent basis (Perazella, 2009). Several therapeutic agents have known nephrotoxic potential; classic examples include anti-microbial agents, chemotherapeutic agents, analgesics, and immunosuppressive agents as cited by Perazella (2009). While most are prescribed, many others are available to the general population over-the-counter (Perazella, 2009). Numerous new drugs with unknown toxic potential are constantly being released for use into clinical practice (Perazella, 2009). Diagnostic agents, in particular iodinated radiocontrast and high dose intra-arterial gadolinium, are other sources of nephrotoxin exposure (Briguori et al., 2005; Ergun et al., 2006).

A large volume of blood (25% of cardiac output or approximately 1300 mL per minute) – passes through both kidneys (Kumar & Clark, 2001) thereby exposing them to high levels of circulating toxins.

Drugs cause approximately 20% of community and hospital acquired episodes of acute renal failure (Kaufman et al., 1991; Nash et al., 2002; Bellomo, 2006). Among older adults, the incidence of drug-induced nephrotoxicity may be as high as 66 % (Kohli et al., 2000). Renal impairment is often reversible if the offending drug is discontinued.

However, the condition can be costly and may require multiple interventions, including hospitalization (Gandhi et al., 2000).

2.6 Types of kidney injury

There are two (2) main types of kidney injury classified by the onset, progression and duration of recovery of renal function. These are: acute kidney injury (reversible) and chronic kidney disease (irreversible). Several divergent views have been held on the definitions and diagnosis of the types of kidney injuries (KDIGO, 2012). For uniformity in treatment and outcomes, the Acute Kidney Injury Network (AKIN) and Risk, Injury, Failure; Loss of Function, End-Stage Renal Disease (RIFLE) criteria are adopted in staging and diagnosing renal insufficiency (KDIGO, 2012).

2.6.1 Acute kidney injury – definition

Acute kidney injury (AKI), formally called acute renal failure (ARF), refers to a complex disorder that comprises multiple causative factors and occurs in a variety of settings with varied clinical manifestations that range from a minimal but sustained elevation in serum creatinine to anuric renal failure (Devarajan, 2006). According to Fry & Farrington (2006), ARF is a potentially reversible reduction in the capacity of the kidney to excrete nitrogenous wastes and maintain fluid and electrolyte homeostasis, which usually occurs over hours to days. Rahman et al. (2012) has also defined AKI as an abrupt (within 48 hours) reduction in kidney function based on an elevation in serum creatinine level, a reduction in urine output, the need for renal replacement therapy (dialysis), or a combination of these factors.

Acute kidney injury (AKI) is however amenable to prevention, early detection and treatment (Kellum & Lameire, 2013).

2.6.2 Incidence of AKI

The incidence of AKI has increased in recent years, both in the community and in hospital settings (Nash et al., 2002; Hsu et al., 2007). The estimated incidence of acute kidney injury is two to three (2-3) cases per 1,000 persons (Hoste & Schurgers, 2008). Seven percent (7 %) of hospitalized patients and about two-thirds ($\frac{2}{3}$) of patients in intensive care units develop AKI, (Nash et al, 2002) often as part of the multiple organ dysfunction syndrome (Hoste et al., 2006).

There is widespread agreement that nephrotoxins are an important etiologic factor in hospital-acquired AKI. An epidemiologic survey by Uchino et al. (2005) revealed that drug nephrotoxicity contributed 19 % of AKI cases in critically ill patients.

2.6.3 Causes of AKI

The causes of AKI have been categorized into three groups: pre-renal, intrinsic, and post-renal.

2.6.3.1 Pre-renal

In pre-renal cause of kidney injury, the renal parenchyma is intact and apparent renal dysfunction results from reduced renal perfusion, attributable to hypovolaemia, hypotension or drugs (Fry & Farrington, 2006). Injury is reversible on correction of the underlying cause (Fry & Farrington, 2006).

2.6.3.2 Intrinsic or intrarenal

In intrinsic renal injury, initial pathophysiology lies within the kidney and is accompanied by early structural lesions in the parenchyma. It includes diseases of the large renal vessels, glomeruli and renal microvasculature, tubules and tubulointerstitium. Damage can result from cytotoxic, ischaemic or inflammatory insults. Tubular cell injury or death may occur attributable to prolonged or inadequately corrected, pre-renal failure - ischaemic acute tubular necrosis (ATN) (Fry & Farrington, 2006).

2.6.3.3 Post-renal

This type of kidney injury may arise as a result of obstruction of urine outflow of both kidneys or a single functioning kidney anywhere from renal pelvis to urethra (Fry & Farrington, 2006). The renal parenchyma remains intact and relief of obstruction usually leads to recovery of function (Rahman et al., 2012).

Pre-renal failure is the most frequent cause at least in hospitalized patients, although obstruction secondary to prostatic disease is as common in some community studies (Fry & Farrington, 2006). Intrinsic disease is most probably attributable to ischaemic ATN (50% of cases of intrinsic ARF), with nephrotoxic ATN, interstitial nephritis, and glomerulonephritis accounting for 35%, 10%, and 5% of cases respectively (Fry & Farrington, 2006). The condition is often multifactorial, for example, the septic, hypotensive patient given aminoglycosides and intravenous contrast. Elderly patients, diabetic patients, and those with pre-existing renal disease are all at higher risk (Fry & Farrington, 2006).

2.7 Clinical presentation of AKI

Clinical presentation varies with the cause and severity of renal injury, and associated diseases (Rahman et al., 2012). Most patients with mild to moderate AKI are asymptomatic and are identified on laboratory testing (Rahman et al., 2012). Patients with severe cases, however, may be symptomatic and present with listlessness, confusion, fatigue, anorexia, nausea, vomiting, weight gain, or edema (Meyer & Hostetter, 2007). Patients can also present with oliguria (urine output less than 400 mL per day), anuria (urine output less than 100 mL per day), or normal volumes of urine (non-oliguric AKI) (Rahman et al., 2012). Other presentations of AKI may include development of uremic encephalopathy (manifested by a decline in mental status, asterixis, or other neurologic symptoms), anemia, or bleeding caused by uremic platelet dysfunction (Rahman et al., 2012).

Patients with AKI are more likely to develop chronic kidney disease in the future (Rahman et al., 2012). They are also at higher risk of end-stage renal disease and premature death (Goldberg & Dennen, 2008; Coca et al., 2009). Patients who have an episode of acute kidney injury should be monitored for the development or worsening of chronic kidney disease (Rahman et al., 2012).

2.8 Management of AKI

A thorough assessment of the patient is key in the management of AKI. Maintenance of the volume status of the patient and removal and/or avoidance of further nephrotoxic insults (Fry & Farrington, 2006) may be enough to restore kidney function. Nevertheless, some patients with AKI may require renal replacement therapy for renal function to be

restored. Clinical interventions for acute renal failure also include the use of diuretics but this according to Mehta et al. (2002), is associated with increased risk of death and non-recovery of renal function especially in critically ill patients.

2.9 Nephrotoxicity as a cause of AKI

Nephrotoxicity can be defined as renal disease or dysfunction that arises as a direct or indirect result of exposure to medicines and industrial or environmental chemical (Aslam et al., 2014). It is characterized by any adverse functional or structural change in the kidney due to the effect of chemical or biological product. These chemicals and biological products may be inhaled, ingested or absorbed; yielding metabolites with an identifiable toxic effect on the kidney. Nephrotoxins can be referred to as physiological substances circulating in abnormal concentration such as may occur in hypercalcaemia, hyperuricaemia or hypokalaemic nephrotoxicity (Aslam, et al., 2014).

2.10 Drugs as cause of nephrotoxicity

The usage of certain drugs in long run may lead to nephrotoxicity (Perazella, 2009). The drugs tend to get accumulated in the form of by products which lead to renal failure or nephropathy (Perazella, 2009). Nephrotoxic drugs include antiretrovirals (example, tenofovir), antimicrobials (example, aminoglycosides) and chemotherapeutic agents (example, cisplatin) (Perazella, 2009). These drugs induce their nephrotoxicity on the tubular, glomerular, interstitial or vascular components of the kidneys (Perazella, 2009).

Renal tubular cells, in particular proximal tubule cells, are vulnerable to the toxic effects of drugs because their role in concentrating and reabsorbing glomerular filtrate exposes

them to high levels of circulating toxins (Perazella, 2005). Drugs that cause tubular cell toxicity do so by impairing mitochondrial function, interfering with tubular transport, increasing oxidative stress or forming free radicals (Zager, 1997; Markowitz & Perazella, 2005). These dysfunctions result in inflammatory changes in the glomerulus, renal tubular cells, and the surrounding interstitium, leading to fibrosis and renal scarring (Markowitz et al., 2003; Perazella, 2005; Markowitz & Perazella, 2005).

In the classic histological appearance of ATN, tubules are surrounded by flattened, denuded epithelium, and the lumen filled by cell debris, with congested peritubular capillaries and an extensive inflammatory cell infiltrate (Fry & Farrington, 2006).

2.11 Aminoglycosides

Aminoglycoside antimicrobial agents are highly potent bactericidal antibiotics effective against gram negative and selected gram positive bacterial pathogens when administered with beta-lactam and other cell wall active antimicrobial agents (KDIGO, 2012). Favourable attributes of aminoglycosides include remarkable stability, predictable pharmacokinetics, low incidence of immunologically mediated side effects and lack of hematologic or hepatic side effects (KDIGO, 2012).

The usage of aminoglycosides is however limited due to their nephrotoxic and to a lesser extent, ototoxic and neuromuscular blockade effects. It has been indicated that the risk of AKI attributable to aminoglycosides is sufficiently frequent and many authors have recommended the elimination of aminoglycosides as a clinical treatment option (KDIGO, 2012).

Aminoglycosides have long been one of the common causes of drug-induced nephrotoxicity (Bhatia et al., 2012) and repeated administration over several days or weeks can result in accumulation within the renal interstitium and tubular epithelial cells and a higher incidence of nephrotoxicity (KDIGO, 2012).

Aminoglycoside antibiotics such as GM are not metabolized in the body (Sreedevi et al., 2011). The injected dose is essentially eliminated by glomerular filtration, whereas a fraction accumulates in the renal proximal tubule cells where the concentration of aminoglycosides is several times higher than in plasma (Khan et al., 2011). Gentamicin (GM) also undergoes partial reabsorption by proximal tubular cells as a consequence of adsorptive endocytosis (Beauchamp et al., 1997; Mingeot-Leclercq & Tulkens, 1999).

Aminoglycosides throughout the endocytic pathway are taken up into the epithelial cells of the renal proximal tubules and stay there for a long time, which leads to nephrotoxicity. Acidic phospholipids, broadly distributed in the plasma membranes in various tissues, were considered to be the binding site of aminoglycosides in brush-border membrane of proximal tubular cells (Nagai & Takano, 2004; Nagai, 2006).

2.11.1 Gentamicin as a common cause of nephrotoxicity

Gentamicin is a broad-spectrum bactericidal aminoglycoside antibiotic, produced by fermentation of *Micromonospora purpurea* or *M. Echinospira* (Abu-Basha et al., 2013)

Based on comparative clinical nephrotoxicity, GM is the most nephrotoxic drug (Humes, 1988). The specificity of gentamicin for renal toxicity is apparently related to its

preferential accumulation in the renal proximal convoluted tubules (50 to 100 times greater than serum) and lysosomes (Nagai & Takano, 2004).

Gentamicin (GM) is more concentrated in the renal cortex of man and experimental animals than it is in other tissues and body fluids and it persists in that location for many weeks after cessation of therapy (Luft & Kleit, 1974; Edwards et al., 1976). It has been suggested that these pharmacologic properties account for the exceptional sensitivity of the kidney to the toxic effects of gentamicin.

2.11.2 GM-induced nephrotoxicity as a model of AKI

Gentamicin induced nephrotoxicity is a model of acute renal failure caused by oxidative stress generated through the induction of superoxide (Maldonado et al., 2003; Tavafi et al., 2012). Alteration in kidney function induced by lipid peroxidation is restricted to the cortical tissue, specifically the proximal convoluted tubules. It has also been demonstrated that gentamicin-induced nephrotoxicity is characterized by direct tubular necrosis, which is localized mainly in the proximal tubules (Bhatia et al., 2012). It is complex phenomenon characterized by an increase in plasma creatinine and urea levels and severe proximal tubular necrosis, followed by deterioration and renal failure (Yaman & Balikci, 2010).

2.12 Reactive oxygen species (ROS), free radicals and oxidative stress as a cause of tissue damage

Abnormal production of ROS may result in damage of macromolecules, to induce cellular injury and necrosis via several mechanisms including peroxidation of membrane

lipids, protein denaturation and DNA damage (Sreedevi et al., 2011). This is believed to be involved in the etiology of many xenobiotic toxicities (Baliga et al., 1999; Kehrer, 1993; Parlakpinar et al., 2005; Sreedevi et al., 2011). Reactive oxygen species (ROS) directly act on cell components, including lipids, proteins, and DNA, destroying their structure (Randjelovic et al., 2012). Reactive oxygen species (ROS) have been suggested as a cause of death for many cells in different pathological states including various models of renal and cardiac diseases.

2.13 GM induces production of ROS

Although GM is widely known to induce nephrotoxicity, the exact mechanism of damage is unclear. However, many investigators have speculated the generation of ROS as a cause of tissue damage especially in the proximal convoluted tubules (Cuzzocrea et al., 2002; Yanagida et al., 2004). In support, Sha & Schacht (1999) reported that GM bioactivation results in the formation of ROS causing deficiency in intrinsic antioxidant enzymes.

2.14 Gentamicin (GM) induces free radical production

Gentamicin (GM) nephrotoxicity involves renal free radical generation, reduction in antioxidant defense mechanisms, acute tubular necrosis, and glomerular congestion (Martinez-Salgado et al., 2007; Mingeot-Leclercq and Tulkens, 1999; Geleilete et al., 2002; Abdel-Raheem et al., 2010), resulting in diminished glomerular filtration rate and renal dysfunction. Sha & Schacht (1999) have also suggested the stimulation of free radical formation by aminoglycosides.

2.15 Mechanism of GM uptake and renal damage

Due to their large size and polycationic charge, aminoglycoside antibiotics do not easily cross biological membranes lacking transport mechanisms (Martinez-Salgado et al., 2007).

Hydroxyl radicals play a role in the pathogenesis of gentamicin nephrotoxicity. GM can induce suppression of $\text{Na}^{(+)}\text{-K}^{(+)}\text{-ATPase}$ activity and DNA synthesis in proximal tubules of rats leading to renal injury. This injury may be relevant to reactive oxygen metabolites generated by GM (Padmini & Kumar, 2012). Renal cortical mitochondria are the source of reactive oxygen metabolites, which induce renal injury (Baliga et al., 1997). It has been shown that the specificity of GM renal toxicity is related to its preferential accumulation in renal convoluted tubules and lysosomes (Nagai, 2004). Aminoglycoside antibiotics such as GM are not metabolized in the live organism and the injected dose is essentially eliminated by glomerular filtration, whereas a fraction accumulates in the renal proximal tubule cells where the concentration of aminoglycosides is several times higher than in plasma (Randjelovic et al., 2012). GM also undergoes partial reabsorption by proximal tubular cells as a consequence of adsorptive endocytosis (Beauchamp et al., 1997; Mingeot-Leclercq & Tulkens, 1999).

Some investigators showed that GM acts as an iron chelator and that the iron-GM complex is a potent catalyst of free radical formation and accumulation (Priuska & Schacht, 1995; Yanagida et al., 2004).

2.16 Effects of nephrotoxic injury on renal compartments

Nephrotoxic substances produce disease in all compartments of the kidney. The entire nephron and collecting duct system are capable of being injured by various nephrotoxins.

Gentamicin-induced AKI can be classified under intrinsic renal disease and the proximal convoluted tubules (PCT) are most commonly affected because of the mechanism by which the PCT handles the drug.

Tubular disease, especially in the PCT occurs as a complication of prescribed nephrotoxins and environmental exposures. Proximal cell tubular toxicity develops due to direct nephrotoxic effects (mitochondrial dysfunction, lysosomal hydrolase inhibition, phospholipid damage, increased intracellular calcium concentration), formation of reactive oxygen species with injurious oxidative stress and osmolar effects with loss of normal cell-cell contact and tubular luminal occlusion (Cummings & Schnellmann, 2001; Markowitz & Perazella, 2005).

2.17 Recovery of renal function in AKI

A remarkable feature of the kidney is its ability to regain normal structure and function after such injury. Once renal perfusion and oxygen supply are normalised, viable cells still adherent to the tubular basement membrane can spread to cover denuded areas, and then differentiate to reproduce normal tubular architecture and function. The return of glomerular filtration aids clearance of tubular debris and relief of obstruction (Fry & Farrington, 2006).

2.18 Induction of AKI in rats with gentamicin

Different methods have been employed to induce renal failure in rats. These include intraperitoneal (i.p.) administration of gentamicin sulfate at a dose of 100 mg/kg/day (in 0.9% NaCl) for 5 - 8 days and assessment of renal failure done 24 hours after the last gentamicin injection (Erdem et al., 2000). Xie et al., (2001) reported of acute renal toxicity at a relatively higher dose of 150 mg/kg, subcutaneously (s.c.) for 5 days. The development of acute renal toxicity in rats has also been shown by administering gentamicin at a dose of 200 mg/kg twice daily for 4 consecutive days (Ortega et al., 2005). Volpini et al., (2006) on the other hand, reported the development of acute renal failure in rats by administration of gentamicin at a dose of 40 mg/kg, intramuscularly, twice daily for nine days, while Bledsoe et al., (2008) reported the development of renal toxicity in rats by administration of gentamicin at a dose of 80 mg/kg sc. for 10 days with the assessment of renal failure on the 11th day.

However, the administration of 100 mg/kg of gentamicin, intra-peritoneally, for 5 consecutive days to induce renal dysfunction seem to be most commonly used model and closely mimics the antibiotic-induced changes in renal function in clinical setup (Amrit et al., 2012).

2.19 Antioxidants role in GM nephrotoxicity

Antioxidants are compounds that hinder oxidative processes and thereby delay or prevent oxidative stress.

The pathophysiology of GM-induced AKI has been intimately related to the generation of ROS and free radicals. In view of this, many research studies have focused on the use

antioxidants with highly potent free radical scavenging capacity to attenuate GM-induced toxicities. *In vivo* and *in vitro* studies have shown that the scavengers of reactive oxygen metabolites are protective in GM-induced renal failure (Pedraza-Chaverri et al., 2000; Randjelovic et al., 2012). The administration of several compounds with antioxidant activity has been successfully used to prevent or ameliorate GM-induced nephrotoxicity (Ali, 2003; Stojiljkovic et al., 2012).

2.19.1 Sources of antioxidants

Polyphenols represent a wide variety of compounds, which are divided into several classes. That is, hydroxybenzoic acids, hydroxycinnamic acids, anthocyanins, proanthocyanidins, flavonols, flavones, flavanols, flavanones, isoflavones, stilbenes, and lignans (Manach et al., 2005).

Phenolic compounds present in medicinal plants have been reported to possess powerful antioxidants activity (Bhatia et al., 2012). By helping to protect tissues against stress, certain polyphenols work as preventive medicines for problems such as cardiovascular diseases, cancer, arthritis and autoimmune disorders (Mursu et al., 2004). These antioxidants scavenge free radicals, reduce their formation and stabilize membrane by decreasing membrane fluidity (Aror et al., 2000; Kromhout et al., 2002). Among botanical medicines, cocoa, ginkgo, elderberry and green tea are examples of rich sources of antioxidant polyphenols (Lee et al., 2003). Some polyphenols (such as proanthocyanidins) exert beneficial cardiovascular effects through inhibition of platelet aggregation (Murphy et al., 2003).

Many plants and plant extracts as well as chemicals thought of to contain high levels of antioxidants have been tested in both humans and experimental animals (with experimentally-induced conditions such as diabetes mellitus, malaria, hypertension and obesity) to explore the potential of tissue protection. Examples of such antioxidant-containing substances include wine, tea, grape fruits, selenium, *sonchus asper*, ginseng, taurine, thymoquinone and curcumin. Among these, cocoa beans have been found to contain the highest amount of antioxidants and their derivatives, such as cocoa powder and chocolate, are important sources of polyphenols (Lee et al., 2003).

2.19.2 *Theobroma cacao* – Novel source of powerful antioxidants

Cacao (or cocoa) beans are seeds of the fruit of the *Theobroma cacao* tree. The pod shaped fruit is botanically classified as baccate-like (berry-like) and each pod produces approximately 35-50 seeds surrounded by a sweet pulp (Crozier et al., 2011), which is often eaten in its fresh unprocessed state. The pod and the pulp surrounding the cacao seed in this case constitute the fruit of cacao. The seed-derived portion of cocoa as often been consumed by many people in the form of powder or chocolate (Crozier et al., 2011). Cocoa nibs have a high phenolic content of about 12-18% (dry weight) and 95% are flavanol monomers (epicatechin and catechin) and procyanidin oligomers (dimer to decamer) (Donavan et al., 2001; Lamuela-Raventós et al., 2005). Flavanols, especially the monomer epicatechin and oligomers and polymers of flavanols called proanthocyanins, can act as strong antioxidants in food systems (Crozier et al., 2011). Apart from its antioxidant components, cocoa also contains mineral elements such as sodium, zinc, magnesium, boron, copper, calcium, phosphorus, potassium, nitrogen and

manganese (Oliveira & Genovese, 2013) which build tissue capacity to withstand damage.

2.19.3 Bioavailability of cocoa

The conclusive evidence for the effectiveness of cocoa polyphenols in disease prevention and human health improvement is essentially dependent on the nature and distribution of these compounds in diet (Khan et al., 2014). In addition, the bioavailability of the ingested cocoa polyphenols will circumscribe organism exposure to these putatively bioactive compounds, affecting a magnitude of related health outcomes. The bioavailability of cocoa polyphenols, starting from their dietary consumption to their fate in the human organism is affected by a number of factors (Khan et al., 2014) including the storage and processing methods.

Principally, flavanols, epicatechin and procyanidins, have so far been foreseen as the principal bioactive cocoa polyphenols due to both their abundance and their relevance to biological activities and physicochemical structures (Bravo, 1998; Corcoran et al., 2012; Khan et al., 2014).

Cocoa flavanols are rapidly absorbed upon ingestion reaching maximum plasma levels about 2 hours after ingestion and achieving elimination in about 6 hours (Baba et al., 2000; Schramm et al., 2001, Holt et al, 2002, Khan et al., 2014). There is however, delayed absorption of some epicatechin metabolites could occur with these metabolites remaining in systemic circulation for up to 24 hours. Cocoa flavanols absorbed in the small intestine, are normally cleared from the body over 24 hours, like the majority of dietary polyphenols.

Some studies have suggested that the early appearance of polyphenols in plasma may buttress the fact that they are mainly absorbed in the small intestine. Complex flavanols which are not absorbed in the small intestines due to their structural isomerism and stereoisomerism (Ottaviani et al., 2011) are transported to the colon where they are metabolized by colonic flora (Monagas et al., 2010).

2.19.4 Health benefits of natural cocoa

The increasing interest in and demand for cocoa has come about as a result of several research reports on inverse association of between cocoa consumption and various disease conditions (such as cardiovascular disease, diabetes mellitus, malaria and obesity) in humans and experimental animals.

Cocoa polyphenols, most importantly, flavanols have been associated with numerous health benefits (Keen et al., 2005). These medicinal properties have long been associated with the polyphenolic compounds which give flavor and color to chocolate (Bravo, 1998).

Cocoa flavanols have been reported to have a wide range of biological properties including the stimulation of nitric oxide synthase, improving blood flow and arterial elasticity, decreasing blood pressure and platelet aggregation, modulating eicosanoid synthesis, lowering the rate of LDL-cholesterol, and stimulating the production of anti-inflammatory cytokines among others (Waterhouse et al., 1996; Wollgast & Anklam, 2000). Cocoa consumption also plays a preventative role in cardiovascular protection and also against tumoral and carcinogenic processes (Erden & Kahraman, 2000).

Furthermore, different mechanisms of activity have been established within this main effect for both cocoa products and isolated flavanols (Jeon et al., 2003).

According to Addai, (2010) natural cocoa is beneficial in preventing asymptomatic malaria, reducing age related, cardiovascular and mental problems due to its high antioxidant levels.

In experimental rats fed on cocoa, there is a significant increase in white blood cells level implying that the administration of cocoa could boost the immune system, since these cells are the most important cells responsible for the protection and fighting of infection (Abrokwah et al., 2009). Importance of cocoa and its products on the heart, liver with alcohol toxicity and in malaria have also been established (Hollenberg, 2006; Addai, 2010; Sokpor et al., 2012). Thus, intake of natural cocoa and its products have been recommended for their benefits.

Available literature is however void of the effect of cocoa on kidney structure and function in GM-induced AKI. Thus, it is of great interest to find out if cocoa can ameliorate GM-induced kidney damage.

CHAPTER THREE

3.0 MATERIALS AND METHODS

3.1 PILOT STUDY

The study was conducted at the Animal Experimentation Unit, Korle-Bu with the aim of establishing the dosage at which gentamicin sulphate (GM) would induce significant and obvious nephrotoxicity. A total of 6 adult male Sprague Dawley rats between 8 – 10 weeks old and weighing 200 – 260 g acquired from the Animal Experimentation Unit, Korle-Bu were used for the study. After a week of acclimatization, the rats were weighed and randomly put into individual cages. Five were designated GM groups and the other one, control group. All the rats were put on standardized rat chow and clean tap water. Gentamicin (GM) group were injected with 80 mg/kg/body weight of gentamicin sulphate produced by Troge Medical GMBH, Hamburg, Germany (with batch number 13201-01 and purchased at the 24 Hour Pharmacy, Korle-Bu Teaching Hospital) for 6 consecutive days. Blood samples were collected by cardiac puncture on the seventh day for analysis of blood urea nitrogen and creatinine. The animals were sacrificed at the histology laboratory of the University of Ghana School of Medicine and Dentistry by perfusion fixation. 10 % sodium buffered formalin was used for the perfusion. The kidneys and liver were harvested for histological processing and light microscopy.

On viewing under the light microscope, pathological changes in GM treated rats were not very obvious. Micrographs of tissue slides of control group rats that received 80 mg/kg 0.9 % normal saline (as placebo) but not GM, showed normal kidney morphology.

In view of this, the study was repeated in another 6 adult male Sprague Dawley rats between 9 -10 weeks old and weighing 130 – 210 g. rats were put into three groups of 2 animals each. The first group was treated with 90 mg/kg GM intraperitoneally (i.p.), the second group, 100 mg/kg GM i.p and the third group (control group) divided into 2 with each receiving 90 mg/kg and 100 mg/kg normal saline i.p. all the treatments were given over a period of 5 consecutive days. Blood samples were collected before and after interventions for biochemical analysis. The same standard histological protocols followed in the first pilot study were used in preparing harvested kidneys and liver for light microscopy. H & E and PAS staining were done in both pilot studies.

Induction of neprotoxicity with 100 mg/kg GM i.p for 5 consecutive days revealed significant and observable tissue damage and signs of inflammation including the presence of colloids in PCTs, loss of brush border, tubular necrosis, PCT epithelial cell desquamation and mononuclear cell infiltration.

A dose of 100 mg/kg GM i.p was concluded to be used for the main study.

3.2 EXPERIMENTAL PROTOCOL FOR MAIN STUDY

3.2.1 Study design

An experimental design was used for this study.

3.2.2 Study population

32 mature male Sprague Dawley rats were sampled for the study.

3.2.3 Inclusion and exclusion criteria

9 – 12 weeks old rats weighing between 160 – 200 g and appearing healthy on visual inspection were sampled for the study. Rats less than 9 weeks old or more than 12 weeks old weighing less than 160 g or more than 200 g were excluded from the experiment. In addition, rats that appeared unhealthy on visual inspection were also excluded.

3.2.4 Acquisition and acclimatization of animals

Thirty-two male adult Sprague Dawley rats between the ages of 9-12 weeks and with weights between 160 – 250 g were acquired from the Animal Experimentation Unit, Korle-Bu for the research. The rats at this age were matured enough and their organs large enough for easy handling.

Male rats were used with consideration that they have no lunar hormonal pattern. The rats were kept in the Animal Experimentation Unit throughout the study at an average temperature of 30°C, relative humidity of 80% and a 12 hour light/dark cycle. The animals were put on standardized rat chow and water for a week to acclimatize. After

acclimatization, the animals were weighed and randomly put into 5 groups with 7 animals in each of first four groups and 4 in the fifth group. Each group of rats were kept rat cage with dimension 20.3 cm × 28.7 cm × 17.3 cm but for limited resources, the rats would have been kept in individual cages for proper monitoring.

The study was carried out with approval from the Ethical and Protocol Review Committee, of the University of Ghana School of Medicine and Dentistry (protocol identification number: **MS-Et/M.8 – P4.4/2014-2015**). Procedures involving the care and use of the animals were done in compliance with standard guidelines for the use of animals in biomedical research.

3.3 Blood sampling for kidney function test

Blood samples were taken by cardiac puncture (after anaesthetizing the animals with ether inhalation as shown in Figure 3) at the commencement (as baseline measures) of the study, before and after interventions (sacrifice of the animals). This was done at weeks 0, 6 and 7. About 1.5 ml of blood was collected from each animal into plain gel separation blood sample bottles, kept in an ice-chest and transported to the Central Laboratory of the Korle Bu Teaching Hospital for biochemical analysis (blood urea electrolytes and creatinine). The samples were left to stand for 30 minutes at room temperature to facilitate clotting and serum separation. The samples were then arranged and centrifuged at 3000 round per minute (rpm) for 5 minutes. The serum was decanted into Eppendorf tubes for biochemical analysis.

3.3.1 Biochemical analysis

A fully automated Vitros 5,1/Fs chemistry analyzer with serial number 34000615 was used in analyzing the samples. Blood urea nitrogen and creatinine levels were analyzed in all blood samples collected at weeks 0, 6 and 7.

3.4 Preparation of 2% (w/v) natural cocoa suspension (NCS)

Natural cocoa powder with batch number 0A1501A was purchased from Good Food Brand, Accra, Ghana. The aqueous suspension was prepared daily by weighing out 8.0 g of the cocoa powder and dissolving in 400 mL of pre-boiled tap water and was cooled prior to administration. The NCS was administered to each group of animals using a graduated feeding bottle. This percentage (w/v) of cocoa was used because it tasted less bitter and tolerable. Due to sedimentation of the suspension, it was administered between the hours of 07-19 GMT and shaken at intervals. The animals were then given clean tap water during the night for another 12 hours. The volume of NCS (NCS_v) consumed in 12 hours per group was calculated by subtracting the volume left in the feeding bottles at the end of 12 hours (N_f) from the initial volume (N_i) administered. The volume of water drunk in 12 hours (W_v) was also calculated as shown below. Total fluid intake per 24 hours was calculated by adding the NCS_v consumed in 12 hours and the volume of water consumed in 12 hours.

$$NCS_v (12hrs) = N_i - N_f$$

$$W_v (12hrs) = W_i - W_f ,$$

where, W_i is initial volume of water administered

W_f is amount of water left at the end of the 12 hours period

$$\text{Total fluid intake per day} = NCS_v + W_v$$

3.5 Gentamicin (GM) dosage for acute kidney injury (AKI)

Having established from the pilot study that a dosage of 100 mg/kg of GM (IP) for five consecutive days was adequate to induce renal dysfunction in the rat, AKI was induced by weighing each animal on a weighing scale (Hana brand) and calculating the corresponding volume of gentamicin sulphate injection produced by Wuhan Grand Pharma, China and with batch number 140117. 2 mL of 80 mg GM was contained in each ampoule. The rats were weighed on daily basis and the calculation of volume of GM per animal done as follows:

Using 100 mg/kg/body weight, \longrightarrow 1000g = 100 mg

$$1g = \frac{1g \times 100mg}{1000g} = 0.1mg$$

$$\text{If } 80mg = 2mL, \text{ then } 0.1mg = \frac{0.1mg \times 2mL}{80mg} = 0.0025mL$$

Hence, if weight of rat is Y, volume of GM to be administered is (0.0025 mL)(Y).

Rats that were not treated with GM were injected intraperitoneally with 0.9 % normal saline purchased from the Surgical Pharmacy, Korle-Bu Teaching Hospital. The volumes administered were calculated following the same equation above.

3.6 Grouping and Treatment of animals

The first group (G1) of animals was fed on NCS for 6 weeks in addition to their standardized rat chow and water. NCS was discontinued at after the 6 weeks prior to administration of GM. In addition to their rat chow, Group two (G2) was also fed on NCS for 7 weeks whiles receiving GM between the 6 – 7 weeks. The third group (G3) was fed on standardized rat chow and water throughout the 7 week period. They were neither treated with NCS nor GM. The fourth group, after being put on their rat chow and water for 6 weeks, received GM only for 5 consecutive days. Group 5 (G5) was put on NCS but not GM, in addition to their rat chow and water for 7 weeks (*Refer to Table 1*). After interventions, the animals were weighed and sacrificed following standard perfusion protocols.

Treatment of the various groups is summarized in the table below:

Table 1: Experimental Interventions

| Group (G) | Treatment | Duration (weeks) | | | | | | | | |
|-----------|--------------------|------------------|---|---|---|---|---|---|---|--|
| | | 1 | 2 | 3 | 4 | 5 | 6 | 7 | 8 | |
| G1 | Rat chow and water | → | | | | | | | | |
| | 2 % NCS | → | | | | | | | | |
| | GM | | | | | | → | | | |
| G2 | Rat chow and water | → | | | | | | | | |
| | 2 % NCS | → | | | | | | | | |
| | GM | | | | | | ▼ | → | | |
| G3 | Rat chow and water | → | | | | | | | | |
| | NCS | | | | | | | | | |
| | GM | | | | | | | | | |
| G4 | Rat chow and water | → | | | | | | | | |
| | NCS | | | | | | | | | |
| | GM | | | | | | → | | | |
| G5 | Rat chow and water | → | | | | | | | | |
| | NCS | → | | | | | | | | |
| | GM | | | | | | | | | |

3.7 Harvesting of rat kidneys

At the end of 5 consecutive days of GM administration (that is, between weeks 6 and 7), blood samples were collected and animals conveyed from the animal experimentation unit to the histology laboratory for perfusion to be done.

A standard set-up for perfusion was made and a clean desiccator without dessicant improvised for a rat gas chamber (*Refer to Figure 3*). Starting with G1 to G5, a rat from each group was sacrificed at a time by placing each rat and a roll of cotton ball soaked with chloroform (BDH Chemicals Limited, Poole, England) into the RGC as shown in *Figure 3*. Inhalation of the chloroform resulted in the rat becoming fully unconscious which was confirmed by pin- pricking of the lateral aspect of the abdominal wall without consequent movement as a sign of pain. The animal was quickly pinned on a dissecting board in the supine position and the thoracoabdominal area swabbed with 70 % alcohol as an aseptic technique prior to incision.

The anterior thoracic wall was dissected and reflected superiorly to expose the thoracic viscera. The cardiovascular system was flushed with about 250 mL of 0.9 % normal saline running constantly under gravity via a 21G ×1” hypodermic needle inserted into the left ventricle and nicking of the right atrium with a pair of scissors to serve as an outlet (*Refer to Figure 4*). Adequate clearing was confirmed by the bright red appearance of the liver turning pale and the flow of normal saline through the rat nostrils. After clearing, the animal was perfused with ~ 200 mL of 10 % sodium buffered formalin (pH = 7.24 – 7.28) using a fixative delivery set under the same conditions for clearing.

Effective fixation was affirmed when all muscles seized twitching and rat became stiff. The anterior abdominal wall was incised and the liver and kidneys harvested. Perfusion of each animal lasted for about 30 minutes. The weights and volumes of the excised organs were determined and fixed in ~50 mL of 10 % buffered formalin for a week before tissue processing for light microscopy.

3.8 Determination of weight and volume of kidneys

The kidneys of each rat were decapsulated on harvesting and blotted dry with tissue paper. Each was then weighed twice using a chemical balance and the average weight was determined to be the actual weight. The volumes were also determined by fluid displacement. Each decapsulated kidney was blotted dry with soft tissue paper and gently placed in a measuring cylinder containing 20 mL of water. The volume was determined by calculating the difference in volumes before and after immersion of the kidney into the water. The kidneys were transferred into separate containers with 10 % buffered formalin for further fixation.

3.9 Sampling of kidney tissues

The left kidney (LK) was selected for longitudinal sections and the right kidney (RK) for transverse sections. The LK was cut into three slabs of 1.5 – 2.0 mm thickness for subsequent histological tissue processing. The RK was cut into 2.0 mm thick slabs. Every other slab was selected for histological tissue processing with a random selection of the first slab. At least 2 and at most 4 slabs were picked for each rat RK.

3.10 Histological preparation

Standard protocols for Periodic Acid Schiff (PAS) histological preparation of tissues were used in processing sampled tissue slabs. Dehydration, clearing and embedding were done using a Leica TP 1020 automatic tissue processor, manufactured in Germany. Tissue blocks were prepared using well labeled tissue cassettes, stainless steel moulds and a molten wax dispenser (Leica EG 1150H manufactured in Germany). After allowing to harden, the paraffin wax blocks of kidney and liver tissue were placed on ice and sectioned with LEICA RM 2235 rotary microtome. The tissues were sectioned at 5 μm thickness. The first section was randomly picked and subsequently, every 10th. For the LK, 3 sections were picked per block. Hence, a total of 9 sections were sampled from each animal for staining for PAS.

The sections were straightened on a plastic plate using 30 % (v/v) alcohol solution and placed on warm water at 40°C in a water bath. They were then picked on clean glass slides and kept in a tissue oven for 24 hrs at 45°C to dry. PAS staining were later done using LEICA ST 4040 automatic linear tissue stainer. Mounting was done using appropriate cover slips and distyrene plasticizer xylene (DPX) mountant.

3.11 Stereological assessment of rat kidney

The absolute volume of glomeruli and number weighted volume fraction of PCT cells were therefore determined independently to assess morphological changes in rat kidneys among experimental groups.

Each slide was bordered by complete lines drawn using a board marker to form a rectangle around the tissue. The microscope stage was moved from one corner to the other on the x- axis. At 3 and 5 microscope stage unit intervals on the x and y-axes respectively, snapshots of renal corpuscles and tubules within the field of view were captured ($\times 400$) onto a computer (HP Compaq dx2300 Microtower) with the aid of a digital eyepiece (Lenovo Q350 USB PC Camera) connected to a Leica Galen III (catalogue no. 317506, serial no. ZG6JA4) light microscope. This was done until the whole area of the tissue was covered. Using a minimum number of 4 animals per group, a total number of 80 micrographs each were randomly sampled per group for stereological assessment to determine the volumes of glomeruli and undamaged PCT epithelial cells using Cavalieri principle (Dezfoolian et al., 2009).

Using Adobe Photoshop CS6 Extended (Trial Version 13.0.1) software, a stereological grid consisting of uniformly spaced points, $1\text{cm} \times 1\text{cm}$ and $0.5\text{ cm} \times 0.5\text{ cm}$ were superimposed over each micrograph of the glomerulus and PCTs respectively to count the number of test points which intersected the glomerulus and epithelial cells of the PCTs (*Figures 5 & 6*).

The following equations were used to determine the volumes of glomeruli and PCTs.

$$V = \frac{\Sigma P \times \left(\frac{a}{p}\right) \times t}{M^2}$$

Where V indicates volume, ΣP is the sum of all test points encountered, (a/p) is the area per point of the stereological grid, t is the thickness of the section and M is the linear magnification.

Number weighted volume fraction of PCTs per cortex (P_v) = $\frac{P}{A} \times 100\%$

Where P is the total number of test points encountered with the PCTs, A is the total points per stereological grid used and given by: $\Sigma a/p$ (a/p is area per point of stereological grid).

Mean P_v per group = $\sum \frac{\{P|A\}}{n} \times 100\%$

Where n is number of samples.

In addition, snapshots of microscope stage graticule were taken at the same magnification. The micrograph of the graticule was used for calibrating the grid which was used for the stereological study.

3.12 STATISTICAL ANALYSIS

Minitab version 15.0 was used for statistical analyses. Levene's test for homogeneity was done to determine normality of all data. Statistical significance of the difference between groups was performed by Student's Paired T-Test and one way analysis of variance (ANOVA) for parametric data results. For non-parametric data, Kruskal-Wallis Test and Mann-Whitney U Test were performed. Differences with $p < 0.05$ were considered to be statistically significant.




Figure 3: Picture showing a rat in a dessicator being anaesthetized by inhalation of chloroform. A – dessicator (without dessicant), B - rat

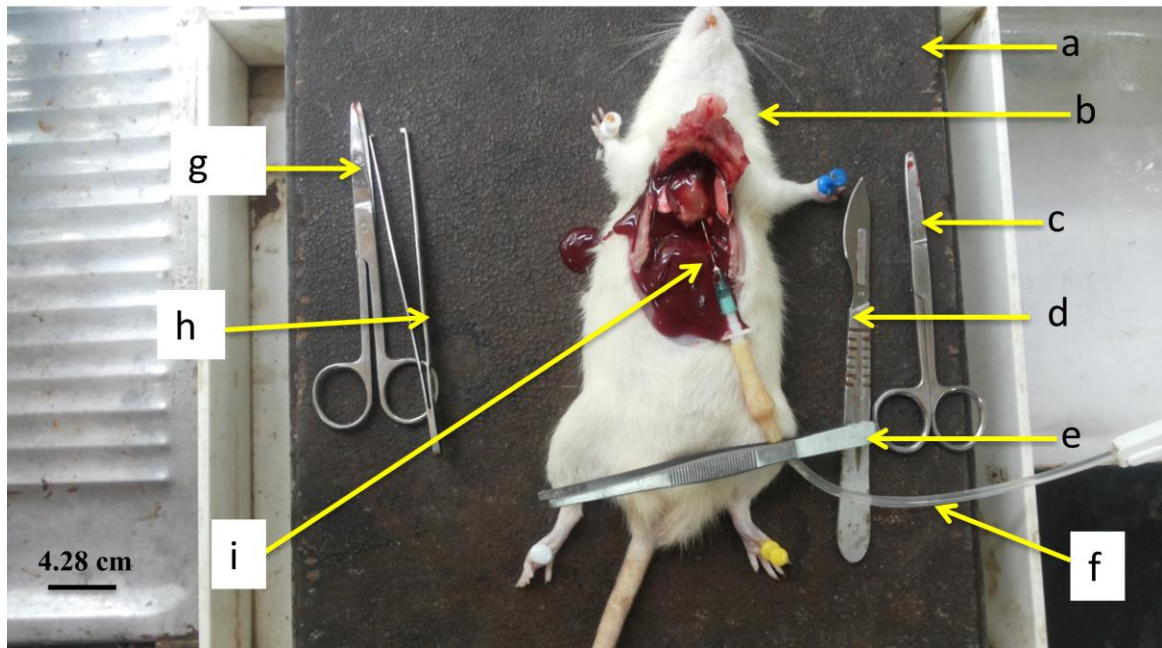


Figure 4: Picture of a rat being perfused.

a –dissecting board, b – Rat, (c and g) – pairs of scissors, d – surgical blade in a blade holder, e – forceps used to stabilize infusion line, f – infusion set, h – toothed forceps and i- 21G×1” gauge hypodermic needle.

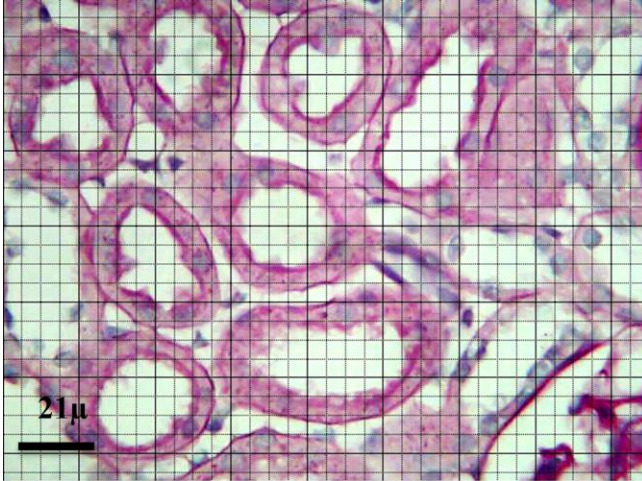


Figure 5: A picture of stereological grid (0.5cm × 0.5 cm) superimposed on kidney section to count PCT epithelial cells

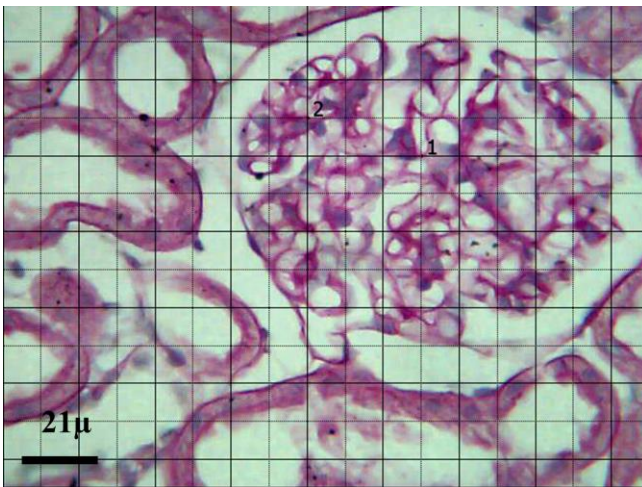


Figure 6: A picture of stereological grid (1 cm × 1 cm) superimposed on kidney section to estimate glomerular volume

CHAPTER FOUR

4.0 RESULTS

Thirty-two adult male Sprague Dawley rats between the weights of 160 g and 250 g were randomly selected for the study. Each rat was assigned to one of five groups (Table 1) and treated with NCS with or without GM in addition to their standardized rat chow and water over a period of 7 weeks. The following results were obtained from the study.

4.1 Behavioural changes

Rats in all groups did not show any behavioural changes prior to and after treatments. They also did not show signs of nephrotoxicity as a result of treatment.

4.2 Mortality

A total number of 3 rats were lost before the end of the treatment. One each from G1 and G4 died at week 0 (start) and 6 respectively as a result of injury to thoracic viscera in the course of blood sampling by cardiac puncture. Another rat was lost from G1 post treatment and during the night. Post mortem was however not done to ascertain the cause of death. It can therefore only be speculated that severe nephrotoxic injury or infection may be responsible. *Table 2* gives a summary of the number of rats per group and mortality observed.

Table 2: Summary on mortality for experimental period

| Group | Number of rat (wk 0) | Mortality | Number of rats (wk 6) | Mortality | Number of rats (wk 7) | Mortality |
|--------------|----------------------|-----------|-----------------------|-----------|-----------------------|------------|
| 1 | 7 | 1(icp)* | 6 | - | 5 | 1(unknown) |
| 2 | 7 | - | 7 | - | 7 | - |
| 3 | 7 | - | 7 | - | 7 | - |
| 4 | 7 | - | 7 | - | 6 | 1(icp)* |
| 5 | 4 | - | 4 | - | 4 | - |
| Total | 32 | 1 | 31 | | 29 | 2 |

(icp)*---injury from cardiac puncture

A total number of 4 rats were sacrificed from G3 because the animals received no treatment and would not be necessary to sacrifice all 7 of them. It was assumed that this group of animals would have the same renal histomorphometry.

4.3 Body weight

The average weight of 32 rats used at the commencement of the study was 193.75 g with a standard error of 4.14 g. One-way analysis of variance showed that there was no significant difference in weight among the five experimental groups at weeks 0, 6 and 7.

4.4 GM and weight

One-way analysis of variance (ANOVA) test showed that there was no significant weight difference among groups at weeks 0 ($p = 0.922$), 6 ($p = 0.947$) and 7 (0.488). Paired t-test analysis however, indicated that the weights of all animals at week 6 were significantly different from that of the same animals at week 0; all the rats in the various experimental groups gained weight. However, by the end of GM administration (week 7), rats that received GM (G1, G2 and G4) lost significant weight compared to the weights of the

same rats at week 7. Gentamicin (GM) treated rats also lost weight significantly compared to rats that did not receive GM (G3 and G5) – Shown in *Table 3 and Figure 7*.

Table 3: Summary of statistics on mean body weight (g) at various treatment points

| Week | Weight (g) \pm SE Mean | | | | | p-value |
|------|---------------------------------|---------------------------------|---------------------------------|---------------------------------|---------------------------------|---------|
| | G1 | G2 | G3 | G4 | G5 | |
| 0 | 189.2 \pm 10.5 | 190.00 \pm 6.81 | 198.75 \pm 9.21 | 198.60 \pm 11.0 | 193.75 \pm 9.44 | 0.922 |
| 6 | 253.33 \pm 9.80 ^{**} | 261.43 \pm 9.11 ^{**} | 257.50 \pm 17.1 ^{**} | 252.14 \pm 6.53 ^{**} | 260.00 \pm 11.70 [*] | 0.947 |
| 7 | 240.00 \pm 9.87 ⁺ | 248.57 \pm 9.86 ⁺ | 265.00 \pm 16.0 | 236.67 \pm 7.82 ⁺⁺ | 243.80 \pm 13.1 | 0.488 |

$\alpha - 0.05$

T-test results for week 6 indicated by asterisk(s): * means $p < 0.05$; ** means $p < 0.005$ and that of week 7 by (⁺) means $p < 0.05$;

⁺⁺ means $p < 0.005$.

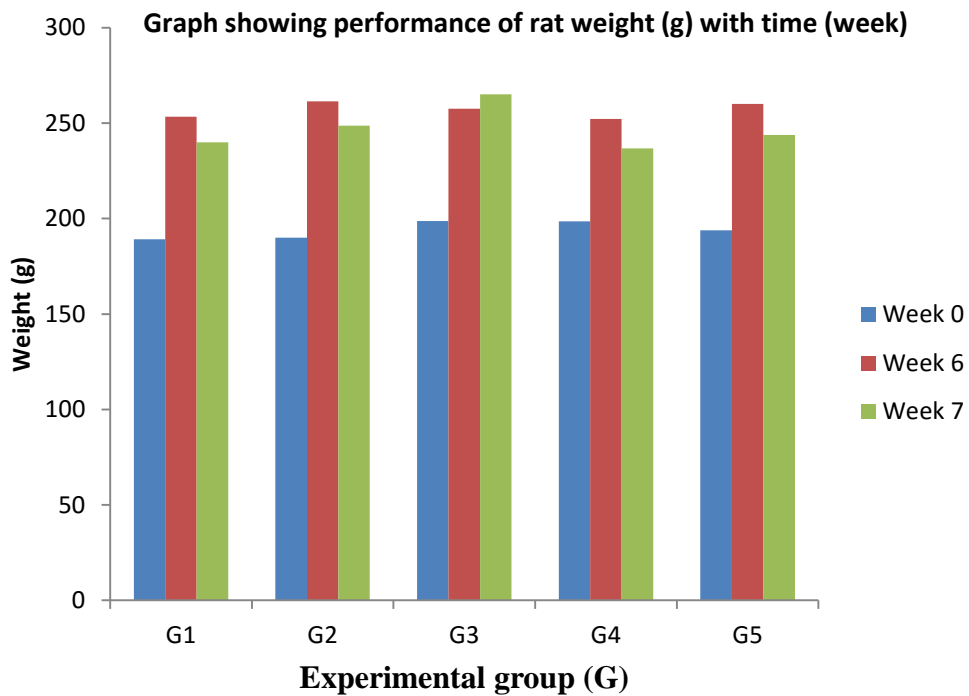


Figure 7: Bar chart of rat weight at different times of experiment (weeks 0, 6 and 7)

4.5 Cocoa and weight

The average weight of rats fed on NCS (G1, G2 and G5) for 6 weeks was 190.60 ± 4.8 g. Those fed on rat chow and water without NCS (G3 and G4) had an average weight of 198.60 ± 7.4 at the end of the 6th week. A two sample t-test analyses showed that there was no significant difference in weight of NCS and non-NCS treated groups ($p = 0.377$, $p > 0.05$) as shown in *Table 4*.

Table 4: Summary of weight analysis of cocoa and non-cocoa (NNCS) treated groups (6 weeks post NCS treated)

| Group | Wt (G) \pm SE Mean | P-Value |
|------------------------|----------------------|---------|
| NCS treated (G1,G2,G5) | 190.60 ± 4.8 | 0.377 |
| NNCS treated (G3, G4) | 198.60 ± 7.4 | |

$\alpha - 0.05$

4.6 Fluid intake

Kruskal-Wallis test was conducted to determine median daily fluid intake per rat. Cocoa with gentamicin treated group (G2) ranked highest with daily intake of 43.14 mL per rat while gentamicin only treated group (G4) recorded the least amount of 30.93 mL. Natural cocoa suspension (NCS) treated groups (G1, G2 and G3) drank relatively higher amounts compared to non-NCS treated groups (G3 and G4).

Furthermore, pair-wise analysis of the experimental groups using Mann-Whitney test showed that the median volume of fluid consumed by rats in G4 was significantly less than those in G1 ($p = 0.0003$), G2 ($p = 0.0000$), G3 ($p = 0.0011$) and G5 ($p = 0.0001$). The test also showed that rats in G2 consumed a higher median volume of fluid (rank of 150.10, z-score of 3.31) than rats in G3 (rank of 113.0, z-score of -0.84). From the Mann-Whitney test, rats fed on NCS consumed more fluid than rats in the control group (G3) and rats treated with GM (Tables 5, 6 and Figure 8).

Table 5: Summary of Kruskal Wallis analysis of daily fluid intake (mL) per rat in each group

| Group (G) | Median (mL) | Average rank | z-score |
|-----------|-------------|--------------|---------|
| G1 | 39.17 | 129.50 | 1.00 |
| G2 | 43.14 | 150.10 | 3.31 |
| G3 | 33.93 | 113.00 | -0.84 |
| G4 | 30.93 | 75.50 | -5.01 |
| G5 | 39.83 | 134.30 | 1.54 |

$p = 0.00, \alpha = 0.05$

Table 6: Summary of post HOC test for median fluid intake

| Pairs | W | p-value |
|-------|--------|---------|
| G1,G4 | 1861.5 | 0.0003 |
| G2,G4 | 1562.5 | 0.0000 |
| G3,G4 | 1909.5 | 0.0011 |
| G5,G4 | 2833.5 | 0.0001 |
| G2,G3 | 1894.5 | 0.0008 |
| G3,G5 | 2486.0 | 0.1242 |

 $\alpha = 0.05$

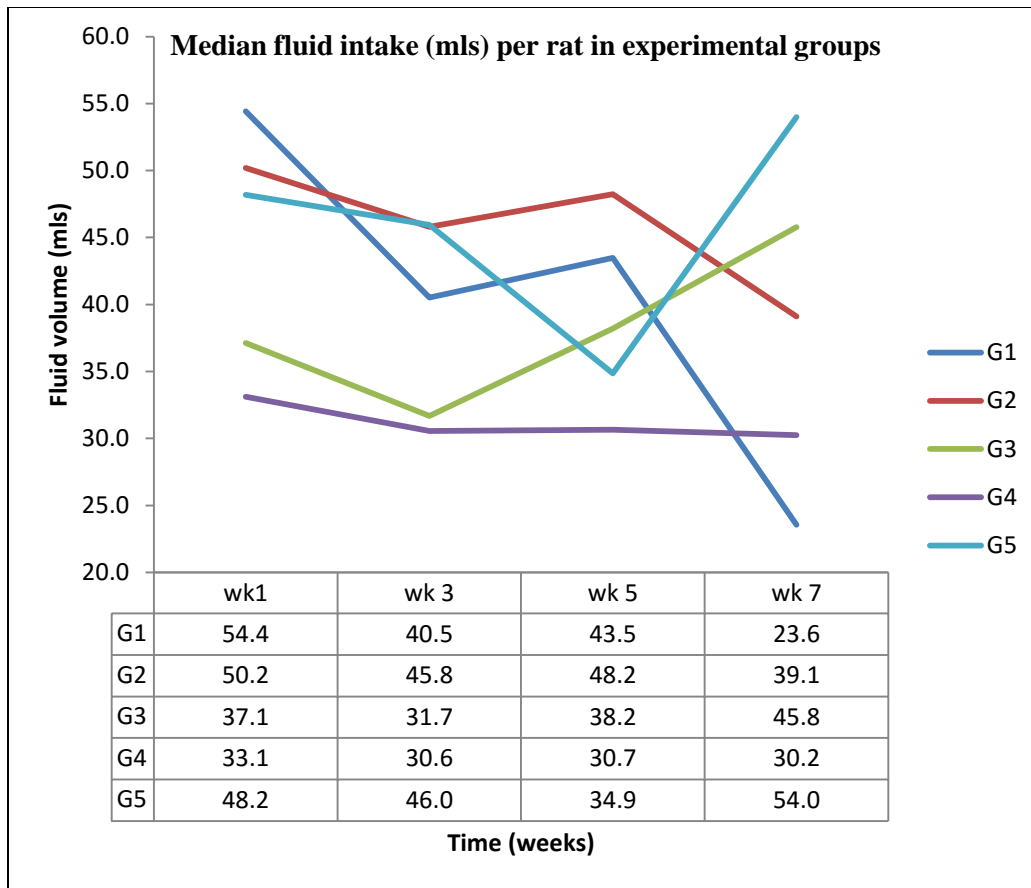


Figure 8: Line graph showing daily median fluid intake (mL) of experimental groups

4.8 Selected biochemical indicators of kidney function

4.8.1 Blood urea nitrogen (BUN) levels

Baseline levels of urea by one way analysis of variance test showed that there was no significant difference among all 5 groups of rats ($p = 0.059$, $p > 0.05$). However, this rose steadily to become significant at the end of week 6 with a p-value of 0.004. At the end of week 7, urea levels rose up steeply ($p = 0.032$) in GM treated groups with G4 recording the highest value of 80.11 ± 21.0 mg/dL and G2 recording least (56.62 ± 16.4 mg/dL). Urea levels at week 7 in non-NCS treatment groups (G3 and G4) were not significantly different from that at week 6 of the same animals (*Table 7 and Figure 9*).

4.8.2 Serum creatinine (SCr) levels

One way analysis of variance test indicated that baseline SCr levels among treatment groups were significantly different ($p = 0.008$). However, at the end of weeks 6 and 7, SCr levels among the experimental groups were not significantly different (p-values of 0.716 and 0.131 respectively). Analysis of SCr levels in G1 and G4 showed that in each group, SCr levels at week 7 was significantly greater than values recorded at week 6 ($p = 0.026$ for G1; $p = 0.028$ for G4). Again, values recorded in G2, G3 and G5 at week 7 were not statistically significant from those recorded at week 6 (*Table 7 and Figure 10*).

Table 7: Summary of statistics on biochemical analysis

| Biochemical marker | Week | G1 | G2 | G3 | G4 | G5 | P-values |
|--------------------|------|-----------------|-----------------|-----------------|-----------------|----------------|----------|
| Urea(mg/dL) | 0 | 14.398 ± 0.338 | 14.046 ± 0.575 | 13.515 ± 0.67 | 16.367 ± 0.890 | 14.006 ± 0.800 | 0.059 |
| | 6 | 14.510 ± 1.02 | 17.607 ± 0.642 | 14.776 ± 1.38 | 12.698 ± 0.69 | 10.994 ± 2.22 | 0.004 |
| | 7 | 59.61 ± 12.2 | 56.62 ± 16.4 | 13.31 ± 1.03 | 80.11 ± 21.0 | 12.96 ± 0.90 | 0.032 |
| Creatinine (mg/dL) | 0 | 0.2783 ± 0.0127 | 0.4137 ± 0.0385 | 0.2771 ± 0.0287 | 0.2925 ± 0.019 | 0.3167 ± 0.032 | 0.008 |
| | 6 | 1.1493 ± 0.059 | 1.1215 ± 0.0715 | 1.0690 ± 0.0528 | 0.8993 ± 0.247 | 1.1057 ± 0.106 | 0.716 |
| | 7 | 3.437 ± 0.868 * | 3.516 ± 1.04 | 1.015 ± 0.0467 | 3.301 ± 0.815 * | 1.131 ± 0.109 | 0.131 |

$\alpha - 0.05$

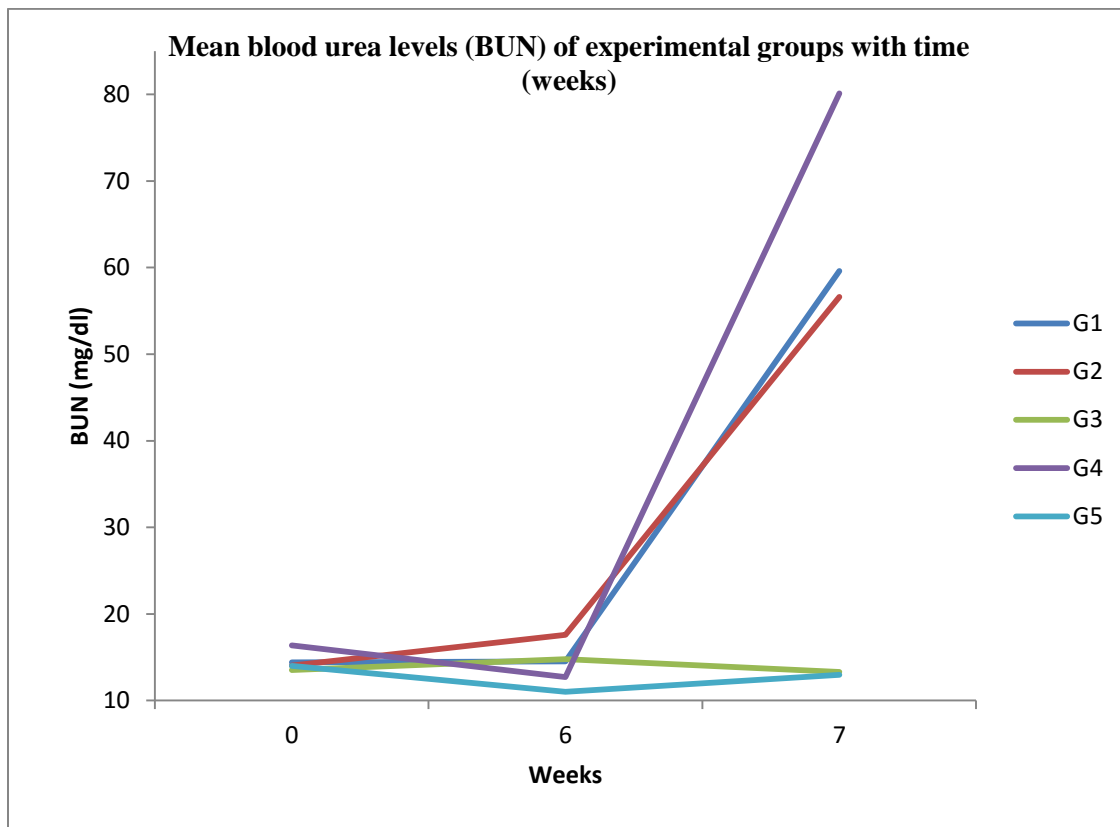


Figure 9: Line graph showing mean blood urea nitrogen (BUN) levels of experimental groups at weeks 0, 6 and 7

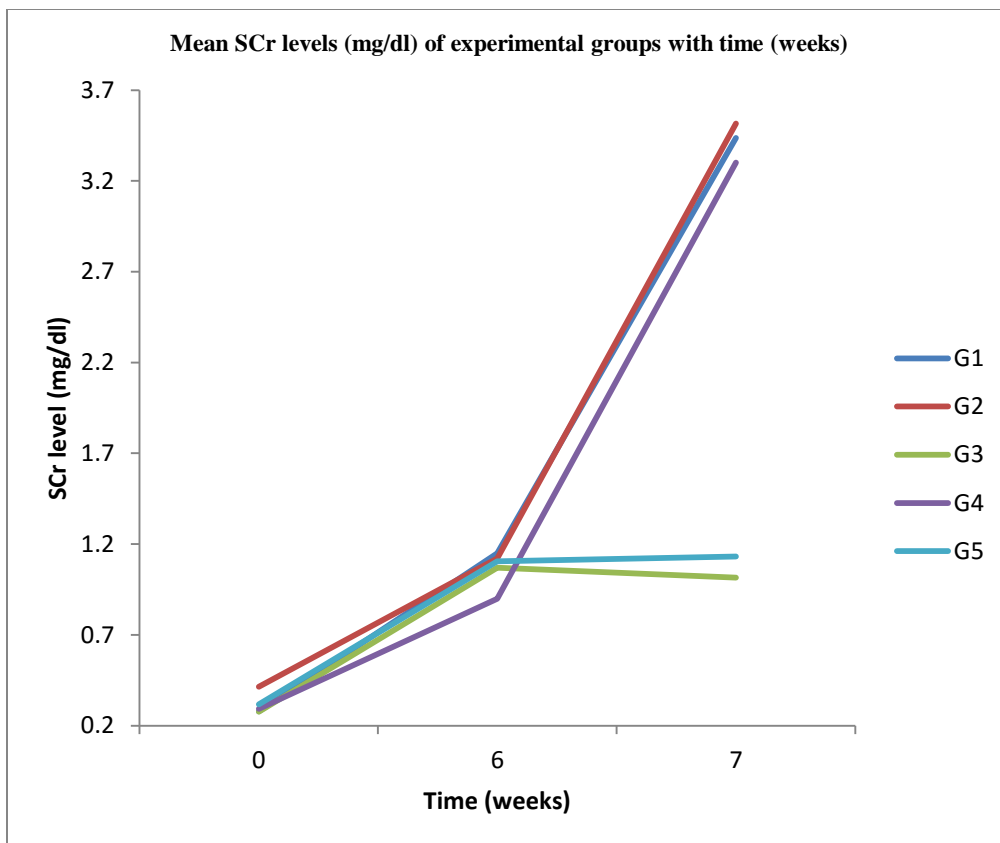


Figure 10: Line graph showing serum creatinine (SCr) levels at weeks 0, 6 and 7

4.9 Stereological assessments

4.9.1 Glomerular volume

One-way analysis of variance test showed that the absolute volumes of glomeruli in rats kidneys were significantly different ($p = 0.006$) as shown in *Table 8*. Paired t-test analysis also showed that the absolute volume of glomeruli in G2 rat kidneys was significantly higher than glomeruli of rats in G4 ($p = 0.02$). Also, paired t-test showed that glomerular volume of rat kidneys in G3 was significantly greater than for those in G1 ($p = 0.005$). The same test showed significantly greater glomerular volume in G5 than G2. In addition, paired t-test analysis indicated a higher volume of glomeruli in G3 compared to G4 as shown in *Table 9*.

Table 8: Summary of absolute glomerular volume among treatment groups

| | Absolute Glomerular volume \pm S.E Mean ($\times 10^3 \mu\text{m}^3$) | | | | |
|------------------|---|------------------|------------------|-----------------|---------|
| G1 | G2 | G3 | G4 | G5 | P-value |
| 22944 \pm 789* | 24904 \pm 894 | 26308 \pm 1015 | 22343 \pm 853* | 26191 \pm 919 | 0.006 |

T-test results indicated by (*) means $p\text{-value} < 0.05$

Table 9: Summary of post HOC analysis for glomerular volume

| Pairs | T-value | DF value | P-value |
|--------|---------|----------|---------|
| G1, G3 | -2.62 | 147 | 0.005 |
| G2,G4 | 2.07 | 129 | 0.02 |
| G2,G5 | -2.99 | 131 | 0.002 |
| G3,G4 | -2.99 | 131 | 0.003 |

4.9.2 Number-weighted volume fraction of proximal tubular epithelial cells

One-way ANOVA indicated that there was a significant difference in the relative PCT volume among experimental groups (p-value = 0.00 as can be seen in *Table 10*) with G3 recording the highest mean value (1.8681 ± 0.15 %) and G4 recording the least (0.2516 ± 0.097 %). The mean PCT volumes G3 and G5 were not significantly different from each other. Paired t-test analysis showed that the relative volume of PCT in G3 was significantly higher than in G1, G2 and G4 (p = 0.005). Performance of paired t-test analysis again showed that the relative volume of PCT for G5 was significantly greater than in G1, G2 and G4 (p = 0.000).

Table 10: Summary of ANOVA test of PCT volume

| | Number weighted volume fraction of PCT (%) | | | | |
|-------------------|--|-------------------|--------------------|-------------------|---------|
| G1 | G2 | G3 | G4 | G5 | P-value |
| 0.2839 ± 0.09 | 0.3077 ± 0.08 | 1.8365 ± 0.25 | 0.2516 ± 0.097 | 1.8681 ± 0.15 | 0.00 |

$\alpha - 0.05$

Table 11: Post HOC analysis of PCT volume

| Pairs | T-value | DF | P-value |
|-------|---------|----|---------|
| G1,G3 | 5.80 | 3 | 0.005 |
| G1,G5 | 8.84 | 4 | 0.000 |
| G2,G3 | 5.81 | 3 | 0.005 |
| G2,G5 | 9.06 | 4 | 0.000 |
| G3,G4 | 5.89 | 3 | 0.005 |
| G4,G5 | 8.94 | 5 | 0.000 |

$\alpha - 0.05$

4.10 Histological features of kidneys sections of rats of various experimental groups

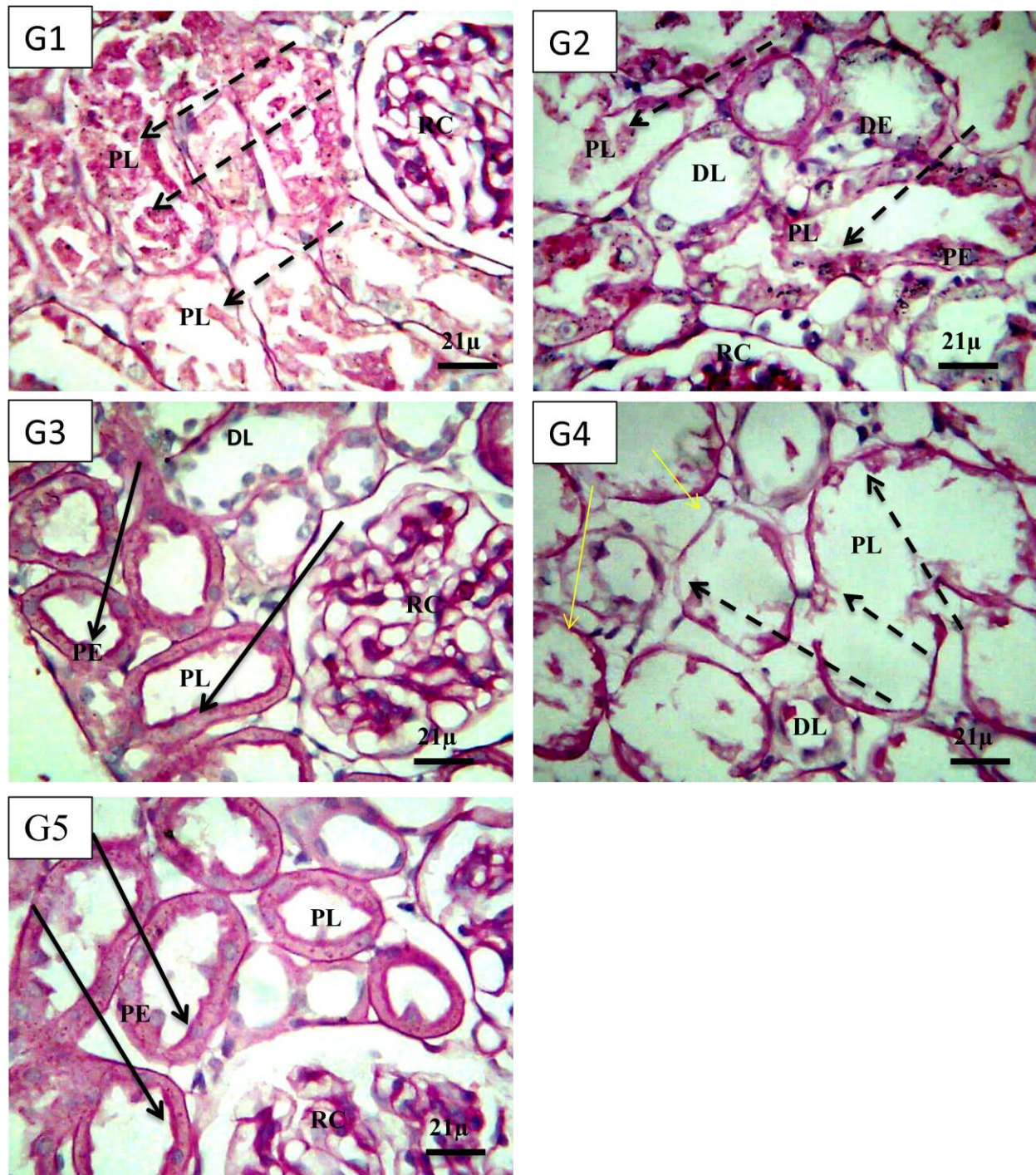


Figure 11 (G1 – G5): Micrographs of PAS stained kidney sections showing proximal tubular necrosis. (See legend to Figure 13 on next page).

Legend (Figure 11): **PE** – proximal convoluted tubular epithelium, **PL** – proximal tubular lumen, **DE** – distal convoluted tubular epithelium, **DL** – distal convoluted tubular lumen, **RC** – renal corpuscle, yellow arrow point to PCT basement membrane, black dashed arrows point to necrotised PCT cells and bold complete arrow show intact PCT cells and lumen

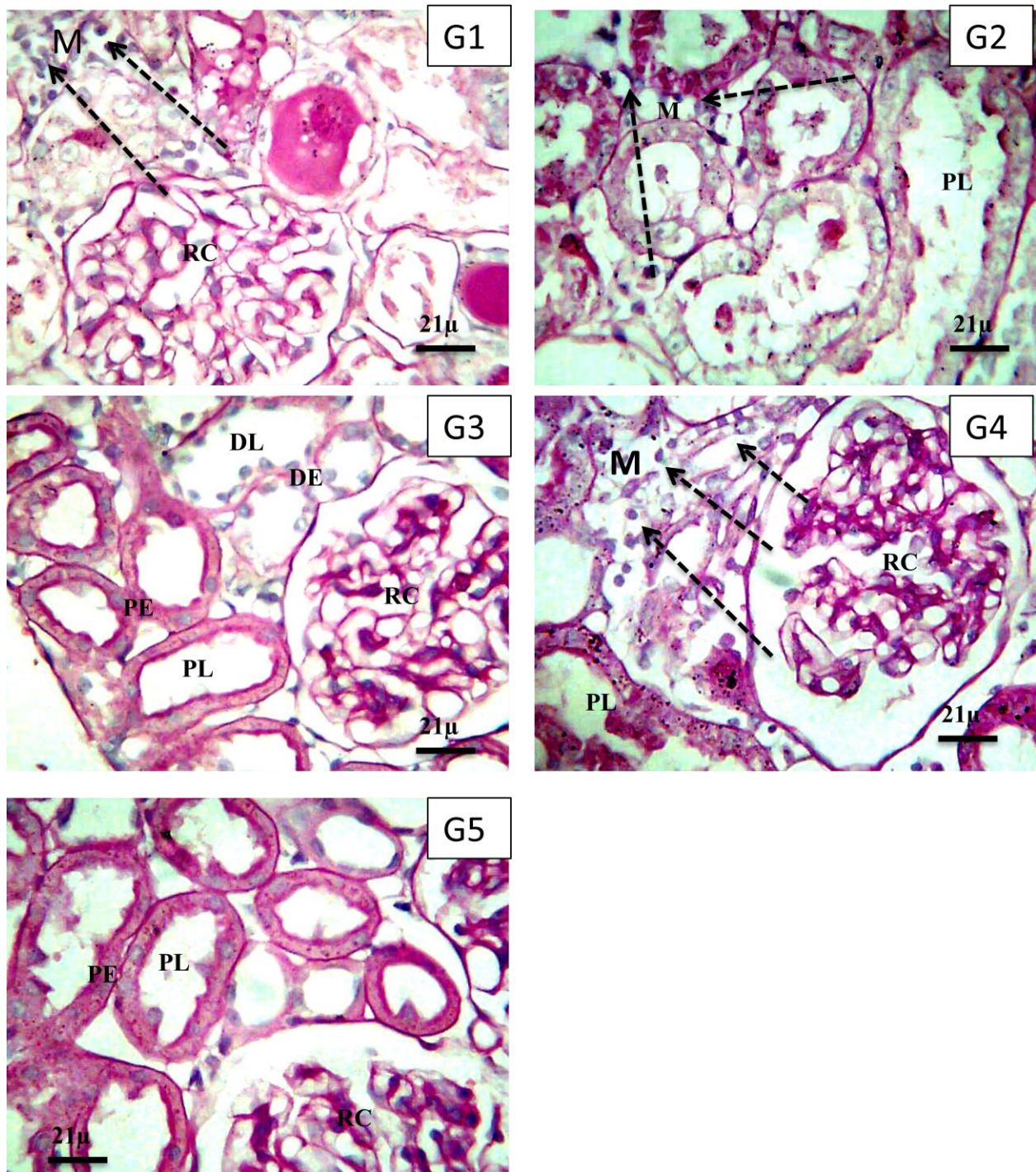


Figure 12 (G1 – G5): Micrographs of PAS stained kidney sections showing mononuclear cell infiltration in GM treated groups. (See legend on next page).

Legend (Figure 12): Dashed arrows point to mononuclear cell infiltration (**M**), **PE** – proximal convoluted tubular epithelium, **PL** – proximal tubular lumen, **DL** – distal convoluted tubular lumen, **RC** – renal corpuscle.

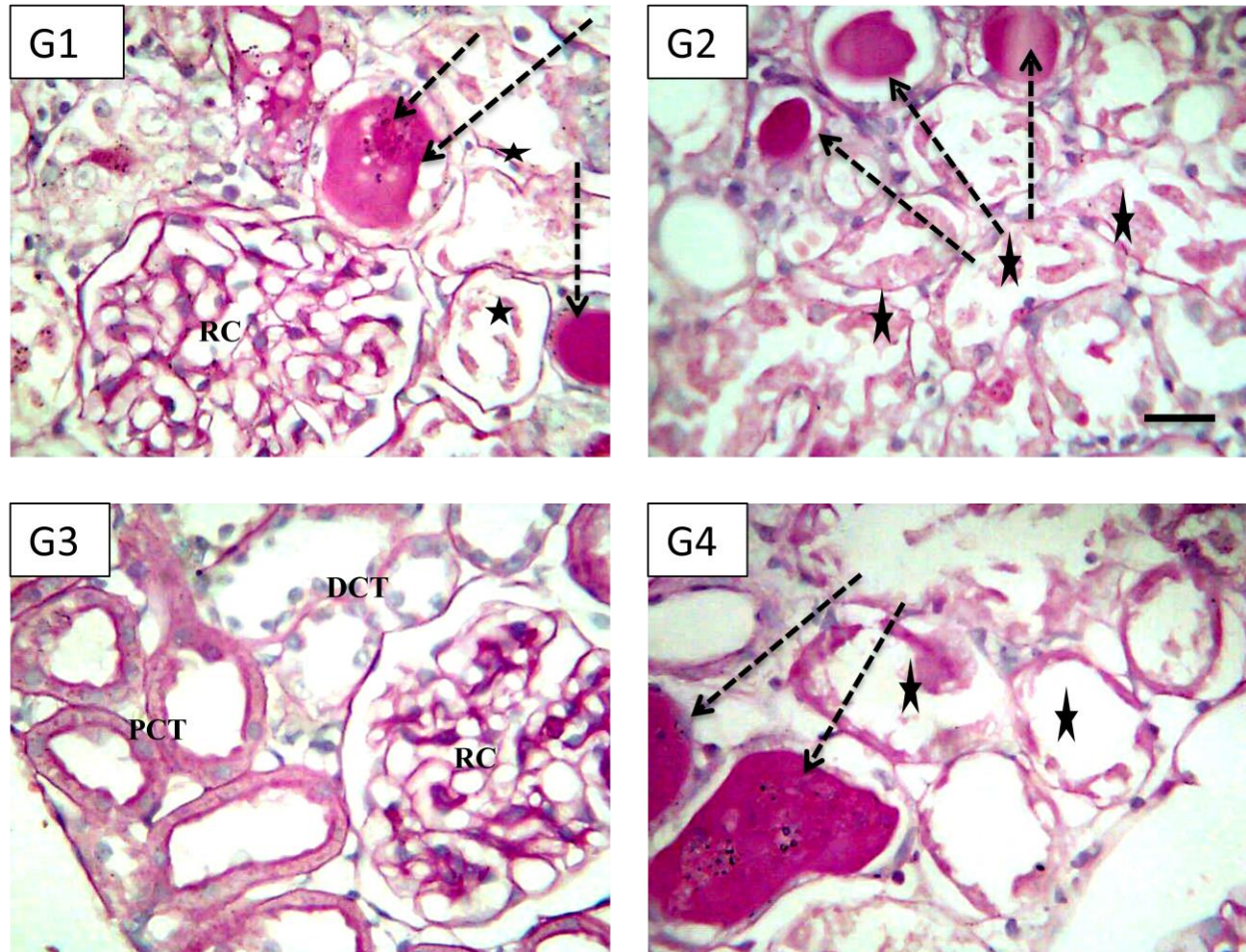


Figure 13 (G1 – G4): Micrographs of PAS stained kidney sections showing colloidal material in renal tubules of GM treated rats (G1, G2 and G4).

KEY: Dashed arrows point to colloidal material in renal tubules; **stars** indicate areas with necrotised and degenerated PCT cells, **PCT** – proximal convoluted tubules, **DCT** – distal convoluted tubules, **GT** – glomerular tuft, **PL** - proximal tubular lumen

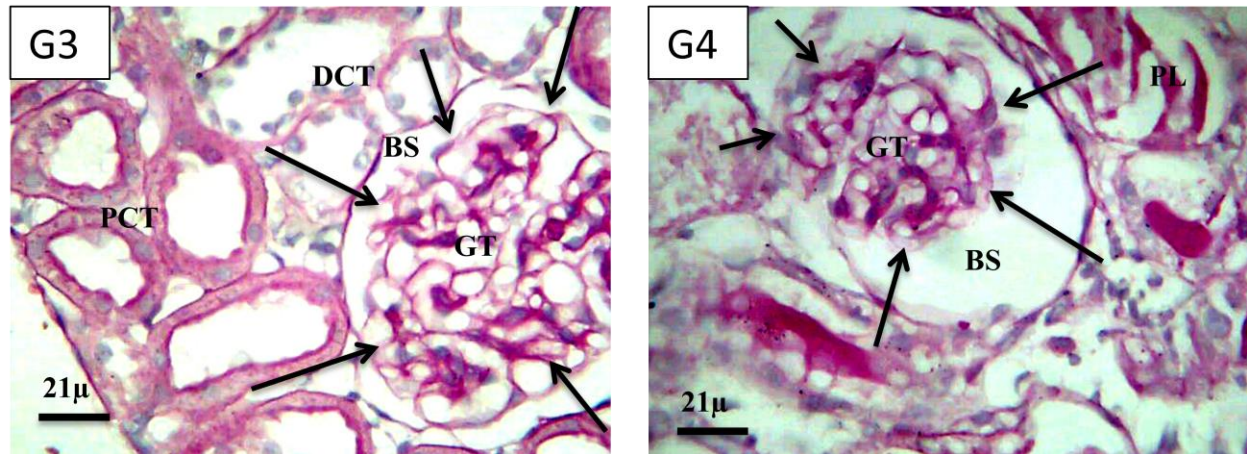


Figure 14 (G3 – G4): Micrograph of PAS stained kidney sections of GM only (G4) and control group (G3) showing glomerular shrinkage (g) in G4 and normal glomerulus (G) in G3.

Legend: PCT – proximal convoluted tubules, DCT – distal convoluted tubules, bold complete arrows point to GT – glomerular tuft, PL - proximal tubular lumen, BS – Bowman's space

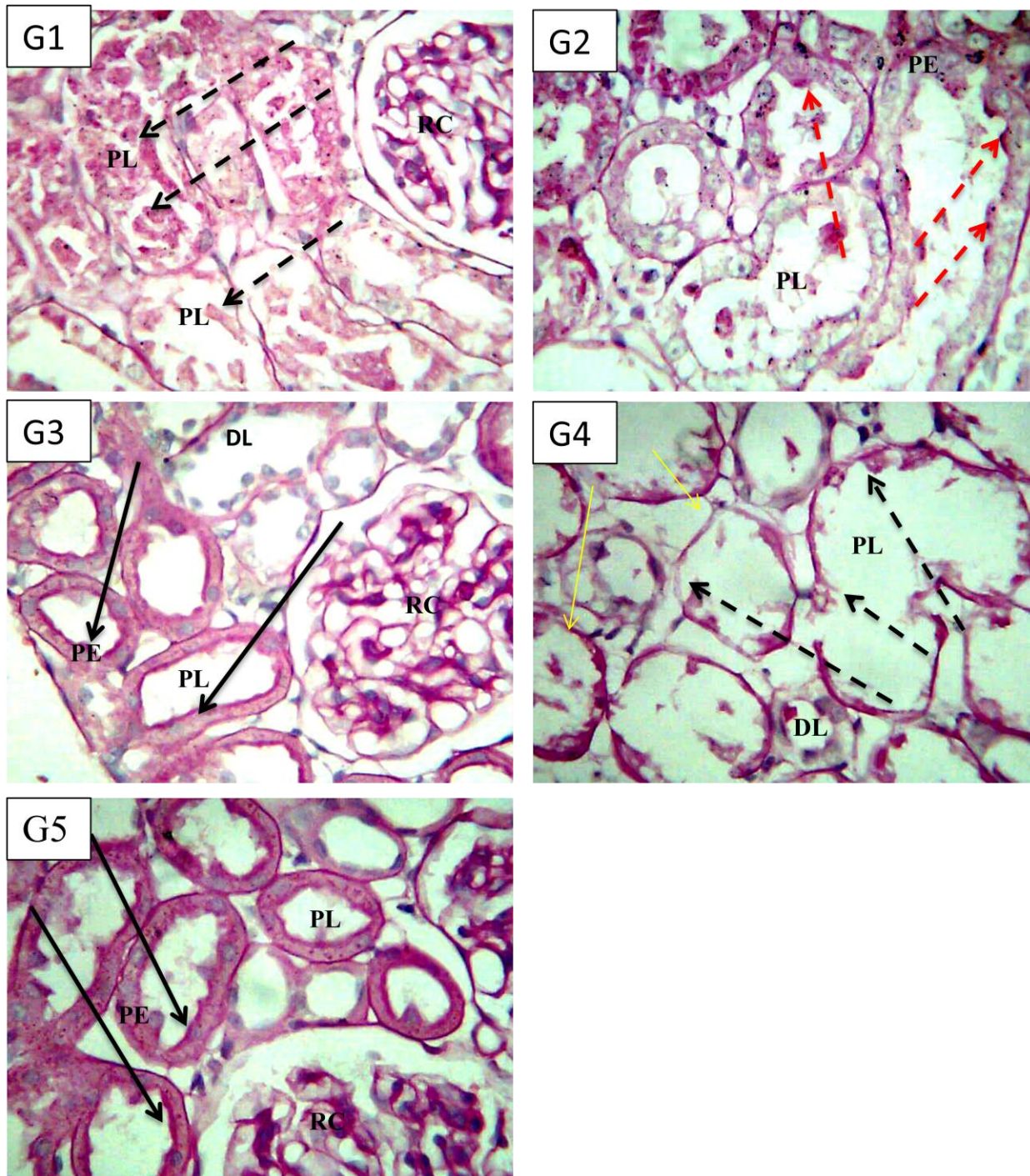


Figure 15 (G1 – G5): Micrographs of PAS stained kidney sections showing loss of brush border in GM treated groups (See legend on next page).

Legend to Figure 15: Dashed black arrows point to areas with brush border loss, dashed red arrows point to areas with patches of brush border, complete yellow arrows point to basement membrane of PCTs, complete black arrows point to intact brush border of PCTs.

CHAPTER FIVE

5.0 DISCUSSIONS

5.1 General

Gentamicin (GM) is an aminoglycoside antibiotic derived from *Micromonospora purpurea* (a gram positive bacterium found in soil or water) and is highly potent and efficient in the treatment of life-threatening bacterial infections. The use of this drug is however limited by its nephrotoxic effect on the kidney (Bhatia et al., 2012) which essentially excretes the drug. About 5 % of GM is actively reabsorbed and preferentially accumulate in the proximal tubular cells where it elicits its toxic effect (Mingeot-Leclercq & Tulkens, 1999; Yanagida et al., 2004). The nephrotoxicity involves generation of ROS generation and accumulation, consumption of antioxidant defense mechanisms, glomerular congestion and acute tubular necrosis leading to diminished creatinine clearance and renal dysfunction (Mingeot-Leclercq & Tulkens, 1999; Hur et al., 2013).

Higher and uncontrolled ROS production leads to extensive oxidation of cell components and irreversible cell/tissue damage underlying the acute pathology of many disease and pathological states (Fraga & Oteiza, 2011). Flavanols and procyanidins are nevertheless chemically able to prevent oxidation, and their presence/administration has been associated with a decrease in oxidative stress markers in animals and humans (Fraga & Oteiza, 2011).

Many researchers have therefore focused on the use of antioxidants to mitigate the effect of GM on kidney structure and function (Khan, 2011; Tavafi et al., 2012). Available literature is however void of effect of cocoa flavanols on GM-induced nephrotoxicity.

The present study was to test the hypothesized therapeutic effect of natural cocoa ingestion in rats with gentamicin-induced acute kidney injury. This view is based on extensive reports on the intimate relationship of reactive oxygen species and the pathophysiology of GM-induced AKI. To ameliorate the nephrotoxic effect of GM, many antioxidant containing substances have been tested and proposed to have ROS scavenging capacity. It was expected that the antioxidant capacity of cocoa polyphenols would mitigate the toxic effect of GM on the kidneys.

The grouping and treatment of animals are summarized in the table below:

Table 1: Experimental Interventions

| Group (G) | Treatment | Duration (weeks) | | | | | | | |
|-----------|--------------------|------------------|---|---|---|---|-----|---|---|
| | | 1 | 2 | 3 | 4 | 5 | 6 | 7 | 8 |
| G1 | Rat chow and water | → | | | | | | | |
| | 2 % NCS | → | | | | | | | |
| | GM | | | | | | → | | |
| G2 | Rat chow and water | → | | | | | | | |
| | 2 % NCS | → | | | | | | | |
| | GM | | | | | | ▼ → | | |
| G3 | Rat chow and water | → | | | | | | | |
| | NCS | | | | | | | | |
| | GM | | | | | | | | |
| G4 | Rat chow and water | → | | | | | | | |
| | NCS | | | | | | | | |
| | GM | | | | | | → | | |
| G5 | Rat chow and water | → | | | | | | | |
| | NCS | → | | | | | | | |
| | GM | | | | | | | | |

5.1.1 Mortality

A total number of 3 rats were lost before the end of the treatment as shown in *Table 2*. One each from G1 and G4 died at week 0 (start) and 6 respectively as a result of injury to thoracic viscera in the course of blood sampling by cardiac puncture. Another rat was lost from G1 post treatment and during the night. Post mortem was however not done to ascertain the cause of death. It can therefore only be speculated that severe nephrotoxic injury or infection may be responsible. Extreme care is therefore required in the collection of blood by cardiac puncture so as not to injure the animal.

5.1.2 Effect of cocoa on fluid consumption.

It was observed from this study that rats in groups fed on natural cocoa had higher median fluid intake compared to those that were not fed on cocoa. The reason for this trend is unclear. Kaur (1992) reported that cocoa contains theobromine which has diuretic and vasodilative effect. If the report by Kaur (1992) is right, then this trend could be explained by diuretic and vasodilative effect of cocoa. Thus, the higher intake of fluid among cocoa fed rat groups could be due to increased urine production and increased fluid intake (*Refer to Tables 5 and 6*).

5.1.3 Body weight

At the end of week 6 (cocoa treatment), weight among NCS and non NCS fed rat was not significantly different. However, at the end of week 7, rats that received gentamicin lost weight compared to those that did not receive GM. Rats in these groups could be said to be in a diseased state (AKI) as a result of GM nephrotoxicity. This may have resulted in loss of appetite and hence decreased food (chow) intake (*Table 4*).

5.1.4 Effect of GM on selected biochemical markers

Studies on GM-induced nephrotoxicity have showed clearly that administration of GM even at low doses result in deranged SCr and BUN levels (Khan, 2011; Aslam et al., 2014). This study established that the administration of 100 mg/kg daily for 5 days resulted in significant increases in SCr and BUN levels in rats treated with GM, whether they were preloaded with NCS or not. This trend was however not observed in control and cocoa only treated groups. Although, SCr levels significantly increased in GM treated rats, the values corresponded to their mean body weights. G2 rats which recorded the highest mean weight (*Table 4*) had a higher level of SCr compared to G4 (*Table 7*).

Marked elevations of serum creatinine and urea concentration were suggested as a significant functional impairment of kidney in GM-induced nephrotoxicity (Tavafi et al, 2012). Serum creatinine concentration is a more potent indicator than the urea in the first phases of kidney disease. Furthermore, urea concentrations begin to increase only after parenchymal injury (Tavafi et al, 2012).

Baseline levels of urea by one way analysis of variance test showed that there was no significant difference among all 5 groups of rats ($p = 0.059$, $p > 0.05$). However, this rose steadily to become significant at the end of week 6 with a p-value of 0.004 although values remained within a normal range. This could probably be as a result of normal physiologic changes in growth. At the end of week 7, urea levels rose up steeply ($p = 0.032$) in GM treated groups with G4 recording the highest value of 80.11 ± 21.0 mg/dl and G2 recording least (56.62 ± 16.4 mg/dl). Urea levels at week 7 in non-NCS treatment groups (G3 and G4) were not significantly different from that at week 6 of the same animals (*Table 7*). The regular consumption of NCS could have

reduced the formation of nitrogenous waste resulting in G2 recording a lower value. Blood urea nitrogen (BUN) of rats that did not receive GM remained normal throughout the experimental period.

5.2 Histopathologic changes

Gentamicin is a positively charged chemical that strongly binds to the acidic phosphoinositide components of the brush border membrane which is a negatively charged portion of the proximal tubule (Hur et al., 2013). Gentamicin mainly acts on the cationic receptor, megalin, located deeply at the base of the brush border villi (Hur et al., 2013). The drug-receptor complex is rapidly internalized by lysosomes through pinocytosis and resulting in lysosomal phospholipidosis. This then disrupts a number of renal intracellular processes (Hur et al., 2013). In addition, GM is also believed to bind to iron, forming GM-iron complex which has been suggested to be a potent catalyst in the generation of ROS.

The pathological mechanisms involved in GM-induced nephrotoxicity has been established to therefore include the induction of oxidative stress by the generation of superoxide anions, hydroxyl radicals, hydrogen peroxide and reactive nitrogen species in kidney. This leads to renal injuries characterized morphologically by PCT epithelial desquamation, tubular necrosis and fibrosis, epithelial oedema, increase in monocyte or macrophage infiltration and glomerular hypertrophy (Nagai, 2006; Martinez-Salgado et al., 2007; Bhatia et al., 2012; Tavafi, 2013).

The implication of ROS and free radicals in GM-induced renal injuries has drawn many researchers towards the use of antioxidants with highly potent free radical scavenging capacity to attenuate GM-induced toxicities. In vivo and in vitro studies have shown that the scavengers of reactive oxygen metabolites are protective in GM-induced renal failure (Pedraza-Chaverri et al.,

2000). Thus, the administration of several compounds with antioxidant activity has been successfully used to prevent or ameliorate GM-induced nephrotoxicity (Ali, 2003; Stojiljkovic et al., 2012).

Evaluation of rat kidney sections among the 5 experimental groups revealed significant morphologic changes especially among GM treated rat. Kidney sections of control group and NCS only fed rats showed normal renal morphology. Kidney sections of rats treated with GM only as well as those pretreated with NCS and discontinued prior to GM administration (G1) revealed extensive proximal tubular necrosis with cast formation in the lumina due to tubular epithelial cell loss (*Figure 11*). There was complete loss of brush border (*Figure 15*) with massive mononuclear cell infiltration around glomeruli, tubules and within the renal interstitium (*Figure 12*). In addition, there was accumulation of colloidal material in the tubules and damage to interstitial tissue (*Figure 13*). These features, characteristic of nephrotoxicity, were observed to be moderate in sections of kidneys of rats fed on cocoa throughout the experimental period with administration of GM over the last 5 days (G2). The antioxidant and anti-inflammatory effects of cocoa flavanols could have ameliorated the toxic effect of GM in G2 rats.

Studies have showed that the retention of GM in PCT cells result in the generation of ROS and free radicals which are potent catalysts for inflammatory processes and precede GM-induced nephrotoxicity. Histomorphologic evaluation from the study supports the fact that GM is nephrotoxic. In this study, glomerular assessment in G3 and G5 showed normal morphology. On the contrary, glomerular shrinkage was observed in G4 kidney sections (*Figure 13*). This was however not obvious in G1 and G2 kidney sections.

In recent times, most researchers have adopted the use of design-based stereology to obtain unbiased estimates of tissues and this forms the basis for measuring morpho-functional correlates in normal and disease conditions.

The systematic and random sampling approaches were used to stereologically evaluate all rat kidneys in the various experimental groups. To obtain results with statistically significant accuracy, a large number of micrographs were used for the evaluation.

Stereological assessment of glomerular volume showed a significant decrease in glomerular volume in G4 kidney sections compared to control and cocoa fed groups ($p < 0.05$). This supports reports by Padmini & Kumar (2012) and Sepehri et al. (2013) that there is glomerular atrophy with GM administration. This could also be explained by the vasoconstrictive effect of ROS generated by GM (Randjelovic et al., 2012). Additionally, the number-weighted volume fraction of PCT epithelial cells showed that there were significant differences among experimental groups ($p = 0.00$) with G4 rat kidneys recording the least volume (*Table 10*). This result further strengthens the fact that GM nephrotoxic effect is particularly confined to the PCTs.

5.3 Effects of regular consumption of cocoa as opposed to discontinuous intake

Many researchers have reported an inverse association of between cocoa consumption and various disease conditions (such as cardiovascular disease, diabetes mellitus, malaria and obesity) in humans and experimental animals.

Cocoa polyphenols, most importantly, flavanols have been associated with numerous health benefits which include cardiovascular protection, defense against carcinogenesis and mediation

of inflammatory processes mainly through its free radical scavenging capacity found in its powerful antioxidants (Waterhouse et al., 1996; Wollgast & Anklam, 2000; Hollenberg, 2006; Addai, 2010; Sokpor et al., 2010).

Cocoa flavanols are rapidly absorbed upon ingestion reaching maximum plasma levels about 2 hours after ingestion and achieving elimination in about 6 hours (Baba et al., 2000; Schramm et al., 2001, Holt et al, 2002, Khan et al., 2014). There is however, delayed absorption of some epicatechin metabolites could occur with these metabolites remaining in systemic circulation for up to 24 hours. Cocoa flavanols absorbed in the small intestine, are normally cleared from the body over 24 hours. This presupposes that cocoa antioxidants are short lived and thus to gain full benefits of the product, it should be consumed on regular basis. A study by Hollenberg (2006) showed that cardiovascular protection by cocoa was pronounced with regular consumption as opposed to discontinuous intake.

The present study showed that histopathological changes were minimized in rat group fed continuously with cocoa (G2) as compared to G1 rats which discontinued cocoa intake prior to GM administration. It was evident that regular consumption of cocoa was protective against gentamicin-induced nephrotoxicity.

5.4 Summary of key findings

Administration of 100 mg/kg of GM i.p. daily for 5 consecutive days in rats resulted in significant rise in SCr and BUN levels (*Table 7*).

Severe nephrotoxicity was observed in rats given GM only (G4) as well as those pre-treated with cocoa for 6 weeks but discontinued intake during GM administration (G1). The observed histological changes were however moderate in G2 rats which were co-treated with GM and cocoa, suggesting that cocoa ameliorated GM effect on the kidneys (*Item 4.10*).

Nephrotoxicity of GM was characterized essentially by severe necrosis of PCT cells and cast formation in the lumina of PCTs, collection of colloidal material in lumina, loss of brush border, glomerular atrophy and infiltration of monocytic cells around glomeruli, PCTs and interstitium (*Item 4.10*).

Quantification of glomerular and proximal tubular cell volumes by means of a design-based unbiased stereology confirmed the nephroprotective effect of cocoa in GM-induced AKI (*Tables 8-10*).

Fluid intake was higher in cocoa fed groups (G1, G2 and G5) than those not fed with cocoa (G3 and G5) probably as a result of the vasodilative and diuretic effects of cocoa (*Table 5*).

A decrease in body weight was recorded with GM administration (*Table 3*).

5.5 Conclusion

The present study has demonstrated that there is severe nephrotoxicity (AKI) at a dose of 100 mg/kg intraperitoneal administration of GM for 5 consecutive days in rats. This is evidenced by kidney function test. It has also revealed the possible nephroprotective effect of cocoa with GM administration as shown histologically by moderate damage in G2 rat kidney sections. Thus, it could be suggested that gentamicin should be given at the lowest effective therapeutic doses in patients with normal kidney function.

The antioxidant capacity of cocoa was possibly responsible for the tissue protection and further strengthens the idea that GM-induced AKI is mediated by oxidative stress. Again, it could be suggested that antioxidant therapy should precede and be co-administered with GM. Kidney function should also be monitored for early detection of injury so as to give prompt treatment.

5.6 Limitations of the study

Due to lack of logistics, the study did not incorporate collection of urine for urinalysis which would have made it possible to estimate the glomerular filtration rate.

Due to lack of funds, the study also did not incorporate the estimation of lipid peroxidation and measurement of endogenous kidney antioxidant enzymes which would have emphasized the implication of oxidative stress in GM-induced AKI.

Due to limited number of rat cages, rats were put in groups instead of individual cages limiting the extent to which they could be monitored effectively.

5.7 Recommendations

- ✓ The exact mechanism underlying the potential therapeutic use of natural cocoa in preventing GM-induced nephrotoxicity needs to be elucidated in further research.
- ✓ Inclusion of female rats should be considered in further studies so as to identify any sexual differences in the therapeutic effect of natural cocoa in ameliorating kidney damage with GM usage.
- ✓ Measurement of the diameter of the glomerular basement membrane should be considered at the electron microscopy (EM) level to make evident changes that occur within the glomeruli.
- ✓ It is recommended that natural cocoa is consumed on regular basis to have its full benefits.

REFERENCES

- Abdel-Raheem, I.T., Abdel-Ghany, A. A. & Mohamed, A.G. (2009). Protective effect of quercetin against gentamicin-induced nephrotoxicity in rats. *Biological and Pharmaceutical Bulletin*, 32(1), 61-67.
- Abrokwa, F. K., Asamoah, K. A. & Esubonteng, P. K. A. (2009). Effect of intake of natural cocoa powder on some biochemical and haematologic indices in the rat. *Ghana Medical Journal*, 43(4), 164 - 168.
- Abu-Basha, E.A., Al-Shunnaq, A.F. & Gehring, R. (2013). Pharmacokinetics of Gentamicin C1, C1a, C2 and C2a in Broiler Chickens after IV, IM, SC and Oral Administration. *Journal of Bioequivalence and Bioavailability*, 5, 129-135. Doi:10.4172/jbb.1000146
- Addai, F. K. (2010). Natural cocoa as diet-mediated anti-malarial prophylaxis. *Medical Hypotheses*, 74, 825-830.
- Affram, K. O., Amoah, S. K., Ayetey, A. S. & Addai, F. K. (2008). *Regular ingestion of cocoa attenuates glycation of haemoglobin in streptozotocin-induced diabetic rats.* (Unpublished master's thesis).University of Ghana, Legon.
- Alchi, B., Nishi, S., Kondo, D., Kaneko, Y., Matsuki, A., Imai, N., ... & Gejyo, F. (2005). Osteopontin expression in acute renal allograft rejection. *Kidney International*, 67, 886 – 896.
- Ali, B. H. (2003). Agents ameliorating or augmenting experimental gentamicin nephrotoxicity: some recent research. *Food Chem Toxicol* 41:1447–1452.

- Ali, M. Z. & Goetz, M. B. (1997). A meta-analysis of the relative efficacy and toxicity of single daily dosing versus multiple daily dosing of aminoglycosides. *Clinical Infectious Diseases*, 24,796–809.
- Amrit, P. S., Arunachalam, M., Amteshwar, S. J., Nirmal, S. & Kuldeep, G. (2012). Animal models of acute renal failure. *Pharmacological Reports*, 64, 31 - 44.
- Aror, A., Byrem, T. M., Nair, M. G. & Stasburg, G. M. (2000). Modulation of liposomal membranes fluidity by flavanoids and isoflavanoids. *Archives Biochemistry Biophysics*, 373,102–109.
- Aslam, M., Dayal, D., Javed, K., Samim, M., Yadav, D., Zaidi, S. M. A., Singh, S. (2014). 8-dehydroxy chrysophenol isolated from extract of *Rheum emodi* enhance gentamicin induced nephrotoxicity in rat model. *World Journal of Pharmacy and Pharmaceutical Sciences*, 3(3), 833 – 849.
- Baba, S., Osakabe, N., Yasuda, A., Natsume, M., Takizawa, T., Nakamura, T., ... & Terao, J. (2000). Bioavailability of (-)-epicatechin upon intake of chocolate and cocoa in human volunteers. *Free Radical Research*, 33, 635–641.
- Baliga, R., Ueda, N., Walker, P. D. & Shar, S. V. (1999). Oxidant mechanisms in toxic acute renal failure. *American Journal of kidney disease*, 29(3), 465-477.
- Beauchamp, D., Laurent, G., Grenier, L., Gourde, P., Zanen, J., Heuson-Strennon, J. A., ... & Bergeron, M.G. (1997). Attenuation of Gentamicin-induced nephrotoxicity in rats by Fleroxacin. *Antimicrobial Agents and Chemotherapy*, 41(6), 1237-1245.

Bellomo, R. (2006). The epidemiology of acute renal failure: 1975 versus 2005. *Current Opinion on Critical Care*, 12(6), 557 - 560.

Bhatia, L., Bhatia, V., & Grover, M. (2012). Nephroprotective effect of fresh leaves extracts of *Sida Cordifolia Linn* in gentamicin induced nephrotoxicity in rats. *International Journal of Research in Pharmacy and Science*, 2(2), 151-158.

Bledsoe, G., Shen, B., Yao, Y. Y., Hagiwara, M., Mizell, B., Teuton, M., ... & Chao, J. (2008). Role of tissue kallikrein in prevention and recovery of gentamicin-induced renal injury. *Toxicology Science*, 102, 433–443.

Bolisetty, S & Agarwal A. (2007). Subclinical Kidney Injury Incites Endotoxin Hyperresponsiveness, *American Journal of Physiology* 293, F41-F42. Doi:10,1152/ajprenal.00224.2007

Bravo, L. (1998) Polyphenols: chemistry, dietary sources, metabolism, and nutritional significance. *Nutritive Review*, 56,317–333.

Briguori, C., Colombo, A., Airoidi, F., Morici, N., Sangiorgi, G. M., Violante, A., ... & Ricciardelli, B. (2005). Nephrotoxicity of low-osmolality versus iso-osmolality contrast agents: Impact of N-acetylcysteine. *Kidney International*, 68, 2250– 2255.

Coca, S. G., Yusuf, B., Shlipak, M. G., Garg, A. X. & Parikh, C.R. (2009). Long-term risk of mortality and other adverse outcomes after acute kidney injury: a systematic review and meta-analysis. *American Journal of Kidney Disease*, 53(6), 961-973.

COCOBOD. (2015). COCOALINK – Connecting Cocoa communities. Retrieved April 13, 2015, from http://www.cocobod.gh/coco_link.php.

Corcoran, M. P., McKay, D. L., & Blumberg, J. B. (2012). Flavonoid basics: Chemistry, sources, mechanisms of action, and safety. *Journal of Nutrition in Gerontology and Geriatrics*, 31(3), 176–189.

Costa, S. V. L., Gil, F. Z., Nascimento, G. & Cavanal, M. F. (1987). Evaluation of distal tubular function in aminoglycoside induced nephropathy. *Brazilian Journal of Medical and Biological Research*, 20(6), 833-836.

Crozier, S. J., Preston, A. G., Hurst, J. W., Payne, M. J., Mann, J., Hainly, L., ... & Miller, D.L. (2011). Cacao seeds are a “Super Fruit”: A comparative analysis of various fruit powders and products. *Chemistry Central Journal*, 5(5) <http://journal.chemistrycentral.com/content/5/1/5>

Cummings, B. S. & Schnellmann, R. G. (2001). Pathophysiology of nephrotoxic cell injury in diseases of the kidney and urogenital tract (pp. 1071 – 1136). Lippincott Williams & Wilkinson.

Cuzzocrea, S., Mazzon, E., Dugo, L., Serraino, I., Paola, R.D., Britti, D., ... & Salvemini, D. (2002). A role for superoxide in gentamicin-mediated nephropathy in rats. *European Journal of Pharmacology*, 450, 67-76.

Devarajan, P. (2006). Update on mechanism of ischaemic acute kidney injury. *Journal of the American Society of Nephrology*, 17:1503-1520.

- Dezfoolian, A., Panahi, M. & Feizi, F. (2009). Stereological evaluation of renal glomeruli in offspring of diabetic female rats. *Yakhteh Medical Journal*, 11(1), 17-22
- Donavan, J. I., Crespy, V. & Manach, C. (2001). Catechin is metabolized by both the small intestine and liver of rats. *Journal of Nutrition*, 131, 1753-1757.
- Edwards, C. Q., Smith, C. R., Baughman, K. L., Rogers, I. F. & Lietman, P.S. (1976). Concentrations of gentamicin and amikacin in human kidneys. *Antimicrobial Agents and Chemotherapy*, 9, 925-927
- Erdem, A., Gundogan, N. U., Usubutun, A., Kilinc, K., Erdem, S. R., Kara, A., ... & Bozkurt, A (2000). The protective effect of taurine against gentamicin-induced acute tubular necrosis in rats. *Nephrology Dialysis Transplant*, 15, 1175–1182.
- Erden, I. M. & Kahraman, A. (2000). The protective effect of flavonol quercetin against ultraviolet A induced oxidative stress in rats. *Toxicology*, 154, 21–29.
- Ergun, I., Kenan, K., Uruc, I., Ekmekci, Y., Canbakan, B., Erden, I., ... & Karatan, O. (2006). The safety of gadolinium in patients with stage 3 and 4 renal failure. *Nephrology Dialysis Transplant*, 21,697– 700.
- Etsey, A.N. (2009). Effect of regular ingestion of natural cocoa on testicular histology in streptozotocin-induced diabetic rats (unpublished master's thesis).University of Ghana, Legon.
- Ferguson, M. A., Vaidya, V., & Bonventre, J. V. (2008). Biomarkers of Nephrotoxic AKI. *Toxicology*, 245(3), 182-193. Doi:10.1016/j.tox 2007.12.024.

- Fraga, C. G. & Oteiza, P. I. (2011). Dietary flavanoids: Role of (-)-epicatechin and related procyanidins in cell signaling. *Free Radical biology and medicine*, 51(2011), 813-823.
- Fry, A.C. & Famington, K. (2006). Management of acute renal failure. *Postgraduate Medical Journal*, 82,106 -116. Doi:10.1136/pgmj.2005.038588.
- Gandhi, T. K., Burstin, H. R., Cook, E. F., Puopolo, A. L., Haas, J. S., Brennan, T. A., ... & Bates, D. W. (2000). Drug complications in outpatients. *Journal of General Internal Medicine*, 15(3), 149-154.
- Garg, A.X., Kurz, A., Sessler, D.L., Cuerden, M., Robinson, A., Mrkobrada, M., ...& Devereaux, P. J. (2014). Perioperative aspirin and clonidine and risk of acute kidney injury: A randomized clinical trial. *Journal of the American Medical Association*, 312(21), 2254-2264.
- Geleilete, T. J., Melo, G.C., Costa, R.S., Volpini, R.A., Soares, T.J. & Coimbra, T.M. (2002). Role of myofibroblasts, macrophages, transforming growth factor-beta endothelin, angiotensin-II, and fibronectin in the progression of tubulointerstitial nephritis induced by gentamicin. *Journal of Nephrology*,15, 633-42.
- Goldberg, R. & Dennen, P. (2008). Long-term outcomes of acute kidney injury. *Advances in Chronic Kidney Disease*, 15(3), 297-307.
- Hebel, R. & Stromberg, M. W. (1976). *Anatomy of the Laboratory Rat*. (pp.62-63). Baltimore, U.S.A The Williams and Wilkins Company,U.S.A, pages 62-63.

- Hollenberg, N. K. (2006). Vascular action of cocoa flavanols in humans: The root of the story. *Journal of Cardiovascular Pharmacology*, 47(Suppl 2), S99-S102.
- Holt, R. R., Schramm, D. D., Keen, C. L., Lazarus, S. A. & Schmitz, H. H. (2002). Chocolate consumption and platelet function. *Journal of American Medical Association*, 287, 2212–2213.
- Hopper, L., Kroon, P.A., Rimm, E.B., Cohn, J.S., Harvey, I., Le Cornu, K.A., & Cassidy, A (2008). Flavonoids, flavonoid-rich foods, and cardiovascular risk: a meta-analysis of randomized controlled trials. *American Journal of Clinical Nutrition*, 88:38-50.
- Hoste, E. A. & Kellum, J. A. (2006). Acute kidney injury: epidemiology and diagnostic criteria. *Current Opinion on Critical Care*, 12(6), 531-537.
- Hoste, E. A. & Schurgers, M. (2008). Epidemiology of acute kidney injury: How big is the problem? *Critical Care Medicine*, 36(4 Suppl), S146-S151.
- Hoste, E. A., Clermont, G., Kersten, A., Venkataraman, R., Angus, D. C., De Bacquer, D. & Kellum, J. A. (2006). RIFLE criteria for acute kidney injury are associated with hospital mortality in critically ill patients: a cohort analysis. *Critical Care*, 10(3), R73.
- Hsu, C. Y., McCulloch, C. E., Fan, D., Ordoñez, J. D., Chertow, G. M. & Go, A.S. (2007). Community-based incidence of acute renal failure. *Kidney International*, 72(2), 208-212.
- Humes, D.H. (1988). Aminoglycoside nephrotoxicity. *Kidney International*, 33(4):900-911

- Hur, E., Garip, A., Camyar, A., Ilgun, S., Ozisik, M., Tuna, S., ...& Duman, S. (2013). The effects of vitamin D on gentamicin-induced acute kidney injury in experimental rat model. *International Journal of Endocrinology*, 313528. <http://dx.doi.org/10.1155/2013/313528>.
- Jeon, S. E., Choi-Kwon, S., Park, K. A., Lee, H. J., Park, M. S., Lee, J. H., ... & Park, K.C. (2003). Dietary supplementation of (-) Catechin protects against UVB-induced skin damage by modulating antioxidant enzyme activities. *Photodermatol Photoimmunol Photom*, 19, 235–241.
- Junqueira, L.C. & Carneiro, J. (2005). *Basic Histology - Text & Atlas* (11th Ed.). New York: McGraw-Hill.
- Kadkhodae, M., Khastar, H., Faghihi, M., Ghaznavi, R. & Zahmatkesh, M. (2005). Effects of co-supplementation of vitamins E and C on gentamicin-induced nephrotoxicity in rat. *Experimental Physiology*, 90,571-576.
- Kalava, M.S. & Menon, S. (2012). Ameliorative effect of *Volvariella volvacea* aqueous extract (billiard ex fries) singer on gentamicin induced renal damage. *International Journal of Pharma and Bio Sciences*, 3(3): B 105-117
- Karahan, I., Atessahin, A., Yilmaz, S., Ceribasi, A.O. & Sakin, F. (2005). Protective effect of lycopene on gentamicin-induced oxidative stress and nephrotoxicity in rats. *Toxicology*, 215, 198–204.

- Kaufman, J., Dhakal, M., Patel, B. & Hamburger, R. (1991). Community-acquired acute renal failure. *American Journal of Kidney Disease*, 17(2), 191-198.
- Kaul, N., Siveski-Iliskovic, N., Hill, M., Slezak, J. & Singal, P. K. (1993). Free radicals and the heart. *Journal of Pharmacology and Toxicology Methods*, 30, 55-67.
- Kaur, J. (1992). Diuretic activity of organomercury (II) complexes of theophylline and theobromine. *Journal of Inorganic Biochemistry*, 48 (4), 305–310.
- Keen, C. L., Holt, R. R., Oteiza, P. I., Fraga, C. & Schimitsz, H. H. (2005). Cocoa antioxidants and cardiovascular health. *American Journal of Clinical Nutrition*, 81, 298S–303S.
- Kehrer, J. P. (1993). Free Radicals as Mediators of Tissue Injury and Disease. *Critical Reviews in Toxicology*, 23(1), 21-48. Doi:10.3109/10408449309104073
- Kellum, J. A. & Lamiere, N. (2013). Diagnosis, evaluation and management of acute kidney injury: A KDIGO Summary (Part I). *Critical Care*, 17(1), 204
- Khan, M. R., Badar, I. & Siddiquah, A. (2011). Prevention of hepatorenal toxicity with *Sonchus asper* in gentamycin treated rats. *BMC Complementary and Alternate Media*, 11, 113
- Khan N., Khymenets, O., Urpí-Sardà M., Tulipani, S., Garcia-Aloy, M., Monagas, M., ... & Andres-Lacueva, C. (2014). Cocoa Polyphenols and Inflammatory Markers of Cardiovascular Disease. *Nutrients* 6, 844-880. Doi:10.3390/nu6020844

- Kidney Disease: Improving Global Outcomes (KDIGO) (2012) Acute Kidney Injury Work Group. KDIGO Clinical Practice Guideline for Acute Kidney Injury. *Kidney International*, Suppl. 2, 1–138.
- Kohli, H. S., Bhaskaran, M. C., Muthukumar, T., Thennarasu, K., Sud, K., Jha, V., ... & Sakhuja (2000). Treatment-related acute renal failure in the elderly: A hospital-based prospective study. *Nephrology Dialysis Transplantation*, 15(2), 212-217.
- Kromhout, D., Menotti, A., Kesteloot, H. & Sans, S. (2002). Prevention of coronary heart disease by diet and lifestyle: Evidence from prospective cross-cultural, cohort, and intervention studies. *Circulation*, 105, 893–898.
- Kumar, P. & Clark, M. (Eds.) (2001). *Clinical Medicine*. W.B. Saunders: Harcourt Publishers Limited
- Lamuela-Raventós, R. M., Romero-Pérez, A. I., Andrés-Lacueva, C. & Tornero, A. (2005). Review: Health Effects of Cocoa Flavanoids. *Food Science and Technology International*, 11(3), 159-176.
- Lapi, F., Azoulay, L., Niazi, T., Yin, H., Benayoun, S. & Suissa, S. (2013). Androgen deprivation therapy and risk of acute kidney injury in patients with prostate cancer. *Journal of the American Medical Association*, 310(3), 289-296.
- Laudau, B.R. (1980). *Essential human anatomy and physiology*. (2nd Ed.). Illinois, USA: Scott, Foresman and Company.

- Lee, K. W., Kim, Y. J., Lee, H.J. & Lee, C. Y. (2003). Cocoa has more phenolic phytochemical and a higher antioxidants capacity than teas and red wine. *Journal of Agric Food Chem*, *51*, 7292–7295.
- Levy, J., Brown, E., Daley, C. & Lawrence, A. (2009). Oxford Handbook of Dialysis (pp. 10) Oxford: Oxford University Press.
- Luft, F. C. & Kleit, S. A. (1974). Renal parenchymal accumulation of aminoglycoside antibiotics. *Journal Infectious Disease*, *130*, 656-659.
- Maldonado, P. D., Barrera, D., Rivero, I., Medina-Campos, O. N., Hernández-Pando, R. & Pedraza-Chaverri, J. (2003). Antioxidant S-allylcysteine prevents Gentamicin-induced oxidative stress and renal damage. *Free Radical Biology and Medicine*, *35*(3), 317-324.
- Manach, C., Williamson, G., Morand, C., Scalbert, A., & Rémésy, C. (2005). Bioavailability and bioefficacy of polyphenols in humans. I. Review of 97 bioavailability studies *American Journal of Clinical Nutrition*, *81*(Suppl), 230S– 242S.
- Markowitz, G. S. & Perazella, M. A. (2005). Drug-induced renal failure: A focus on tubulointerstitial disease. *Clinical Chimica Acta*, *351*, 31– 47.
- Markowitz, G. S., Fine, P. L., Stack, J. I., Kunis, C. L., Radhakrishnan, J., Palecki, W., ...& D'Agati, D.V. (2003). Toxic acute tubular necrosis following treatment with zoledronate (Zometa). *Kidney International*, *64*(1), 281-289.
- Martinez-Salgado, C., Lopez-Hernandez, F. J. & Lopez-Novoa, J. M. (2007). Glomerular nephrotoxicity of aminoglycosides. *Toxicology and Applied Pharmacology*, *233*, 86-98.

- Matthew, T. H. (1992). Drug-induced renal disease. *Medical Journal Aust*, 156, 724–728.
- Mehta, R. L., Pascual, M., Soroko, S. & Chertow, G. (2002). Diuretics, mortality and nonrecovery of renal function in acute renal failure. *Journal of The American Medical Association*, 288(20), 2547-2553.
- Mehta, R. L., Kellum, J. A., Shah, S. V., Molitoris, B. A., Ronco, C., Warnock, D. G. & Levin, A. (2007). Acute kidney injury network: report of an initiative to improve outcomes in acute kidney injury. *Critical Care*, 11(2), R31.
- Meyer, T. W. & Hostetter, T. H. (2007). Uremia. *New England Journal of Medicine*, 357(13), 1316-1325.
- Mingeot-Leclercq, M. P. & Tulkens, P. M. (1999). Aminoglycosides: nephrotoxicity. *Antimicrobial Agents and Chemotherapy*, 43(5), 1003-1012.
- Min-Hsiung P., Ching-Shu L. & Chi-Tang Ho (2010). Anti-inflammatory activity of natural dietary flavonoids. *Food Functions*, 1, 15-31.
- Monagas, M., Urpi-Sarda, M., Sanchez-Patan, F., Llorach, R., Garrido, I., Gomez-Cordoves, C., ...& Bartolome, B.(2010). Insights into the metabolism and microbial biotransformation of dietary flavan-3-ols and the bioactivity of their metabolites. *Food Functions*, 1, 233–253.
- Murphy, K. J., Chronopoulos, A. K., Singh, I., Francis, M. A., Moriarty, H., Pike, M. J., ... & Sinclair, A. J. (2003). Dietary flavanols and procyanidins oligomers from cocoa

- (*Theobroma Cacao*) inhibit platelet function. *American Journal of Clinical Nutrition*. 77(6), 1466–1473.
- Mursu, J., Voutilainen, S., Nurmi, T., Rissanen, T. H., Virtanen, J. K., Kaikkonen, J., ... & Salonen, J. T. (2004). Dark chocolate consumption increases HDL-cholesterol concentration and chocolate fatty acids may inhibit lipid peroxidation in Healthy humans. *Free Radical Biology Medicine*. 37(37a), 107–113.
- Nagai, J. & Takano, M. (2004). Molecular aspects of renal handling of aminoglycosides and strategies for preventing the nephrotoxicity. *Drug Metabolism and Pharmacokinetics*, 19(3), 159-170.
- Nagai, J. (2006). Molecular mechanisms underlying renal accumulation of aminoglycoside antibiotics and mechanism-based approach for developing nonnephrotoxic aminoglycoside therapy. *Yakugaku Zasshi*, 126(5), 327-35
- Nash, K., Hafeez, A. & Hou, S. (2002). Hospital-acquired renal insufficiency. *American Journal of Kidney Disease*. 39(5), 930-936.
- Oliveira, T. B. & Genovese, M. I. (2013). Chemical composition of cupuassu (*Theobroma grandiflorum*) and cocoa (*Theobroma cacao*) liquors and their effects on streptozotocin-induced diabetic rats. *Food Research International*, 51(2), 929-935. Doi: 10.1016/j.foodres.2013.02.019
- Ortega, A., Ramila, D., Izquierdo, A., González, L., Barat, A., Gazapo, R., ... & Esbrit, P. (2005). Role of the reninangiotensin system on the parathyroid hormone–related protein

- overexpression induced by nephrotoxic acute renal failure in the rat. *Journal of the American Society of Nephrology*, *16*, 939–949.
- Ottaviani, J. I., Momma, T. Y., Heiss, C., Kwik-Urbe, C., Schroeter, H. & Keen, C.L. (2011). The stereochemical configuration of flavanols influences the level and metabolism of flavanols in humans and their biological activity *in vivo*. *Free Radical Biology and Medicine*, *50*, 237–244.
- Padmini, M. P. & Kumar, J. V., (2012). A histopathological study on gentamicin induced nephrotoxicity in experimental albino rats. *ISOR Dental and Medical Sciences*. ISSN: 2279-0861, *1*(1), 14-17.
- Parlakpınar, H., Tasdemir, S., Polat, A., Bay-Karabulut, A., Vardi, N., Ucar, M. & Acet, A. (2005). Protective role of caffeic acid phenethyl ester (CAPE) on gentamicin-induced renal toxicity in rats. *Toxicology*, *207*(2), 169-177.
- Pedraza-Chaverri, J., Maldonado, P. D., Medina-Campos, O., Olivares-Corichi, I. M., Granados-Silvestre, M. A., Hernandez-Pando, R., ... & Ibarra-Rubio, M.E. (2000). Garlic ameliorates gentamicin nephrotoxicity: relation to antioxidants. *Free Radical Biology and Medicine*, *29*(7), 602-611.
- Pen, M. H., Lai, C. H. & Ho, C.T. (2010). Anti-inflammatory activity of natural dietary flavonoids. *Food Functions*, *1*, 15-31.
- Perazella, M. A. (2005). Drug-induced nephropathy: an update. *Expert Opinion on Drug Safety*, *4*(4), 689-706.

- Perazella, M.A. (2009). Renal vulnerability to drug toxicity. *CJASN*, 4(7): 1275-1283.
- Pruiska, E. M. & Schacht, J. (1995). Formation of free radicals by gentamicin and iron and evidence of an iron-gentamicin complex. *Biochemical Pharmacology*, 50(11), 1749-1752.
- Rahman, M., Shad, F. & Smith, M. C. (2012). Acute Kidney Injury: A Guide to Diagnosis and Management. *American Family Physician*, 86(7):631-639.
- Randjelovic, P., Veljkovic, S., Stojiljkovic, N., Velickovic, L., Sokolovic, D., Stoilkovic, M., ... & Ivan Ilic. (2012). Protective effect of selenium on gentamicin-induced oxidative stress and nephrotoxicity in rats. *Drug and Chemical Toxicology*, 35(2), 141–148.
- Riff, L. J. & Jackson, G.G. (1971). Pharmacology of gentamicin in man. *The Journal of Infectious Diseases*, 24(Supple 1), 98-105
- Salem, E.A., Salem, A.N., Kamel, M., Maarouf, A. M., Bissada, N. K., Hellstrom, W. J. G. & Eiadl M. (2010). Amelioration of gentamicin nephrotoxicity by green tea extract in uninephrectomized rats as a model of progressive renal failure. *Renal Failure*, 32(10), 1210–1215.
- Schramm, D. D., Wang, J. F., Holt, R. R., Ensunsa, J. L., Gonsalves, J. L., Lazarus, S. A., ... & Keen, C. L. (2001). Chocolate procyanidins decrease the leukotriene-prostacyclin ratio in humans and human aortic endothelial cells. *American Journal of Clinical Nutrition*, 73, 36 – 40.

- Sepehri, G. H., Derakhshanfar A. & Saburi L. (2013). Does Propylthiouracil Increase the Gentamicin-Induced Nephrotoxicity In Rat? *Iranian Journal Basic Medical Science*, 16, 1190-1195.
- Sha, S. H. & Schacht, J. (1999). Stimulation of free radical formation by aminoglycoside antibiotics. *Hearing Research*, 128 (1-2), 112-118.
- Shu-Hui, J., Cheng-Hsien, C., Yung-Ho, H., Chun-Cheng, H., Tso-Hsiao, C., Heng, L., ... & Yuh-Mou Sue. (2007). Tetramethylpyrazine protects rat renal tubular cell apoptosis induced by gentamicin. *Nephrology Dialysis Transplant*, 22, 732-739.
- Sokpor, G., Addai, F. K., Gyasi, R. K., Bugjei, K. A. & Ahenkorah, J. (2012). Voluntary ingestion of natural cocoa extenuated hepatic damage in rats with experimentally induced chronic alcoholic toxicity. *Functional Foods in Health and Disease*, 2(5), 166- 187.
- Sreedevi, A., Jyothi, Y.P.L. & Bharathi, K. (2011). Protective effect of fruits of *Pedaliium murex* against gentamicin-induced nephrotoxicity in rats. *International Journal of Phytopharmacology*, 2(1), 27-36.
- Stojiljkovic, N., Stoilkovic, M., randjelovic, P., Veljkovic, S. & Mihailovic D. (2012). Cytoprotective effect of vitamin c against gentamicin-induced acute kidney injury in rats. *Experimental and toxicologic pathology*, 64(1-2), 69-74.
- Tavafi, M., Ahmadvand, H. & Toolabi P. (2012). Inhibitory Effect of Olive Leaf Extract on Gentamicin-Induced Nephrotoxicity in Rats. *Iranian Journal of Kidney Disease*, 6, 25-32.

- Uchino, S., Kellum, J.A., Bellomo, R., Doig, G.S., Morimatsu, H., Morgera, S., ... & Ronco, C. (2005). Acute renal failure in critically ill patients: a multinational, multicenter study. *Journal of the American Medical Association*, 294:813–818.
- Veljković, M., Ilić, S., Stojiljković, N., Velicković, L., Pavlović, D., Radenković, M., ... & Golgnjatović, M. (2015). Beneficial Effects of Green Tea Extract in Gentamicin-Induced Acute Renal Failure in Rats. *Scientific Journal of the Faculty of Medicine*, 32(1), 51-58.
- Volpini, R. A., Balbi, A. P. C., Costa, R. S. & Coimbra, T. M. (2006). Increased expression of p38 mitogen activated protein kinase is related to the acute renal lesions induced by gentamicin. *Brazilian Journal of Medical and Biological Research*, 39, 817–823.
- Waterhouse, A. L., Shirley, J. R. & Donovan, J. L. (1996). Antioxidants in Chocolate. *The Lancet*, 348, 834.
- Wollgast, J. & Anklam, E. (2000). Review on polyphenols in *Theobroma cacao*: changes in composition during the manufacture of chocolate and methodology for identification and quantification. *Food Research International*, 33, 423–447.
- Xie, Y., Nishi, S., Iguchi, S., Imai, N., Sakatsume, M., Saito, A., ... & Gejyo, F. (2001). Expression of osteopontin in gentamicin-induced acute tubular necrosis and its recovery process. *Kidney International*, 59, 959–974.
- Yaman, I. & Balikci, E. (2010). Protective effects of nigella sativa against gentamicin-induced nephrotoxicity in rats. *Experimental and Toxicologic Pathology*, 62, 183-90.

Yanagida, C., Ito, K., Komiya, I. & Horie, T. (2004). Protective effect of fosfomycin on gentamicin-induced lipid peroxidation of rat renal tissue. *Chemico- Biological Interactions*, 148, 39-147.

Young, B., Heath, J. W., Stevens, A., Lowe, J. S., & Deakin, P. J. (2006). Wheater's Functional Histology (5th Ed.), Churchill Livingstone: Elsevier Limited.

Zager, R.A. (1997). Pathogenetic mechanisms in nephrotoxic acute renal failure. *Seminars in Nephrology*, 17(1), 3-14.

APPENDIX I

a. Intraperitoneal Injection

- i. Rats were tightly held at the back (neck and back region) so that the head was slightly lower than the back feet.
- ii. The rat's left lower quadrant of abdomen was cleaned with alcohol swab.
- iii. A 1 mL syringe (containing required amount of gentamicin or 0.9 % normal saline) was inserted at an angle of less than 15 into the left lower quadrant.
- iv. The syringe was slightly drawn back to make sure it was not in a blood vessel.
- v. Injection was then administered.

b. Collection of blood for biochemical analysis (Cardiac puncture)

- i. Rats were anaesthetized by ether inhalation until consciousness was lost
- ii. A 2 mL syringe was fixed to a 23G × 1" hypodermic needle was inserted into the left ventricle by moving about 1 cm superiorly above the xiphisternum and 1 cm laterally to the left and into the 5th intercostal space.
- iii. The plunger of the syringe was drawn back to collect about 1.5 mL of blood into gel separation sample bottles

APPENDIX II

Stain

1% Periodic Acid Solution (200 mL)

Periodic Acid.....2g

Distilled water.....200 mL

Schiff Reagent

Commercially prepared200 mL

Meyer's Haematoxylin (IL)

Haematixylin.....1 g

Sodium Iodate.....0.2 g

Potassium Alum.....50 g

Citric Acid.....1 g

Chloral hydrate.....50 g

Distilled water.....100 mL

Flow chart of procedure for PAS staining

Clear in Xylene (3 changes; I=2 mins, II=1 min, III= 1 min)



Rehydrate in Alcohol (2 changes in Absolute Alcohol 1 min each, 70% Alc 50 secs)



Bring to water (1 min)



1% Periodic Acid Solution (5 mins)



Bring to running water (5 mins)



Rinse in 2 changes of distilled water



Schiff Reagent (15 mins)



Rinse in 0.5% sodium metabisulphate (3 times) slides fully submerged



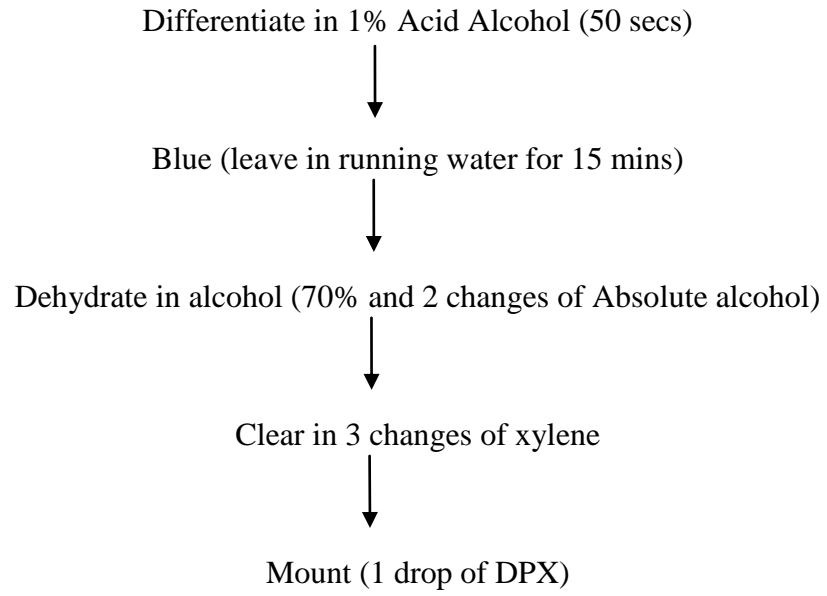
Wash in running water (5 mins)



Celestine blue-haemalum sequence

- a) Stain in Celestine blue (5 mins)
- b) Rinse in water
- c) Stain in Meyer's Haematoxylin (5 mins)
- d) Wash well in running water





APPENDIX III

Protocol for preparation of 10 % buffered formalin

A. 10% buffered formaldehyde pH 7.3 (IL)

| | |
|---|--------|
| Formalin (37 - 40% w/v - BDH, England)..... | 100 mL |
| Distilled water..... | 900 mL |
| Sodium dihydrogen otophosphate (NaH_2PO_4)..... | 4g |
| Disodium hydrogen otophosphate (Na_2HPO_4)..... | 6.5g |

Apparatus and equipment

- ✓ Electronic balance (Mettler CH – 8606)
- ✓ 1000 mL flask
- ✓ Magnetic stirrer
- ✓ pH meter (Philips, PW9418)
- ✓ Conical flasks and beakers
- ✓ Plastic weighing container
- ✓ Measuring cylinder