



REVIEW ARTICLE

Obstetrics

Disseminated adult Wilms tumor in pregnancy: Leveraging multidisciplinary care in a low-resource setting

Perez Sepenu¹  | Alim Swarray-Deen² | Aba Scott³ | Theodore K. Boafor²  |
Winfred K. Baah⁴ | Mathew K. Kyei⁵ | Jerry Coleman²

¹Department of Obstetrics & Gynecology, Maternal-Fetal Medicine Unit, Korle Bu Teaching Hospital, Accra, Ghana

²Department of Obstetrics & Gynecology, University of Ghana Medical School, Accra, Ghana

³National Centre for Radiotherapy, Oncology and Nuclear Medicine, Korle Bu Teaching Hospital, Accra, Ghana

⁴Department of Medicine & Therapeutics, University of Ghana Medical School, Accra, Ghana

⁵Department of Surgery, Urology Unit, University of Ghana Medical School, Accra, Ghana

Correspondence

Theodore K. Boafor, Department of Obstetrics and Gynecology, University of Ghana Medical School, College of Health Sciences, PO Box 4236, Korle Bu, Accra, Ghana.

Email: theodoreboafor@gmail.com, tboafor@ug.edu.gh

Abstract

Wilms tumor (WT) occurring in adults is rare and even much more rarely found to coexist with pregnancy. Clinical outcome in adults is worse overall compared with pediatric patients with WT and is often misdiagnosed with no standardized protocols for care guided by high-evidence clinical trials. We present a case of a 23-year-old woman diagnosed with WT who was found to be pregnant immediately following nephrectomy. Workup findings showed that she had disseminated disease but was successfully managed in a multidisciplinary team setting with modified intrapartum chemotherapy followed by postpartum chemotherapy. In low-resource settings, management protocols for adult patients with WT can be individualized by multidisciplinary teams to leverage available resources for best outcomes.

KEYWORDS

adult Wilms tumor, antenatal chemotherapy, multidisciplinary care, nephroblastoma, pregnancy, renal tumor

1 | INTRODUCTION

It is rare for malignancies to coexist with pregnancy, with an incidence of 1 in 1000 to 1 in 6000 pregnancies in high-resource countries.¹ A coexisting malignancy during pregnancy can pose seemingly impossible clinical decisions for the remainder of the gestation period. Women face the choice between continuing the pregnancy, which can complicate treatment and allow for further disease progression and or harm to the growing fetus, or terminating the pregnancy to allow for the timely administration of lifesaving treatment.² Although rare, the most common cancers diagnosed during pregnancy include but are not limited to breast, melanoma, thyroid, cervical cancers, lymphomas, and very rarely Wilms tumor (WT).²⁻⁴

WT, or nephroblastoma, constitutes 6% to 7% of all pediatric tumors and is the most common primary renal tumor in children.⁵ It is

rarely seen in adults, with an incidence of 0.2 cases per million,¹ and predominantly occurs in younger adults with a median diagnosis at age 34 years.⁵ Although adult WT is histologically similar to pediatric nephroblastoma, the clinical presentation tends to differ, with adults having a higher stage at diagnosis and poorer overall prognosis.⁶ Women tend to have a higher survival rate compared with men.⁷

The coexistence of WT and pregnancy is extremely rare, with only few cases have been reported in the literature.¹

Management of WT in adults is not currently standardized. Generally, it follows the treatment modalities for children as recommended by Children's Oncology Group (COG) and International Society of Pediatric Oncology (SIOP) protocols.⁵ When it occurs in the setting of pregnancy, it becomes a quagmire of complex management choices that is not eased by preexisting treatment guidelines or clinical trials to dictate the standard of care. We present a

case of disseminated WT in a pregnant 23-year-old woman who was managed by a multidisciplinary team (MDT) where chemotherapy was initiated antenatally followed by successful delivery and disease management.

2 | CASE REPORT

A 23-year-old Ghanaian woman of African ancestry initially presented to a peripheral health facility with a year's history of left flank swelling. She did not seek any medical care when she noticed the mass, until symptoms became associated with fever, chills, and weight loss. She was initially diagnosed as having a urinary tract infection and treated with antibiotics. She was eventually referred to the urologist when symptoms worsened and also became associated with frank hematuria.

Findings from an abdomino-pelvic computed tomography (CT) scan with contrast showed a large mass involving the upper and middle poles of the left kidney measuring 11 × 11 × 16 cm. The rest of the abdominal organs (liver, gallbladder, pancreas, spleen, right kidney) were normal (Figures 1–3).

Results from CT renal angiography without and with intravenous contrast showed a large necrotic mass lesion involving the upper part of the left kidney. Lobar branches were seen arising from the main left renal artery outside the kidney contour with the tumor seen stretching the lobar branches. A tiny accessory renal arterial branch was seen arising from the proximal part of the main renal artery (Figure 4).

A full blood cell count showed a hemoglobin level of 10.3g/dL with white cell and platelet counts within normal limits. Results

from renal function test were unremarkable, with a creatinine level of 59mmol/L. Findings from liver function test and clotting profile were both normal.

A left radical nephrectomy was performed with pathology notable for WT. Macroscopy included a left nephrectomy specimen of 1kg and measuring 21 × 13 × 9cm with the cut surface showing a firm yellow-grey tumor measuring 14 × 11 × 10cm in diameter;

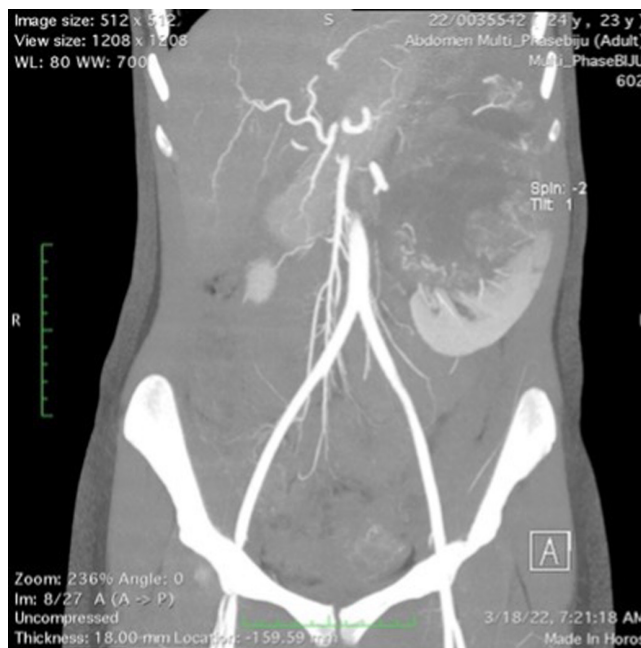


FIGURE 2 Abdomino-pelvic computed tomography scan showing left Wilms tumor (coronal view).

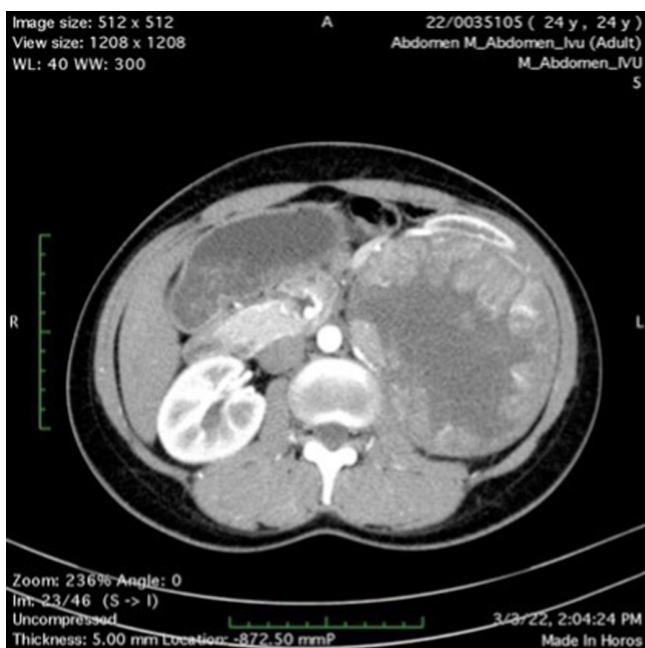


FIGURE 1 Abdomino-pelvic computed tomography scan showing left Wilms tumor (axial view).

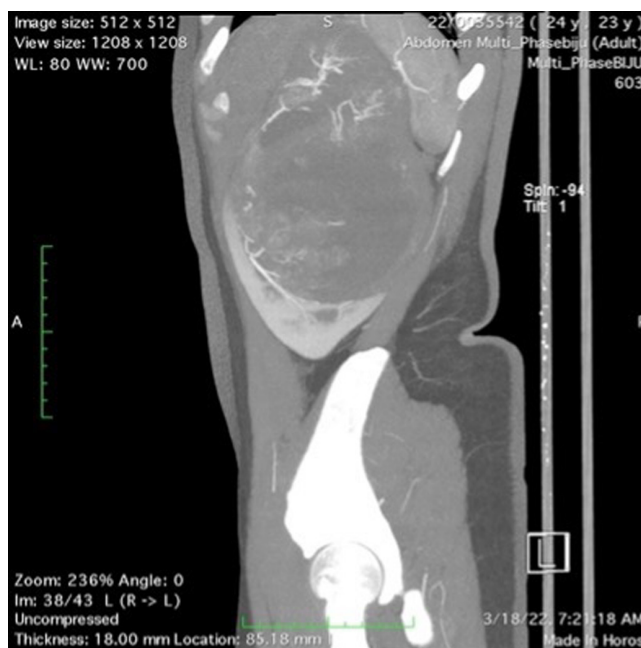

FIGURE 3 Abdomino-pelvic computed tomography scan showing left Wilms tumor (sagittal view).

the tumor appeared to have broken through the capsule, and there was evidence of tumor rupture. Findings from microscopy showed a predominantly tubular pattern with luminal borders separated

by tightly bound cells, embryonal-looking rosettes, and pseudo rosettes. These features of epithelial cells with minimal blastema and stroma were in keeping with nephroblastoma (WT). No unfavorable features were reported.

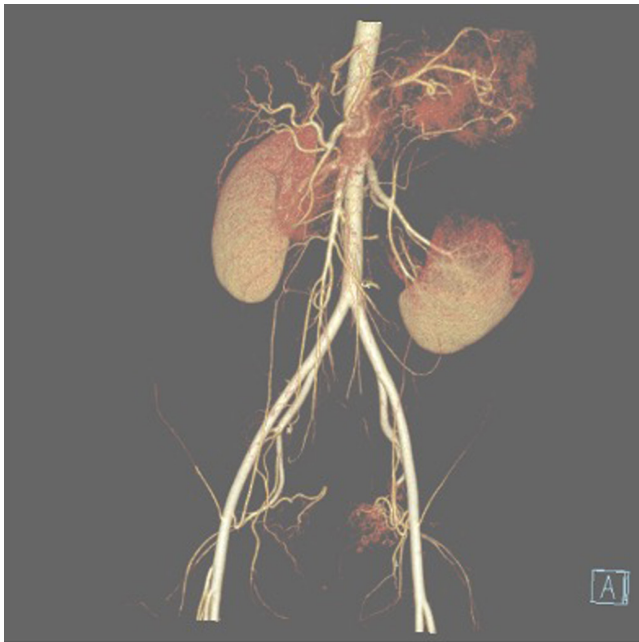

FIGURE 4 Computed tomography renal angiography showing a large mass lesion of the left kidney.

Further immunohistochemistry results were positive for paired box gene 8 (PAX8), p53, Wilms' tumor suppressor gene (WT1), epithelial membrane antigen (EMA), pan cytokeratin (PanCK), neuron-specific enolase (NSE), and CD56 and showed predominantly epithelial cells with minimal blastema and stroma (Figure 5).

Due to persistent postoperative vomiting for 5 days, a urine pregnancy test was performed and noted to be positive. Pelvic ultrasound confirmed the presence of a 6-week gestational sac.

An MDT consisting of maternal-fetal medicine specialists, oncologists, urologists, renal physicians, neonatologists, anesthesiologists, a dietician, and clinical psychologists was formed to guide her management. The initial management plan of the MDT was to offer adjuvant radiotherapy after radical nephrectomy preceded by termination of pregnancy with ovarian cryopreservation. This decision was made because of the disease stage (stage III, due to tumor rupture) and gestational age. The patient was counseled on her diagnosis and the MDT recommendation. She, however, declined the ovarian cryopreservation because of financial constraints and refused termination of pregnancy, and hence could not have the radiation therapy. She was then scheduled to undergo follow-up in the obstetric renal high-risk clinic.

IMMUNO HISTO CHEMISTRY	
CASE SUMMARY	
CASE NO	:22MLI6560
SPECIMEN	:Paraffin block - Left Radical Nephrectomy
RESULT	: <ul style="list-style-type: none"> • CK 7 : Negative • PAX 8 : Positive • Vimentin : Negative • p53 : Positive • Ki-67 : High index • WT 1 : Positive • EMA : Positive • Pan CK : Positive • Synaptophysin : Negative • NSE : Positive • CD 56 : Positive • CD99 : Negative • AMACR : Negative
DIAGNOSIS	:Features are Consistent with <i>Adult Wilms Tumor</i>
	Note : The tumour is Epithelial predominant and blastema and stroma are minimal
	Anaplasia is not noted in the sections provided
	Please correlate with macroscopic and concomitant findings of the sections for accurate staging

FIGURE 5 Immunohistochemistry report.

She defaulted her follow-ups and presented 4 months later to the obstetric renal high-risk clinic with complaints of recurrent left flank pain. A repeat abdominopelvic ultrasound demonstrated a huge retroperitoneal mass in the left renal bed with associated satellite masses suggestive of tumor recurrence with intra-abdominal dissemination and metastasis to the left hepatic lobe, as well as a live pregnancy at 24 weeks 6 days gestation. She continued to express the desire to continue her pregnancy. A fetal anomaly scan was performed and results were unremarkable.

The multidisciplinary team, in consultation with the pediatric oncology team, counseled the patient and provided a workup for her to receive palliative chemotherapy with doxorubicin (adriamycin) 50 mg/m² and cyclophosphamide 450 mg/m² for three cycles three weekly, until 34 to 35 weeks of gestation, to allow recovery from side effects of chemotherapy, especially neutropenia, with an aim of delivery of the baby at 38 weeks of gestation. She was to have optimum fetal surveillance with biweekly growth scans, daily fetal kick counts, twice-daily fetal Dopplers, umbilical artery Dopplers as indicated, maturation of fetal lungs at 28 weeks and 34 weeks using intramuscular dexamethasone, and delivery via induction of labor at 34 weeks.

Following delivery, she was to have the full pediatric chemotherapy protocol for WT, which included vincristine, adriamycin and dactinomycin in addition to the doxorubicin and cyclophosphamide followed after cycle 6 by irradiation to the whole liver as 19.8 Gy in 11 fractions. Due to the chemotherapy, she was also counseled not to breastfeed the baby.

She was mostly managed on an outpatient basis except in the immediate postchemotherapy period when she was admitted for fetal surveillance (daily fetal kick count, twice daily fetal heart rate monitoring, and weekly nonstress test) and maternal monitoring.

Intramuscular dexamethasone 6 mg 12 hourly for 48 h was administered for fetal lung maturation at 28 and 34 weeks.

The planned third cycle of adriamycin and cyclophosphamide was suspended due to persistent pancytopenia at 34 weeks of gestation to allow platelet levels to improve as it was close to the time of delivery.

The patient requested an elective cesarean section to be followed by contraception after she had been counseled on the possible options including induction of labor. She delivered via an uneventful elective cesarean section at 37 weeks 6 days to a live female neonate with Apgar scores of 8 and 9 at 1 and 5 minutes, respectively and a birth weight of 2435 g (third percentile for gestational age). A postplacental copper intrauterine device was inserted for family planning. The baby was examined by the neonatologist immediately following delivery and found to be healthy. Due to the antenatal exposure of the fetus to chemotherapy, gonadal function assessment of the baby was planned within 6 months after delivery via assessment of levels of the anti-Müllerian hormone (AMH), follicle-stimulating hormone (FSH), luteinizing hormone (LH), and estradiol by a pediatric endocrinologist. The patient was discharged on postoperative day 3 in stable condition.

Three weeks after delivery when the wound was fully healed and the patient was fully recovered, she was worked up again to restart chemotherapy using the full pediatric WT protocol consisting of cyclophosphamide, doxorubicin, vincristine, dactinomycin, and adriamycin. She has since then received weekly intravenous vincristine for 10 weeks followed by a three-weekly intravenous vincristine regimen for five cycles (one dose given so far), intravenous dactinomycin on day 28 of initiation of vincristine followed by 6-weekly dactinomycin for five cycles (one dose given so far). Reassessment ultrasonography of the abdomen showed no intra-abdominal free fluid, lymphadenopathy, or mass lesions and two heterogeneous lesions at segment 6 and 4B of the liver measuring 5.2 and 3.2 cm.

She was offered follow-up of her gonadal function using evaluation of levels of her anti-AMH, FSH, LH, estradiol, and progesterone at 6 and 12 months postchemotherapy. She is currently doing very well at her last radio-oncology review and has given her consent for this case report.

3 | DISCUSSION

Only approximately 300 cases of nephroblastoma (WT) in adults have been documented in the literature with varying terminologies and confusing histological diagnosis.⁵ Nephroblastoma presents as a triphasic embryonal tumor with various proportions of blastema, stroma, and epithelial cells.⁸ Blastemal cells are the most malignant tumor component as they are the least differentiated with rapid mitotic activity. Epithelial components tend to be well differentiated with abortive tubules or glomeruli-like structure. Stromal components have moderate malignant potential with varying undifferentiated to partially differentiated mesenchymal cells.⁵ This patient had a monophasic tumor predominantly epithelial, which has a better prognosis because it is the least malignant component. Immunohistochemistry staining in African children with WT children show a preponderance of p53 mutation ranging from 8.3% to 60.3% compared with Caucasians (between 0% and 13.4%).⁹ This patient had a positive p53 mutation in addition to other mutations. This mutation is associated with more clinically aggressive disease even with favorable histology.⁹

The clinical presentation of WT is usually weight loss, flank pain, flank mass, or hematuria.¹⁰ All of these symptoms were present in our patient.

Abdominal ultrasound is the first diagnostic modality of choice to confirm a renal mass. CT scan and magnetic resonance imaging help to differentiate WT from other renal masses such as neuroblastoma, which can further be differentiated from WT through urine analysis for catecholamines and metaiodobenzylguanidine scintigraphy. This patient's diagnosis was made using an abdominal ultrasound and CT scan. Supportive tests included a full blood cell count to screen for tumor-associated anemia and thrombocytopenia, kidney function test for potential derangement in kidney function, liver function test for altered liver enzymes in liver metastasis, and clotting profile for

disrupted coagulation such as occurs in WT-acquired von Willebrand disease.¹¹

Currently, Kilton et al.'s diagnostic criteria is widely used to diagnose adult WT and includes: (a) a primary renal neoplasm; (b) primitive blastomatous spindle or round cell component; (c) formation of abortive or embryonal tubular or glomeruloid structures; (d) no areas of hypernephroma; (e) pictorial confirmation of histologic findings; and (f) age older than 15 years.^{5,12,13}

Due to the absence of clear guidelines in adults, treatment is adapted from the WT protocols for children. In developed countries, multidisciplinary team management, appropriate patient stratification using histological type to select chemotherapeutic agents, and research-driven care are core to treatment success.¹⁴ The two most commonly applied treatment regimens for WT are derived from the National Wilms Tumor Study Group/COG and SIOP, which involves surgery, chemotherapy, and irradiation.¹¹ In metastatic disease, usually involving lymph node, lung, and liver, escalated therapy and whole-lung radiation therapy is the treatment of choice. This patient, managed under resource constraints, had both disseminated disease to the para-aortic lymph node and liver at the time of presentation and also a wanted pregnancy. An MDT was constituted to formulate a plan of care in a high-risk pregnancy clinic setting. Patient-adapted and risk-modified treatment is a strategy of choice, where chemotherapy not fatally toxic to the fetus was initiated during the pregnancy and escalated immediately postpartum guided by the histological type. Concerns regarding the possible effect of chemotherapy on the offspring of such women include congenital anomalies, genetic diseases, low birth weight, and prematurity.¹⁵ However, apart from low birth weight, the neonate of this patient had a good outcome, highlighting the fact that with MDT care, the appropriate choice of life-saving chemotherapeutic agents, and fetal surveillance can promote good outcomes even in pregnant women managed in low-resource settings. Presently, regimens for chemotherapy used in WT protocols after the first trimester, such as cyclophosphamide, vincristine, doxorubicin, are considered relatively safe.¹⁶ Avilés and Neri reported that offspring of children exposed in utero to such chemotherapeutic agents on follow-up had no congenital or neurologic abnormalities, no reported malignancies, and normal educational performance.¹⁷ However, antenatal chemotherapeutic protocols must be implemented after multidisciplinary discussions and appropriate patient counseling prior to treatment initiation.¹⁶ Abdomino-pelvic irradiation on the other hand is contraindicated as it directly affects the growing fetus and hence is generally avoided antenatally, as was done in this case.

Barriers to care have been studied in childhood nephroblastoma, especially in low-resource settings with strategies for improved care clearly defined.^{18,19} Although this has not been studied in adult WT, it offers a starting basis to outline care modalities to improve outcomes. The major barriers were late presentation to a mainstream hospital for definitive care and poor compliance to treatment.¹⁸ In this presented case, there was a delay to seek definitive care as well as a delay in diagnosis at the initial care centers. Public education

to ensure earlier presentation, social support, improved supportive care, a locally adapted treatment guideline, and dedicated multidisciplinary management may be key to improve outcomes.¹⁸

Clinical psychologist care is also important in enhancing compliance to treatment. This case had psychological support throughout her care, ensuring compliance to therapy. One of the important questions that informed her choice of keeping the pregnancy was concerning her fertility after chemotherapy, for which she needed psychological support. Chemotherapy using alkylating agents and irradiation of the abdomen and pelvis potentially reduces primordial follicles with resultant temporary or permanent ovarian function loss.¹⁵ Symptoms of ovarian insufficiency may arise during treatment, shortly afterwards, or later on as premature menopause.¹⁵ There is higher risk with cyclophosphamide, intermediate risk with Adriamycin, and low risk with vincristine, all of which were used in the management of this case. Gonadal function status of premenopausal women who receive chemotherapy can be assessed at 6 and 12 months after chemotherapy using levels of AMH, FSH, LH, estradiol, and progesterone, with AMH said to be the most sensitive.^{20,21} Neonates exposed antenatally to gonadotoxic chemotherapy may be followed up in the minipuberty phase within 6 to 9 months of delivery by the pediatric endocrinologist using assessment of AMH, FSH, LH, and estradiol levels.²² A review of studies by Del et al., however, suggest that there are no long-term effects on child gonadal function after antenatal exposure to gonadotoxic chemotherapy.²³

Contraception is important to postpone pregnancy at least until 2 years after treatment to allow enough time to confirm remission and rule out secondary effects of chemotherapy that may complicate future pregnancy such as diabetes or hepatic, renal, or cardiac disease. An MDT during the prenatal period that includes an oncologist and a maternal fetal medicine specialist is essential to set the best time to get pregnant.¹⁵ Our patient chose postplacental intrauterine device insertion as contraception.

4 | CONCLUSION

In summary, we present a rare case of an adult patient diagnosed with disseminated WT peripartum. She was found to be pregnant soon after radical nephrectomy and before postsurgical chemotherapy could be commenced. She preferred to keep the pregnancy and was managed in a multidisciplinary high-risk obstetric renal clinic with antenatal and postpartum chemotherapy. Further research is needed to outline protocols for resource-adapted and risk-profiled therapy in adult pregnant patients with WT prior to delivery.

AUTHOR CONTRIBUTIONS

Perez Sepenu, Jerry Coleman, and Theodore K. Boafor: conception, drafting of the manuscript, MDT meetings, clinical management of patients, editing the manuscript, and approval of the final manuscript. Alim Swarray-Deen, Aba Scott, Mathew K. Kyei, and Winfred K. Baah: MDT meetings, clinical management of patients, editing of the manuscript, and approval of the final manuscript.

FUNDING INFORMATION

None.

CONFLICT OF INTEREST STATEMENT

The authors have declared that no competing interests exist.

DATA AVAILABILITY STATEMENT

Data sharing is not applicable to this article as no new data were created or analyzed in this study.

ORCID

Perez Sepenu  <https://orcid.org/0000-0002-1931-1664>

Theodore K. Boافر  <https://orcid.org/0000-0003-1742-4777>

REFERENCES

1. Brown JT, Harik LR, Barbee MS, et al. Multidisciplinary care of adult wilms' tumor during pregnancy: a case report and review of the literature. *Clin Genitourin Cancer*. 2020;18(1):e1-e4.
2. Codacci-Pisanelli G. Cancer in pregnancy: an association to make one shiver-highlights from "cancer in pregnancy: 15 years after", 10-11 October 2019, Milan, Italy. *Ecancermedalscience*. 2019;13(October):10-11.
3. McCormick A, Peterson E. Cancer in pregnancy. *Obstet Gynecol Clin North Am*. 2018;45(2):187-200.
4. Nsafu J, Vanderpuye V, Scott AA, et al. Experiences and challenges in the management of pregnancy-associated breast cancer at the Korle Bu teaching hospital: a review of four cases. *Ecancermedalscience*. 2020;14:1-7.
5. Bajaj S, Gandhi D, Shah J, Serhal M, Sharma S. Adult Wilms tumor: an unusual case report with dedicated literature review. *Clin Imaging*. 2022;83:138-143.
6. Kasenda S, Mategula D, Chiphangwi N, Gadama LA, Masamba LPL. High-risk adult Wilms' tumor in pregnancy: a case report. *Malawi Med J*. 2019;31(2):155-158.
7. Mitry E, Ciccolallo L, Coleman MP, Gatta G, Pritchard-Jones K. Incidence of and survival from Wilms' tumor in adults in Europe: data from the EURO CARE study. *Eur J Cancer*. 2006;42(14):2363-2368.
8. Doganis D, Katsimpris A, Panagopoulou P, et al. Maternal lifestyle characteristics and Wilms tumor risk in the offspring: a systematic review and meta-analysis. *Cancer Epidemiol*. 2020;67:101769.
9. Atanda AT, Anyanwu LJC, Atanda OJ, Mohammad AM, Abdullahi LB, Farinyaro AU. Wilms' tumor: determinants of prognosis in an African setting. *African J Paediatr Surg*. 2015;12(3):171-176.
10. Khan I, Basu S, Khan D, Choudhary A, Khan S. Wilms' tumor in an adult female complicating pregnancy: a case report. *J Clin Diagnostic Res*. 2018;12(6):PD05-PD06.
11. Theilen TM, Braun Y, Bochennek K, Rolle U, Fiegel HC, Friedmacher F. Multidisciplinary treatment strategies for Wilms tumor: recent advances, technical innovations and future directions. *Front Pediatr*. 2022;10(July):1-14.
12. Rodrigues FA, Ribeiro EC, Filho RM, Silva EA, Diaz FAF. Adult Wilms tumor during gestational period. *Urology*. 2009;73(4):929.e1-929.e2.
13. Kilton L, Matthews MJ, Cohen MH. Adult Wilms tumor: a report of prolonged survival and review of literature. *J Urol*. 1980;124(1):1-5.
14. Ekenze SO, Nwangwu EI, Ezomike UO, Orji EI, Okafor OO. Continuing barriers to care of Wilms tumor in a low-income country. *Pediatr Blood Cancer*. 2019;66:e27416.
15. Crnogorac S, Miranovic V. Pregnancy after malignant disease – challenges and possibilities. *J Perinat Med*. 2018;46(4):349-353.
16. Walker JP, Saltzman AF, Kessler ER, Cost NG. Adult Wilms tumor during pregnancy: case report and literature review. *Urology*. 2019;129:200-205.
17. Avilés A, Neri N. Hematological malignancies and pregnancy: a final report of 84 children who received chemotherapy in utero. *Clin Lymphoma*. 2001;2(3):173-177.
18. Ekenze SO, Okafor OC, Obasi AA, Okafor DC, Nnabugwu II. Wilms tumor in Africa: a systematic review of management challenges and outcome in two decades (2000-2019). *Pediatr Blood Cancer*. 2020;67(11):e28695.
19. Holmes DM, Matatiyo A, Mpsa A, et al. Outcomes of a resource-adapted Wilms tumor treatment protocol in Lilongwe, Malawi, 2016-2021: successes and enduring barriers to cure. *medRxiv*. 2022:2022-08.
20. Turan V, Oktay K. Sexual and fertility adverse effects associated with chemotherapy treatment in women. *Expert Opin Drug Saf*. 2014;13(6):775-783.
21. Lie Fong S, Lugtenburg PJ, Schipper I, et al. Anti-müllerian hormone as a marker of ovarian function in women after chemotherapy and radiotherapy for haematological malignancies. *Hum Reprod*. 2008;23(3):674-678.
22. Renault CH, Aksglaede L, Wojdemann D, Hansen AB, Jensen RB, Juul A. Minipuberty of human infancy – a window of opportunity to evaluate hypogonadism and differences of sex development? *Ann Pediatr Endocrinol Metab*. 2020;25(2):84-91.
23. Del Pup L, Peccatori F, Azim H, et al. Obstetrical, fetal and postnatal effects of gestational Antineoplastic chemotherapy: how to counsel cancer patients. *Int J Immunopathol Pharmacol*. 2012;25(2):33-46.

How to cite this article: Sepenu P, Swarray-Deen A, Scott A, et al. Disseminated adult Wilms tumor in pregnancy: Leveraging multidisciplinary care in a low-resource setting. *Int J Gynecol Obstet*. 2023;00:1-6. doi:[10.1002/ijgo.15157](https://doi.org/10.1002/ijgo.15157)