Radiology Case Reports 18 (2023) 1466–1470

Available online at www.sciencedirect.com

ScienceDirect

journal homepage: www.elsevier.com/locate/radcr

Case Report

Giant pericardial cyst, an unusual cause of right heart failure in an elderly patient with tuberculosis and HIV: A case report☆,☆☆

Juliana Labi, BSc, MBChB[a,*], *Erasung-Umar Ibrahim, MBChB, MWACS*[b], *Dorothea Akosua Anim, MBChB, MGCP*[a], *Lawrence Agyemang Sereboe, MBBS, FWACS, FGCS*[b], *Yaw Boateng Mensah, MBChB, DA(WACS), MPH, FWACS, FGCPS*[c]

[a] *Department of Radiology, Korle Bu Teaching Hospital, 1 Guggisberg Ave, Accra, Ghana*
[b] *National Cardiothoracic Centre, P.O. Box KB 846, Korle Bu, Accra, Ghana*
[c] *Department of Radiology, University of Ghana Medical School, College of Health Sciences, Korle Bu, Accra, Ghana*

ARTICLE INFO

Article history:
Received 9 December 2022
Revised 10 January 2023
Accepted 11 January 2023
Available online 1 February 2023

Keywords:
Acquired pericardial cyst
Computed tomography
Echocardiography
Percutaneous drainage

ABSTRACT

Pericardial cysts are rare mediastinal masses commonly asymptomatic and incidentally found on chest radiographs. Pericardial cysts may be acquired/inflammatory in origin and may be symptomatic. We present a case of 65-year-old male who presented with symptoms of right heart failure. Diagnosis of a giant pericardial cyst was made using imaging modalities such as chest X-ray, computed tomography scan, and echocardiography. Percutaneous cyst aspiration was done under echocardiography guidance. Radiologists and cardiothoracic surgeons need to understand the pathology of inflammatory/acquired pericardial cysts to include in their differential diagnosis of mediastinal masses.

© 2023 The Authors. Published by Elsevier Inc. on behalf of University of Washington. This is an open access article under the CC BY-NC-ND license (http://creativecommons.org/licenses/by-nc-nd/4.0/)

Introduction

Pericardial cysts are rare benign lesions found in the thoracic cavity, and occur in 1 in 100,000 persons [1]. Pericardial cysts are usually considered congenital in origin [2]. However, they may be acquired, in which case they are termed as inflammatory cysts [2]. Inflammatory cysts may be caused by rheumatic pericarditis, tuberculosis, trauma including cardiac surgery, and ruptured echinococcal cysts among others [3]. Pericardial cysts may also present as pseudocysts, encapsulated and loculated pericardial effusions. Pericardial cysts are frequently asymptomatic and usually an incidental finding on chest radiographs [4]. They can however be symptomatic depending on their size and location [5] and present with signs of compression and mass effect on nearby structures [2]. Typical symptoms include chest discomfort, dyspnea, cough, palpitations, cardiac arrhythmias, and lower respiratory tract

☆ Funding: No external funding secured for this manuscript.
☆☆ Competing Interests: None to declare.
* Corresponding author.
E-mail address: juliemills05@yahoo.com (J. Labi).
https://doi.org/10.1016/j.radcr.2023.01.048
1930-0433/© 2023 The Authors. Published by Elsevier Inc. on behalf of University of Washington. This is an open access article under the CC BY-NC-ND license (http://creativecommons.org/licenses/by-nc-nd/4.0/)

infections [4]. In this case report, we present a case of a giant pericardial cyst which presented with symptoms of right heart failure.

Case report

A 65-year-old man was referred with a past medical history of cardiac tamponade secondary to tuberculosis in 2018 which was successfully managed with pericardiocentesis and a 6-month course of antituberculous medication. Patient also had a history of HIV infection and was on antiretroviral medication at the time of evaluation.

Six months prior to presentation, he reported to his primary physician with shortness of breath and pedal edema. His JVP was raised 6 cm, cardiac apex in the fifth left intercostal space midclavicular line, heart sounds I and II were heard with a pericardial knock. A 2D echocardiography showed a pericardial effusion (localized) with slight compression of the right ventricle and evidence of septal bounce with exaggerated E/A ratio of 3.5.

At presentation, the patient's complaints were easy fatigability, dyspnea on exertion, and bilateral feet and leg swelling of 6 months' duration. A diagnosis of chronic constrictive pericarditis was made, and further investigations requested. A plain chest radiograph showed an enlarged cardiac silhouette with irregular margins, a soft tissue mass overlying the cardiac silhouette and blunting of the right costophrenic angle (Fig. 1). The left lung field and demonstrated bones were unremarkable. An impression of anterior mediastinal mass was made.

Echocardiography showed a large well-defined cystic lesion containing both fluid and organized fibrin which was compressing the right ventricle. The rest of the cardiac chambers had normal geometry with good global contractility and an ejection fraction of 76%, no thrombus or pericardial effusion seen.

A contrast-enhanced computed tomography scan requested to further characterize the mediastinal lesion showed a large thin-walled, well-defined (15.6APx14.9CCx20.0TR) cm homogenous cystic lesion with mean attenuation of 22 HU in the prevascular (anterior) and visceral (middle) spaces which was related anteriorly and inferiorly to the heart. The cystic lesion was seen to compress predominantly the right atrium and right ventricle and displaced the heart postero-superiorly. There were no solid components, associated calcifications, internal septations, or abnormal enhancement of the cystic lesion. The intrathoracic component of the inferior vena cava was dilated measuring 3.3 cm in diameter due to impaired venous return. There was a right sided pleural effusion with its largest depth measuring 1.7 cm (Fig. 2). A diagnosis of a giant pericardial cyst likely of an inflammatory/acquired cause on account of the previous history of tuberculous pericarditis was made.

A complementary ultrasound scan of the abdomen showed dilated inferior vena cava and hepatic veins, with the liver measuring 15.5 cm, also seen was moderate ascites (Fig. 3).

A decision to drain the cyst under echocardiography guidance was made by the attending cardiothoracic surgeons. The drainage procedure was performed under local anesthesia yielding approximately 1200 mL of a brown-colored nonodorous fluid with numerous tiny yellowish particulate matter (Fig. 4). Analysis of the drained fluid showed high levels of adenosine deaminase (138.4 IU/L-normal, 0-30) and a positive Gene Xpert result for *Mycobacterium tuberculosis* complex, indicating the patient had an active tuberculosis infection. A post-percutaneous drainage chest radiograph was done 3 days after the procedure (Fig. 5), and this showed no significant change in size of the pericardial cyst after.

A week after the drainage, the patient had partial cystectomy and drainage with intraoperative findings of straw-

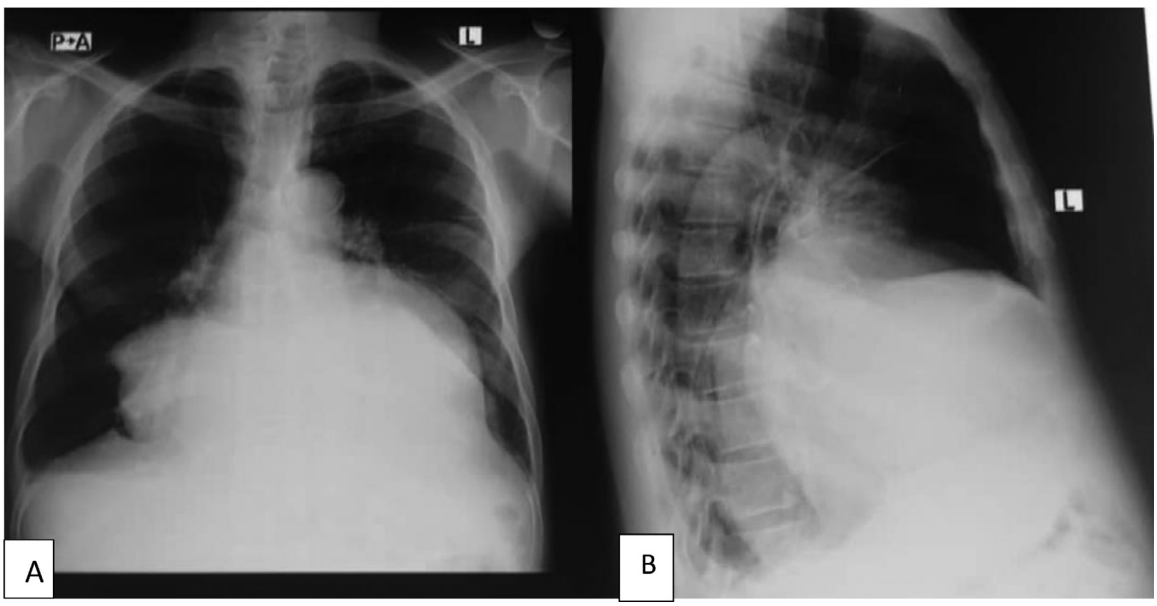

Fig. 1 – (A and B) Posterior-anterior (PA) and lateral chest radiograph showing a large anterior mediastinal lesion overlying the cardiac silhouette.

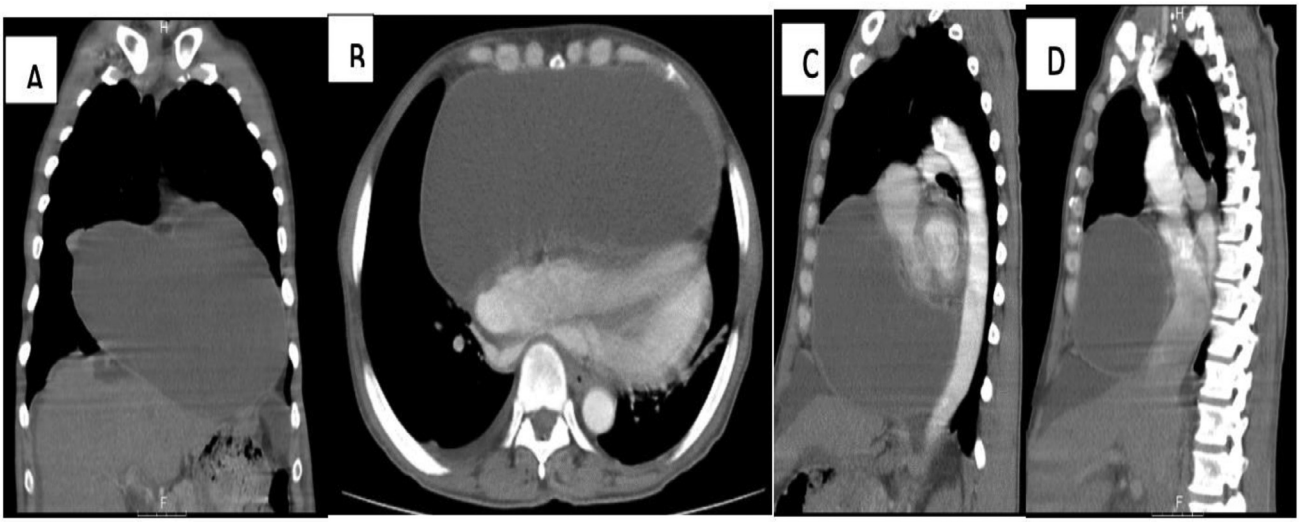

Fig. 2 – CECT scan of the chest (A) coronal, (B) axial, (C, D) sagittal, showing a large thin-walled nonenhancing homogenous cystic lesion in the anterior and middle mediastinum, right pleural effusion and a dilated inferior vena cava. CECT, contrast-enhanced computed tomography.

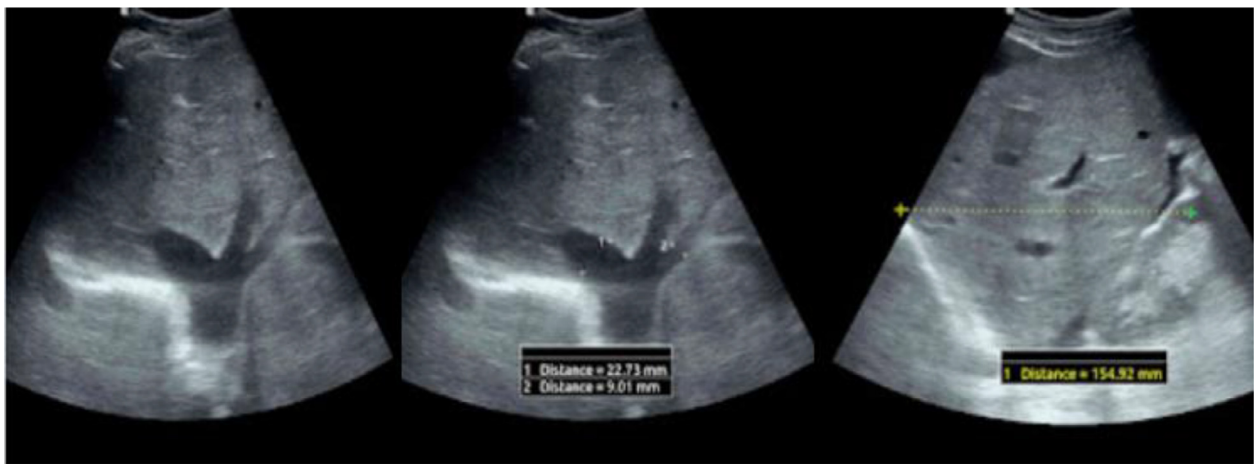

Fig. 3 – Transabdominal ultrasound scan showing dilated hepatic veins and inferior vena cava.

Fig. 4 – Percutaneous aspiration of pericardial cyst.

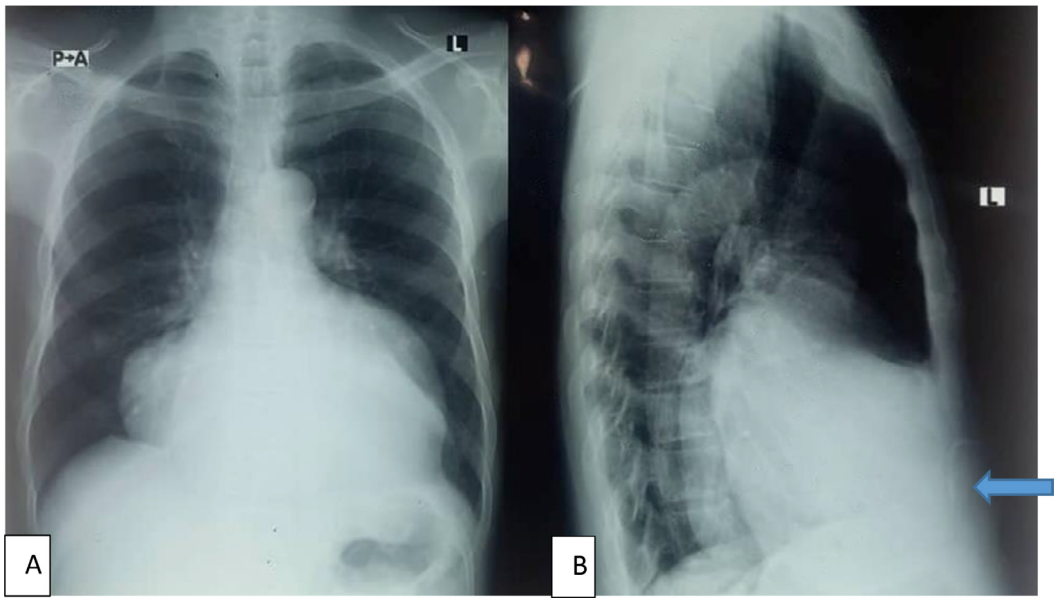

Fig. 5 – (A and B) Postpercutaneous drainage chest radiograph showing (PA) and lateral chest radiograph showing minimal change in size of pericardial cyst. Drainage tube seen in situ (⟸) on lateral radiograph.

colored effluent mixed with brown-colored fluid measuring 1200 mL and a thick-walled cyst in the anterior mediastinum compressing the heart. The pericardium was intact. Postoperatively, the patient developed a left pleural effusion, and a left chest drain was inserted which drained of 1850 mL of brown-colored fluid.

The surgical wound healed satisfactorily, and patient was discharged to recommence antituberculous medications and continue antiretroviral therapy

Discussion

Pericardial cysts are infrequent benign causes of mediastinal masses commonly asymptomatic [6]. When symptomatic it is due to complications such as compression, inflammation, hemorrhage, and rupture [7]. The index case under review presented with symptoms of right heart failure, which was as a result of the compressive effect of the cyst on the right side of the heart. It is however uncertain when the cyst began to develop or how quickly it enlarged. The patient's history of pericardiocentesis for a cardiac tamponade and antituberculosis treatment may have been the genesis of the development of the pericardial cyst.

Pericardial cysts ranging from 2 to 28 cm in size/diameter have been reported in literature [8]. In this case, the cyst measured approximately (15.6 × 14.9 × 20.0) cm. The lesion was located in the anterior (perivascular) and middle (visceral) mediastinum. Even though most reported cysts are located in the right costophrenic angle, they can also occur anywhere in the mediastinum corroborating what was found in this case [6].

Pericardial cysts on radiographs may mimic other conditions such as teratomas, bronchogenic cysts, lymphangioma, thymic cyst, etc. [2] making it difficult to diagnose. CT scans are excellent for differentiating pericardial cysts from other mediastinal masses [9]. The cysts appear as well-defined thin-walled, well-demarcated oval homogenous masses which fail to enhance postcontrast administration [4,10] as was the case of the pericardial cyst of the patient. As shown in this patient, echocardiography may diagnose a pericardial cyst as a non-communicating spherical entity attached to the pericardium [11]; however, additional imaging by CT or MRI is often needed to delineate the exact anatomic location, relation, and effect on surrounding structures.

Management of pericardial cysts is dependent on the symptomatology. Asymptomatic patients generally undergo conservative treatment depending on the location and size of cyst [5]. This is done with serial radiological imaging such as noncontrast low-dose CT scan and MRI; however, evidence regarding the appropriate interval between follow-ups is scarce [10]. In the case of symptomatic patients with large pericardial cysts video-assisted thoracoscopic surgery, sternotomy and resection of the cyst or thoracotomy and resection is the preferred approach depending on the location of the cyst. Alternatively, an ultrasound or echocardiography-guided percutaneous aspiration of the cyst may be considered in patients unfit for surgery [10,12], as was the case in the index patient. Guide lines from the Task Force on the diagnosis and management of pericardial disease of the European Society of Cardiology recommend percutaneous aspiration and ethanol sclerosis as the initial treatment of congenital and inflammatory cysts [3].

Conclusion

Pericardial cysts are commonly thought of as congenital in origin and typically located in the cardiophrenic angle. This case

report supports the notion of inflammatory pericardial cyst and the complications that may arise. Radiologist and cardiothoracic surgeons should consider this pathology in the differential diagnosis of cystic mediastinal masses if there is a history to suggest past inflammatory cause. Percutaneous cyst aspiration may be considered first-line management to alleviate symptoms and hopefully curative with ethanol sclerosis in lesions that are diagnosed very early.

Patient consent

Informed consent was obtained from the patient. The patient was also ensured of complete anonymity and confidentiality.

REFERENCES

[1] Patel J, Park C, Michaels J, Rosen S, Kort S. Pericardial cyst: case reports and a literature review. Echocardiography 2004;21(3):269–72.
[2] Meredith A, Zazai IK, Kyriakopoulos C. Pericardial cyst. StatPearls [Internet], Treasure Island (FL): StatPearls Publishing; 2022. Available at: http://www.ncbi.nlm.nih.gov/books/NBK562287/.
[3] Maisch B, Seferović PM, Ristić AD, Erbel R, Rienmüller R, Adler Y, et al. Guidelines on the diagnosis and management of pericardial diseases executive summary: the task force on the diagnosis and management of pericardial diseases of the european society of cardiology. Eur Heart J 2004;25(7):587–610.
[4] Elamin WF, Hannan K. Pericardial cyst: an unusual cause of pneumonia. Cases J 2008;1(1):26.
[5] Mwita JC, Chipeta P, Mutagaywa R, Rugwizangoga B, Ussiri E. Pericardial cyst with right ventricular compression. Pan Afr Med J 2012;12:60.
[6] Makar M, Makar G, Yousef K. Large pericardial cyst presenting as acute cough: a rare case report. Case Rep Cardiol 2018;2018:e4796903.
[7] Kar SK, Ganguly T, Dasgupta S, Mitra M, Bhattacharya R. Pericardial cyst: a review of historical perspective and current concept of diagnosis and management. Interv Cardiol J 2015;1:1.
[8] Akbayrak H, Yildirim S, Murat S, Mehmet O. A rare giant pericardial cyst mimicking a paracardiac mass. Cardiovasc J Afr 2016;27(4):e7–9.
[9] Noori MAM, Mohammadian M, Saeed H, Abboud R, Polyak A, Jawed Q, et al. Pericardial cyst, a rare incidental finding in an uncommon location: a case report. Cureus 2022;14(6). [Internet] Available at: https://www.cureus.com/articles/99691-pericardial-cyst-a-rare-incidental-finding-in-an-uncommon-location-a-case-report.
[10] Ershadi R, Vahedi M. Uncommon location of a giant pericardial cyst: a case report. Iran J Med Sci 2021;46(4):308–11.
[11] Michelotto E, Tarantino N, Ostuni V, Pedote P, Colonna P, Guglielmi R. An uncommon pericardial cyst in the central mediastinum: incremental diagnosis with contrast-enhanced three-dimensional transesophageal echocardiography. J Cardiovasc Echogr 2013;23(4):106–10.
[12] Qamar Y, Gulzar M, Qamar A, Sabry H, Minhas T. An incidental finding of a large pericardial cyst. Cureus 2022;14(4). [Internet] Available at: https://www.cureus.com/articles/92315-an-incidental-finding-of-a-large-pericardial-cyst.