ResearchGate

See discussions, stats, and author profiles for this publication at: https://www.researchgate.net/publication/262375148

Acute and Sub-Chronic Toxicity Studies of Aqueous Extract of Root Bark of Cassia Sieberiana D.C. in Rodents

Article *in* Journal of Applied Pharmaceutical Science · April 2014

DOI: 10.7324/JAPS.2014.40415

CITATIONS
10

READS
78

4 authors:

Kofi Donkor
Centre for Plant Medicine Research, Mampong-Akuapem
14 PUBLICATIONS **38** CITATIONS

SEE PROFILE

Laud Kenneth Okine
University of Ghana
64 PUBLICATIONS **427** CITATIONS

SEE PROFILE

Wonder Abotsi
Kwame Nkrumah University Of Science and Technology
39 PUBLICATIONS **323** CITATIONS

SEE PROFILE

Eric Woode
Kwame Nkrumah University Of Science and Technology
121 PUBLICATIONS **902** CITATIONS

SEE PROFILE

Some of the authors of this publication are also working on these related projects:

Project Ethnopharmacological Studies of Plants with Anagelsic Properties View project

Project Xylopia project View project

All content following this page was uploaded by Eric Woode on 17 May 2014.

The user has requested enhancement of the downloaded file.

Journal of Applied Pharmaceutical Science Vol. 4 (04), pp. 084-089, April, 2014
Available online at http://www.japsonline.com
DOI: 10.7324/JAPS.2014.40415
ISSN 2231-3354 BY-NC-SA

Acute and Sub-Chronic Toxicity Studies of Aqueous Extract of Root Bark of *Cassia Sieberiana* D.C. in Rodents

Kofi Donkor[1], Laud N.K. Okine[2], Wonder K. M. Abotsi[3], Eric Woode[3*]

[1]Department of Pharmacology and Toxicology, Centre for Scientific Research into Plant Medicine, Mampong-Akuapim, Ghana, [2]Department of Biochemistry, University of Ghana, Legon, Ghana, [3]Department of Pharmacology, Faculty of Pharmacy and Pharmaceutical Sciences, College of Health Sciences, KNUST, Kumasi, Ghana.

ARTICLE INFO

Article history:
Received on: 28/02/2014
Revised on: 02/04/2014
Accepted on: 22/04/2014
Available online: 28/04/2014

Key words:
urinalysis, micrograph, centrilobular necrosis, nephroprotective, biochemical

ABSTRACT

Acute and sub-chronic toxicity studies of the aqueous extract of the root bark of *C. sieberiana* (Caesalpiniaceae), a plant used locally in Ghana for the treatment of pain, was carried out in rodents. In the acute study, a single oral dose (5000 mg/kg) of the aqueous extract of *C. sieberiana* (NPK) was administered to six rats and six mice, and observed for 14 days for signs of acute toxicity. In the sub-chronic study, rats were administered with NPK (15-750 mg/kg) daily for three months. Urinalysis, haematological and biochemical analyses were carried out on urine, blood and serum samples collected at the end of the three-month treatment. Histological analyses of the liver, heart, kidney and lung tissues were also done. The results showed that administration of 5000 mg/kg of NPK to animals did not result in death. There were no significant differences ($p>0.05$) between control and test animals in the haematological assay. The albumin, alkaline phosphatase and total bilirubin were higher ($p<0.05$) in test animals compared to the controls. Liver micrographs showed centrilobular necrosis at the dose of 750 mg/kg. The findings, therefore, show that the oral toxicity of NPK in rodents is low (oral LD_{50} > 5000 mg/kg). However, the extract may have deleterious effects on the liver at high doses on prolonged administration.

INTRODUCTION

Cassia sieberiana DC. (Caesalpiniaceae), commonly called African laburnum is a perennial savannah legume shrub or tree, up to 20 m high. The leaves are spirally arranged, leaflets elliptical to ovate, shortly hairy. The fruit is a cylindrical pod (up to 90 cm) which contains ellipsoid, rusty to dark brown seeds (van der Maesen, 2007). The aqueous decoctions of the roots, stem bark and the fruit pulp have been used traditionally in North-eastern Nigeria for the treatment of inflammatory conditions, tiredness, jaundice and joint pains (Madusolomuo *et al.*, 1999). The extracts are used to treat fever, malaria, diuretics, diarrhoea, leprosy, bilhazia, stomach pains and as a dewormer (Tamboura *et al.*, 2005). Presently, at the Centre for scientific Research into Plant Medicine (CSRPM), Mampong-Akwapim, Ghana, the milled root bark of the plant is processed and used for the treatment of various pain conditions including pain associated with stomach ulcer and menstruation. Earlier works have shown that *C. sieberiana* extracts had antimicrobial, antifungal, anti-oxidant and anti-ulcerogenic activity (Silva *et al.*, 1997a; Silva *et al.*, 1997b; Asase *et al.*, 2008; Nartey *et al.*, 2012).

Ethanolic and aqueous root extracts of *C. sieberiana* also has analgesic, anti-inflammatory, antiparasitc, myorelaxant and antispasmodic activities (Duwiejua *et al.*, 2008; Sy *et al.*, 2009). The anti-nociceptive activity of the ethyl acetate extract of the root bark has been shown to be attributable to interactions with opioidergic, muscarinic cholinergic and adenosinergic systems (Donkor *et al.*, 2013).

The phytochemical studies of the plant indicated the presence of tannins, flavonoids, sterols, saponins, phenolics and anthroquinones (Duquenois *et al.*, 1968; Madusolomuo *et al.*, 1999; Donkor *et al.*, 2013). Obidah and his co-workers(Obidah *et al.*, 2009) reported that oral administration of aqueous extract of *C. sieberiana* stem bark to rats resulted in hepatotoxicity at lower dose levels of 20-60 mg/kg and nephrotoxicity at higher doses of 180 mg /kg. Earlier, Tamboura *et al.* (Tamboura *et al.*, 2005) found that the LD_{50} of the aqueous leaf extract in mice was 24.4 mg/kg.

** Corresponding Author*
Prof. Eric Woode, Department of Pharmacology Faculty of Pharmacy and Pharmaceutical SciencesCollege of Health Sciences Kwame Nkrumah University of Science and Technology Kumasi, Ghana,
Tel: +233 244 589793, E-mail: ewoode.pharm@knust.edu.gh

© 2014 Kofi Donkor et al. This is an open access article distributed under the terms of the Creative Commons Attribution License -NonCommercial-ShareAlike Unported License (http://creativecommons.org/licenses/by-nc-sa/3.0/).

There are other reports of toxicity of *C. Sieberiana* and other members of its genera in literature (Dhar *et al.*, 1968; Mugera, 1970; El Sayed *et al.*, 1983; Neuwinger, 1996). Though the root bark of the plant is widely used medicinally, little studies has been done on its toxicity. Only an acute single-dose toxicity study has been reported (Nartey *et al.*, 2012)-which recorded no sign of toxicity up to a dose level of 2000 mg/kg body weight *p.o.* There is, therefore, the need for a thorough safety assessment of the root bark of the plant. In this regard, we have examined, in the current study, the acute and sub-chronic toxicity of the aqueous extract of the root bark of *C. sieberiana* in rodents.

MATERIALS AND METHODS

Plant material

The root bark of *Cassia sieberiana* was collected from the CSRPM's arboretum (5°55'05.44"N; 0°07´58.95"W) at Mampong-Akwapim, Ghana. They were authenticated by Mr. Ofori Lartey of the Plant Development Department (PDD) of the CSRPM and a voucher specimen (CSRPM No. 300) kept in the Herbarium of the PDD of the CSRPM, Mampong-Akwapim, Ghana.

Reagents and Chemical

Test kits: aspartate aminotransferase (AST), alanine aminotransferase (ALT), alkaline phosphatase (ALP), gamma-glutamyl transferase (GGT), albumin (ALB), total and direct bilirubin, creatinine and urea were purchased from Cypress Diagnostics (Belgium). Urine test strips (UroColor™ 10) were obtained from Standard Diagnostics Inc. (kyonggi-do, Korea). All other chemicals were purchased in their purest form available from British Drug House (BDH) Ltd. (Poole, UK).

Preparation of Extract

A kilogram of milled air-dried root bark of the plant material was boiled and kept at a temperature of 80 °C for 3 hours. It was left to cool at room temperature and sieved through a fine mesh. The mixture was lyophilized to yield 301.52 g (30.15% w/w of raw plant material) and labelled NPK.

Animals

Female Sprague-Dawley rats (190-205 g) and Female C3H mice (26-30 g) were obtained from the Animal Unit of the Centre for Scientific Research into Plant Medicine (CSRPM), Mampong-Akuapem, in the Eastern Region of Ghana. The animals were housed in groups of six in stainless steel cages (34×47×18 cm^3) with soft wood shavings as bedding, fed with normal commercial pellet diet (GAFCO, Tema), given clean water *ad libitum* and maintained under laboratory conditions (temperature 24-28 °C, relative humidity 60-70 %, and 12 hour light-dark cycle). The research was conducted in accordance with the internationally accepted principles for laboratory animal use and care (NIH, No.85-23, revised 1985). Ethical clearance was obtained from the CSRPM's ethics committee.

Acute toxicity studies

A single oral dose of the extracts was administered at 5.0 g /kg body weight to six female rats and six female mice each with an oral gavage needle. Mortality and general behaviour of the animals were observed over a 48-hour period. Surviving animals were observed for a further period of 12 days for toxic symptoms of piloerection, as well as lachrymatory, locomotor and respiratory activities.

Sub-chronic toxicity studies

Four groups of six female rats each were kept in four separate metal cages. Group 1 was kept as control and received normal clean drinking water *ad libitum* for three months. Group 2, 3 and 4 were treated with 15, 150 and 750 mg/kg of NPK daily for three months. The animals in each group were weighed on day zero (baseline) and weekly thereafter. Blood samples of rats in each treatment group was obtained by tail bleeding, at baseline and termination of treatment, into Eppendorf tubes without anticoagulant, centrifuged (Denley BS 400, England) at 4000 ×*g* for 5 min and the serum obtained stored at -40 °C for biochemical analyses. Other blood samples were collected into separate tubes already coated with trisodium citrate (Westergreen E.S.R, UK) for haematological analysis.

Urinalysis

Urine samples of rats in each treatment group at baseline and termination of treatment were analysed for glucose, bilirubin, ketones, specific gravity, pH, proteins, urobilinogen, nitrate, blood and leukocytes using urine reagent strips (UroColor™ 10, Standard Diagnostic Inc., Korea).

Haematological analysis

Red blood cells (RBC), mean cell volume (MCV), haematocrit (HCT), mean corpuscular haemoglobin (MCH), mean corpuscular haemoglobin concentration (MCHC), red cell distribution width (RDW), white blood cells (WBC), haemoglobin (HGB), platelet counts (PLT), mean platelet volume (MPV), platelet distribution width (PDW) and lymphocytes (LYMPH) were determined with an automated haematology analyser (Sysmex K21, Tokyo, Japan).

Serum biochemical analyses

Serum aspartate aminotransferase (AST), alanine aminotransferase (ALT), alkaline phosphatase (ALP), γ-glutamyltransferase (GGT), albumin (ALB), total and direct bilirubin, creatinine and urea of samples were determined using protocols from Cypress diagnostic kits (Belgium) with a semi-automated blood chemistry analyser (Photometer 4040, Robert Riele G & Cole- 2000, Germany).

Histology

At termination of treatment, two rats from each group were sacrificed by cervical dislocation and the heart, lungs, liver, kidney and spleen were excised and weighed. All the organs

except the spleen were stored in 10 % neutral formalin and dehydrated with a progressively increasing concentration of ethanol. The tissues were cleared with chloroform and impregnated with paraffin wax. Sections, 5 µm thick were stained with haematoxylin and eosin (Khalaf *et al.*, 2010) and mounted on slides for light microscopic examinations.

Statistical analysis

Results were expressed as the mean value ± standard error of mean (SEM). Differences between control and experimental groups were determined by one-way analysis of variance (ANOVA), followed by Holm-Sidak's multiple comparisons test. GraphPad Prism for Windows version 6 (GraphPad Software, San Diego, CA, USA) was used for all statistical analyses and *P* values less than 0.05 were considered significant.

RESULTS

Acute toxicity studies

The administration of 5000 mg/kg to both rats and mice did not result in the death of any of the animals for the 14-day experimental period. Also, animals did not show signs of acute toxicity such as piloerection, lacrimation or changes in locomotion and respiration.

Sub-chronic toxicity studies

Body and organ weights

The percentage change in mean body weight with period of treatment, and organ/body weight ratio at termination of treatment in control and NPK-treated animals are shown in Fig.1 and Table 1, respectively. The results showed no significant difference (p>0.05) in body weight changes between NPK-treated and control animals with time. Similarly, there were no significant changes (p>0.05) in the organ weights, expressed as percentage of body weight, at termination between control and NPK-treated animals.

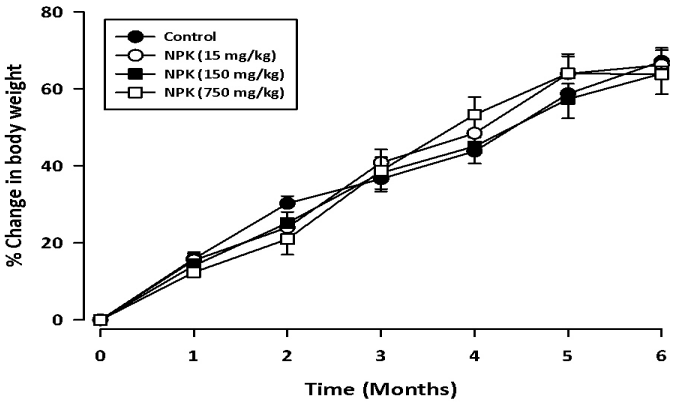

Fig. 1: Effect of oral administration of NPK on the body weight of rats in the sub-chronic toxicity test. Data are expressed as Mean ± S.E.M. (*N*=6). Treated groups were compared to controls using a two-way ANOVA (*treatment* × *time*) followed by Holm-Sidak's test.

Table. 1: Effect of NPK on organ/body weight ratio.

Organ	Organ /body weight ratio (%) Treatment group			
	Control	NPK 15 mg/kg	NPK 150 mg/kg	NPK 750 mg/kg
Liver	3.22 ± 0.03	3.59 ± 0.31	3.69 ± 0.01	3.21 ± 0.21
Lungs	0.56 ± 0.06	0.55 ± 0.11	0.57 ± 0.03	0.56 ± 0.09
Heart	0.38 ± 0.05	0.36 ± 0.02	0.36 ± 0.03	0.32 ± 0.02
Spleen	0.21 ± 0.01	0.20 ± 0.01	0.24 ± 0.00	0.23 ± 0.02
Kidneys	0.60 ± 0.02	0.58 ± 0.01	0.62 ± 0.01	0.60 ± 0.00

Values are Mean±SEM (n= 6).

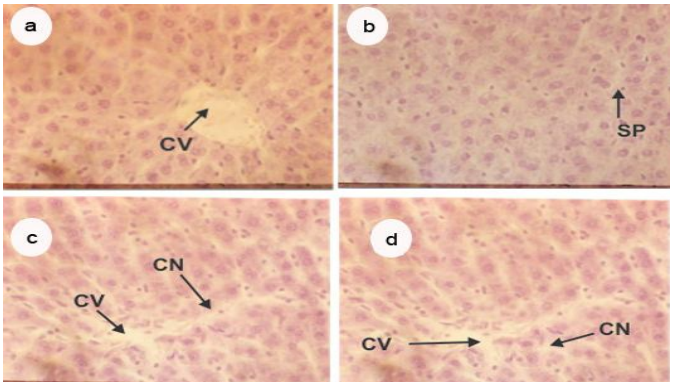

Fig. 2: Liver sections (H&E-stained, 132×) of control rats (a) and rats treated daily with NPK at doses of 15 mg/kg (b), 150 mg/kg (c) and 750 mg/kg (d) for three months in the sub-chronic toxicity test. Abbreviation: CV, central vein; CN, centrilobular necrosis; SP, interstitial space.

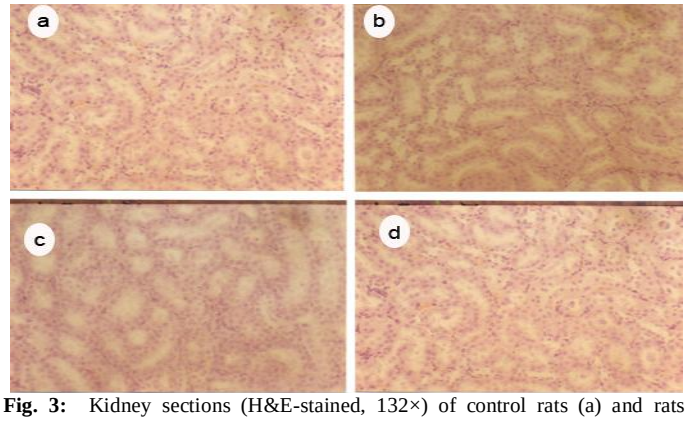

Fig. 3: Kidney sections (H&E-stained, 132×) of control rats (a) and rats treated daily with NPK at doses of 15 mg/kg (b), 150 mg/kg (c) and 750 mg/kg (d) for three months in the sub-chronic toxicity test.

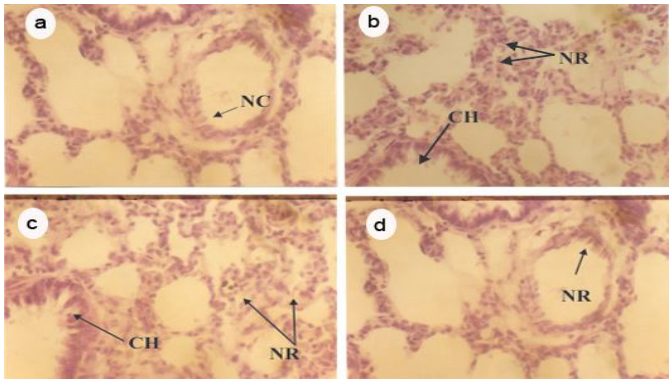

Fig. 4: Lung sections (H&E-stained 132×) of control rats (a) and rats treated daily with NPK at doses of 15 mg/kg (b), 150 mg/kg (c) and 750 mg/kg (d) for three months in the sub-chronic toxicity test. Abbreviation: CH, Clara cell hyperplasia; NC, normal Clara cell; NR, inflammatory response.

Table. 2: Effect of NPK on serum biochemical parameters.

Parameter	Treatment Group			
	Control	NPK		
		15 mg/kg	150 mg/kg	750 mg/kg
ALT (U/L)	32.20 ± 3.03	32.60 ± 2.66	36.52 ± 5.42	38.21 ± 2.49
AST (U/L)	117.42 ± 4.75	119.53 ± 3.90	118.00 ± 5.87	123 ± 5.59
ALP (U/L)	32.45 ± 1.60	28.23 ± 1.36	41.98 ± 3.38**	27.84 ± 0.62
GGT (U/L)	3.53 ± 0.77	3.13 ± 0.65	2.70 ± 0.37	2.80 ± 0.36
ALB (g/L)	44.75 ± 0.95	50.00 ± 2.97	49.00 ± 1.58	69.50 ± 4.79****
T. bil (µmol/L)	1.83 ± 0.25	3.33 ± 0.35**	2.90 ± 0.15*	2.63 ± 0.36
D. bil (µmol/L)	0.93 ± 0.29	0.63 ± 0.21	1.56 ± 0.13	0.53 ± 0.09
Creat (µmol/L)	66.07 ± 4.97	54.36 ± 2.79	55.64 ± 3.26	56.27 ± 2.10
Urea (mmol/L)	7.50 ± 0.84	5.68 ± 0.41	5.70 ± 0.27	5.85 ± 0.41

Values are Mean±SEM (n= 6). *p<0.05, **p<0.01, ****p<0.0001 compared to control. T. bil, total bilirubin ; D. bil, direct bilirubin ; Creat, creatinine.

Table. 3: Effect of NPK on urine parameters.

Parameter	Treatment Group			
	Control	NPK		
		15 mg/kg	150 mg/kg	750 mg/kg
Glucose (mg/dl)	-	-	-	-
Bilirubin (mg/dl)	-	-	-	-
Ketones (mg/dl)	1.00 ± 0.00	*t*	0.50±0.00	0.50±0.00
S.G.(g/ml)	1.025 ± 0.00	1.03 ± 0.00	1.03 ± 0.00	1.03 ±0.00
Blood (RBC/µl)	-	-	-	-
pH	6.50 ± 0.00	7.30 ± 0.06	7.00 ± 0.00	7.00 ± 0.00
Protein (g/l)	*t*	*t*	*t*	*t*
Nitrite	-	-	-	-
Leukocyte (WBC/µl)	-	-	-	-
Urobilinogen (mg/dl)	N	N	N	N

Results are means of N = 6. (–): Absent; (N): Normal; (*t*): Trace.

Table. 4: Effect of NPK on haematological parameters.

Parameter	Treatment Group			
	Control	NPK		
		15 mg/kg	150 mg/kg	750 mg/kg
RBC (x106 /µ l)	8.49 ± 0.27	8.71 ± 0.81	9.03 ± 0.16	8.87 ± 0.16
MCV (µ3)	59.32 ± 1.79	62.42 ± 1.43	62.53 ± 0.77	61.77 ± 0.51
HCT (%)	49.87 ± 2.72	51.60 ± 1.46	56.45 ± 1.10	54.77 ± 0.82
MCH (pg)	18.75 ± 0.56	18.35 ± 0.89	18.18 ± 0.20	18.08 ± 0.16
MCHC (g/dl)	31.92 ± 2.07	29.47 ± 0.75	29.12 ± 0.53	29.30 ± 0.17
RDW (%)	35.6 ± 0.86	38.3 ± 4.63	36.8 ± 1.48	34.6 ± 1.47
WBC(x103/µ l)	8.72 ± 0.73	7.26 ± 0.49	9.12 ± 0.74	10.15 ± 0.31
HGB (g/l)	15.96 ± 0.19	15.85 ± 0.20	16.05 ± 0.20	16.05 ± 0.21
PLT (x103/µ l)	581 ±116.17	289 ± 42.79	497.33 ±107.72	645 ± 36.77
MPV (µ3)	6.55 ± 0.18	6.90 ± 0.12	7.00 ± 0.16	6.78 ± 0.14
LYMPH (#)	6.82 ± 0.77	6.32 ± 0.25	7.75 ± 0.69	8.15 ± 0.36

Values are means ± S.E.M. of N = 6.

Serum biochemistry and urinalysis

The effects of sub-chronic administration of NPK to rats on selected serum biochemical and urine parameters at termination of treatment are shown in Tables 2 and 3. The results of serum biochemical indices indicate that NPK caused significant increases (p<0.05) in the levels of ALB, ALP and total bilirubin compared to the controls. Dipstick urinalysis data indicate that there were no significant differences (p>0.05) in the levels of urine parameters between NPK-treated and control animals except ketones where there was a significant reduction (p<0.01) in the levels between test and control animals.

Haematological studies

The effect of sub-chronic administration of NPK on certain haematological indices at termination of treatment is shown in (Table 4). The results show that there were no significant difference (p>0.05) in all parameters measured between control and NPK-treated animals.

Histology

The effects of NPK on the histopathology of the liver, kidney, lung and heart tissues at termination of treatment are shown in Figs. 3-6. Results showed that NPK did not affect the morphology of the kidney and heart tissues (Figs. 4a-d, 6a-d). However, lungs of 15 and 150 mg/kg NPK-treated animals showed slight inflammatory response in alveolar areas and Clara cell hyperplasia without the thickening of alveolar septa and bronchiolar epithelial wall (Figs. 5a-d). Similarly, there was centrilobular necrosis of the 750 mg/kg NPK-treated animals (Figs. 3a-d)

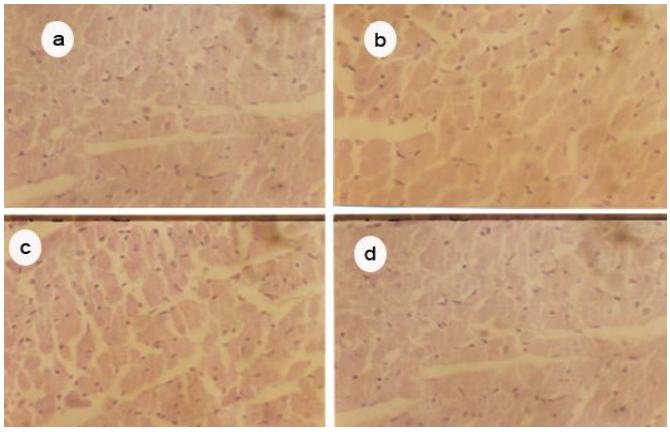

Fig. 5: Heart sections (H&E-stained 132×) of control rats (a) and rats treated daily with NPK at doses of 15 mg/kg (b), 150 mg/kg (c) and 750 mg/kg (d) for three months in the sub-chronic toxicity test.

DISCUSSION

In Ghana, the herbal medicine industry is becoming highly lucrative as a result of increased patronage of herbal preparations. Aside the government agency, Centre for Scientific Research into Plant Medicine, (CSRPM), Mampong-Akwapim, whose mandate is to carry out research and development of herbal medicine, there are numerous other private companies which are into the production and administration of herbal medicines. The CSRPM currently produces more than forty herbal preparations which it administers in its clinic including milled root bark of *Cassia sieberiana* (NPK). Despite the increased patronage of herbal preparations, information on their safety is very scanty. Thus we have evaluated comprehensively, the acute and sub-chronic toxicity of NPK in animals.

The limit dose of 5000 mg/kg did not result in mortality or any clinical sign of acute toxicity in both mice and rats in the short term (i.e., 48 h) and long term (i.e., 14 days) observatory period suggesting that the oral LD_{50} of the extract is more than 5000 mg/kg in both species. The limit test is used in situations where the investigator has information indicating that the test material is likely to be non-toxic or of low toxicity (OECD, 2001). In a previous study, the oral LD_{50} of root bark of *C. sieberiana* in

rats was estimated to be more than 2000 mg/kg (Nartey *et al.*, 2012). The result of the acute oral toxicity study, therefore, suggests that NPK at the limit dose tested is essentially non-toxic (scale of Hodge and Sterner(Hodge *et al.*, 1943)), and safe in aqueous oral formulation in rodents.

In the sub-chronic studies, the extract did not appear to affect the normal growth of test animals as evidenced by comparable weight gain by both control and test animals over the three month treatment period (fig. 1). Furthermore, there was no significant change when excised heart, kidney, liver, lung and spleen were expressed relative to body weight in control and test animals (Table. 1). Relative weight is more indicative of toxicity than absolute weight (Demma *et al.*, 2007).

Liver and kidney play a key role in metabolic processes. Whiles the liver detoxifies substances that are harmful to the body, the kidney helps in maintenance of homeostasis by reabsorbing vital substances and excretion of waste products (Greaves, 2007). The biochemical analysis (Table 2) showed a significant elevation in serum total bilirubin, ALB (at 750 mg/kg) and ALP (at 150 mg/kg) in NPK-treated animals compared to controls. In the assessment of liver damage by drugs or any other hepatotoxin, the determination of enzyme levels such as ALT and AST is largely used (Dobbs *et al.*, 2003). Serum ALP level on the other hand, is related to the function of hepatic cell and increased level is due to increased synthesis of the enzyme, in the presence of increasing biliary pressure (Moss *et al.*, 1974). Albumin is synthesised in the liver—decreased levels are implicated in malfunction in hepatic synthetic ability whiles excessive levels are usually due to dehydration (Pritchett, 2009). Thus the elevated levels of ALP and total bilirubin in NPK-treated animals may be indicative of liver dysfunction as a result of prolonged administration of the extract. Urea is the first acute renal marker upon renal injury and creatinine is the most trustable renal marker and increases only when the majority of renal function is lost (Borges *et al.*, 2005). The present result reveals a reduction, though not statistically significant, in the levels of urea and creatinine at all the dose levels compared to controls. Nephrotoxicants such as cadmium increase serum levels of urea and creatinine in the rat whiles nephroprotective agents such as honey reduces serum urea and creatinine levels (Abdel-Moneim *et al.*, 2007). Results of the urinalysis revealed no significant differences between test and control animals in all the parameters measured (Table 3).

Blood cells are produced in the bone marrow. Known haemotoxicants such as paracetamol cause reduction in RBCs leading to anaemia (Mullick *et al.*, 1973) and some bioactive phytochemicals affect HCT levels (Patrick-Iwuanyanwu *et al.*, 2007). In the haematological studies (Table 4), there was no significant difference between test and control animals. Hence, the extract may not have deleterious effects on bone marrow function. Histological examination of the extract-treated samples of liver stained with haematoxylene and eosin revealed slight centrilobular necrosis at the highest dose of 750 mg/kg. Known hepatotoxins such as paracetamol cause hepatocyte degeneration, centrilobular necrosis and haemorrhages (Iweala *et al.*, 2011). Thus the extract may have a deleterious effect on the liver at high dose of 750 mg/kg on prolonged administration as evidenced by centrilobular necrosis and elevation in the serum ALP levels. The kidney and heart did not show noticeable morphological changes in all the NPK-treated animals. However, there was some toxicological insult to the lungs as evidenced by slight inflammatory response and Clara cell hyperplasia in the NPK-treated animals.

In conclusion, oral toxicity of the aqueous extract of the root bark of *C. sieberiana* in rodents is low (oral LD_{50} > 5000 mg/kg). However, the extract may have deleterious effects on the liver at high doses on prolonged administration. These findings support its safe ethnomedicinal use at moderate doses.

ACKNOWLEDGEMENT

The authors are grateful to the staff of the Animal House Unit of the CSRPM, Mampong-Akwapim for their technical support during the study.

REFERENCES

Abdel-Moneim WM, Ghafeer HH. The Potential Protective Effect Of Natural Honey Against Cadmium-Induced Hepatotoxicity And Nephrotoxicity. Mansoura J. Forensic Med. Clin. Toxicol., 2007; 15:75-97.

Asase A, Kokubun T, Grayer RJ, Kite G, Simmonds MS, Oteng-Yeboah AA, Odamtten GT. Chemical constituents and antimicrobial activity of medicinal plants from Ghana: *Cassia sieberiana, Haematostaphis barteri*, *Mitragyna inermis* and *Pseudocedrela kotschyi*. Phytotherapy research, 2008; 22:1013-1016.

Borges LP, Borges VC, Moro AV, Nogueira CW, Rocha JB, Zeni G. Protective effect of diphenyl diselenide on acute liver damage induced by 2-nitropropane in rats. Toxicology, 2005; 210:1-8.

Demma J, Gebre-Mariam T, Asres K, Ergetie W, Engidawork E. Toxicological study on *Glinus lotoides*: a traditionally used taenicidal herb in Ethiopia. Journal of ethnopharmacology, 2007; 111:451-457.

Dhar ML, Dhar MM, Dhawan BN, Mehrotra BN, Ray C. Screening of Indian plants for biological activity: I. Indian journal of experimental biology, 1968; 6:232-247.

Dobbs NA, Twelves CJ, Gregory W, Cruickshanka C, Richards MA, Rubens RD. Epirubicin in patients with liver dysfunction: development and evaluation of a novel dose modification scheme. European Journal of Cancer, 2003; 39:580-586.

Donkor K, Okine LNK, Abotsi WKM, Woode E. Anti-inflammatory and Anti-nociceptive Effects of Ethyl Acetate Fraction of Root Bark of *Cassia sieberiana* D. C. in Murine Models. Pharmacologia, 2013; 4:301-310.

Duquenois P, Anton R. [Contribution to the chemical study of the leaves of *Cassia sieberiana* D.C]. Planta medica, 1968; 16:184-190.

Duwiejua M, Panyin AB, Weremfo A, Woode E, Ansah C. Antinociceptive activity of the ethanolic extract of the root bark of *Cassia sieberiana* (Fam. Caesalpinaceae). Journal of Pharmacy & Bioresources, 2008; 4:49-58.

El Sayed NY, Abdelbari EM, Mahmoud OM, Adam SE. The toxicity of *Cassia senna* to Nubian goats. The Veterinary quarterly, 1983; 5:80-85.

Greaves P. 2007. Histopathology of preclinical toxicity studies: Interpretation and Relevance in Drug Safety Evaluation. New York: Academic Press.

Hodge HC, Sterner JH. Determination of substance acute toxicity by LD_{50}. American Industrial Hygiene Association, 1943; 10:93.

Iweala EEJ, Obichi IC, Omotosho OE. Biochemical and Histological Responses of Hepatotoxic Rats Fed *Musa paradisiaca L.* Supplemented Diet. International Journal of Pharmacology, 2011; 7.

Khalaf MAM, Ghaleb SS, Abbas MF. Protective Effect Of Carnosine On Amikacin-Induced Nephrotoxicity In Rats. Mansoura J. Forensic Med. Clin. Toxicol. , 2010; 18:81-95.

Madusolomuo MA, Nadro MS, Wurocheke AU. Antihepatotoxic properties of *Cassia sieberiana* in acetaminophen–treated rats. Nig. J. Biochem. Mol. Biol, 1999; 14:21-25.

Moss DW, Butterworth PJ. 1974. Enzymology and medicine. London: Pitman Medical

Mugera GM. Toxic and medicinal plants of East Africa. II. Bulletin of epizootic diseases of Africa. Bulletin des epizooties en Afrique, 1970; 18:389-403.

Mullick FG, Delage C, Irey NS. Sickle cell crisis associated with drugs. Archives of environmental health, 1973; 26:221-222.

Nartey ET, Ofosuhene M, Kudzi W, Agbale CM. Antioxidant and gastric cytoprotective prostaglandins properties of *Cassia sieberiana* roots bark extract as an anti-ulcerogenic agent. BMC Complementary and Alternative Medicine, 2012; 12:65.

Neuwinger HD. 1996. African ethnobotany: poisons and drugs: chemistry, pharmacology, toxicology. Weinheim:Chapman & Hall.

Obidah W, Sa'ad UA, Wurochekke AU. Toxic effects of aqueous stem bark extract of *Cassia sieberiana* on some biochemical parameters in rats. Afr. J. Biochem. Res, 2009; 3:229-231.

OECD. 2001. OECD Guideline for Testing of Chemicals. Acute Oral Toxicity-Fixed Dose Procedure. OECD/OEDC.

Patrick-Iwuanyanwu KC, Wegwu MO, Ayalogu EO. Prevention of CCl4-induced liver damage by ginger, garlic and vitamin E. Pakistan Journal of Biological Sciences, 2007; 10:617-621.

Pritchett S. Abnormal LFTs. InnovAiT: The RCGP Journal for Associates in Training, 2009; 2:140-147.

Silva O, Barbosa S, Diniz A, Valdeira ML, Gomes E. Plant extracts antiviral activity against Herpes simplex virus type 1 and African swine fever virus. Pharmaceutical Biology, 1997a; 35:12-16.

Silva O, Ferreira E, Vaz Pato M, Gomes E. Guinea-Bissau's plants: in vitro susceptibility studies on Neisseria gonorrhoeae. Pharmaceutical Biology, 1997b; 35:323-328.

Sy GY, Fall AD, Diatta W, Gueye M, Badji K, Bassène E*l*. Analgesic and anti-inflammatory activity of aqueous root extract of *Cassia sieberiana DC* (Caesalpiniaceae). Afr. J. Pharm. Pharmacol, 2009; 3:651-653.

Tamboura HH, Bayala B, Lompo M, Guissou IP, Sawadogo L. Ecological Distribution, Morphological Characteristics And Acute Toxicity Of Aqueous Extracts Of *Holarrhena Floribunda* (G. DON) Durand & Schinz, *Leptadenia hastata* (PERS.) Decne and *Cassia sieberiana* (DC) Used By Veterinary Healers In Burkina Faso. African Journal of Traditional, Complementary and Alternative Medicines, 2005; 2:13-24.

van der Maesen LJG.2007. Cassia sieberiana DC. Record from PROTA4U. Schmelzer, G.H. & Gurib-Fakim, A. (Editors). PROTA (Plant Resources of Tropical Africa / Ressources végétales de l'Afrique tropicale), Wageningen, Netherlands.

How to cite this article:

Kofi Donkor, Laud N.K. Okine, Wonder K. M. Abotsi, Eric Woode. Acute and Sub-Chronic Toxicity Studies of Aqueous Extract of Root Bark of *Cassia Sieberiana* D.C. in Rodents. J App Pharm Sci, 2014; 4 (04): 084-089.

View publication stats