

Available online at www.sciencedirect.com

ScienceDirect

journal homepage: www.elsevier.com/locate/radcr

Case Report

A rare case of intussusception in a 6-month-old baby [☆]

Emmanuel Fiagbedzi^{a,b,*}, Joseph Arkorful^b, Emmanuel Appiah^b, Nicholas Otumi^b, Ishmael Ofori^b, Philip Nii Gorleku^b

^aUniversity of Ghana, Department of Medical Physics, Accra, Ghana

^bUniversity of Cape Coast, College of Health and Allied Sciences, Department of Medical Imaging Technology and Sonography, Cape Coast, Ghana

ARTICLE INFO

Article history:

Received 10 March 2024

Revised 17 June 2024

Accepted 30 June 2024

Available online 1 August 2024

Keywords:

Intussusception

Treatment

Case

Diagnosis

ABSTRACT

This case report discusses the clinical presentation, imaging findings, and successful management of a rare case of intussusception in a 6-month-old female infant referred to a regional hospital in Ghana. The patient presented with vomiting, lethargy, fever, and currant jelly stool. Differential diagnoses considered included Merkel diverticulum, volvulus, lymphadenopathy, and hypertrophic pyloric stenosis. Ultrasound imaging revealed a concentric lesion with characteristic signs of intussusception. Ileo-caeco coli intussusception was confirmed as the diagnosis. Surgical management was used for this patient. The postsurgery phase was without any complications. The patient recovered well and was discharged with a switch to oral medications. Infant intussusception is still a disease with a low morbidity rate.

© 2024 The Authors. Published by Elsevier Inc. on behalf of University of Washington.

This is an open access article under the CC BY-NC-ND license

(<http://creativecommons.org/licenses/by-nc-nd/4.0/>)

Introduction

The occurrence of intussusception in a female newborn at the age of 6 months is a significant medical issue characterised by the inward folding of a portion of the intestine, resulting in a blockage inside the gut [1]. This illness poses a significant risk to a child's life and need immediate medical intervention [2]. Intussusception in babies manifests via several symptoms, such as abrupt and vociferous weeping triggered by abdominal discomfort, the act of bringing the knees towards the chest, the presence of blood and mucus in the stool

resembling currant jelly, episodes of vomiting, the presence of a mass in the abdomen, weakness, and diarrhoea [3–5]. In children, risk factors include cystic fibrosis, infections and intestinal polyps, while in adults, factors like bowel adhesions, endometriosis and intestinal tumors are relevant [2].

Diagnosing intussusception in newborns under 3 months old might be difficult due to the presence of vague symptoms [1,6]. Lethargy and pallor, particularly when there are no stomach symptoms, might serve as significant indicators. Emesis is a persistent manifestation of intussusception, irrespective of its nonbilious nature. The presence of per rectum bleeding and a palpable lump in the epigastrium might aid in the

[☆] Competing Interests: The authors declare that they have no known competing financial interests or personal relationships that could have appeared to influence the work reported in this paper.

* Corresponding author.

E-mail address: emmanuel2g4@gmail.com (E. Fiagbedzi).

<https://doi.org/10.1016/j.radcr.2024.06.080>

1930-0433/© 2024 The Authors. Published by Elsevier Inc. on behalf of University of Washington. This is an open access article under the CC BY-NC-ND license (<http://creativecommons.org/licenses/by-nc-nd/4.0/>)

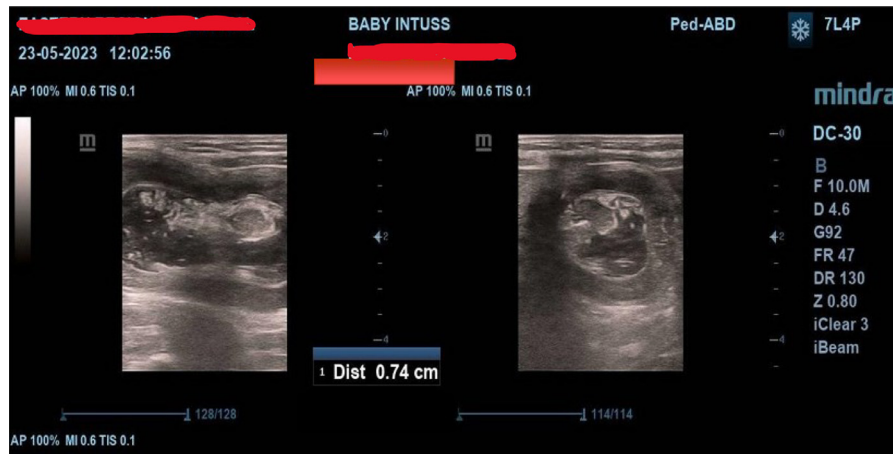


Fig. 1 – A concentric lesion with rings of alternating hypoechoic and hyperechoic layers; a classical sonographic appearance of intussusception.

process of diagnosing the condition [7]. Prompt identification is crucial for effective therapy [8].

Medical imaging plays a crucial role in diagnosing intussusception; ultrasound is preferred in children, while computed tomography (CT) scans are more common in adults [9,10]. Treatment typically involves enemas for children and may require surgical intervention if enemas are unsuccessful. Surgical removal of section of the bowel is often necessary in adults [11].

Clinical presentation

A 6 months old lethargic febrile female infant who was referred to a regional hospital with a history of a palpable soft, firm and tender mass at the umbilical and left iliac fossa region with vomiting and passage of currant jelly stool for 2 days on the 23 May, 2023. Routine laboratory investigations depicted an increase in lymphocytes, total cell count and hemoglobin was 14.0 g/dL. Upon further review by the Physician she was sent for an ultrasound scan.

Differential diagnosis

In light of the clinical presentation, differential diagnoses such as merkel's diverticulum, volvulus, lymphadenopathy, infantile hypertrophic stenosis were considered [12]. To confirm the diagnosis and rule out these conditions, further investigations, including ultrasound examination and intra operative findings were perused. The differential diagnosis for a rare congenital defect known as merkel diverticulum is diagnosed when a segment of the small intestine protrudes through a weak area in the abdominal wall [6,10]. It may manifest with symptoms similar to intussusception, such as vomiting, bloody faeces, and abdominal pain. However, it possesses sonographic characteristics like a short bowel connection to a blind-ending peristaltic loop [3,13].

Investigations and imaging findings

The patient underwent an ultrasound examination. An ultrasound with the following specifications was used; Machine type: Mindray DC 30, Exam preset: abdominal, Transducer: both linear and curvilinear transducers of frequency ranges 7.5-15 and 2.5-5.0MHz. The findings of the examination were obtained from greyscale (Bmode). Color Doppler was activated to assess the vascularity of bowels. TGC, overall gain, focus, PRF and depth were all adjusted to suit the examination. Patient remain in supine position throughout the examination.

The findings revealed concentric lesion with rings of alternating hypoechoic and hyperechoic layers (Fig. 1), giving a target sign on transverse view and pseudo kidney sign on sagittal view, indicative of bowel seen at the left iliac fossa. This lesion shows minimal flow on color doppler (Fig. 2) interrogation and a minimal peritoneal fluid seen (Fig. 3). The liver is of average size measuring 6.9 cm with homogeneous parenchymal echotexture, smooth surface, and sharp edge. No intra or extrahepatic dilatation. The pancreas is of normal sonographic appearance. The spleen is of average size measuring 4.5 with homogeneous parenchymal and echotexture. No focal mass seen. The gall bladder wall is of uniform thickness with no intraluminal sludge or calculus seen. Both kidneys are of average size measuring RT = 5.2 × 2.5 cm and LT = 6.1 × 2.8 cm with good corticomedullary and sinus differentiation. No focal mass, calculus or hydronephrosis seen bilaterally. No intraabdominal mass or intraperitoneal fluid collection seen. Abdominal organs displayed normal sonographic appearances (Fig. 4).

Treatment

Due to the delayed detection of intussusception and the presence of symptoms indicating possible bowel ischemia, the medical recommendation was to proceed with an urgent surgical intervention as seen in Fig. 5 (laparotomy with man-

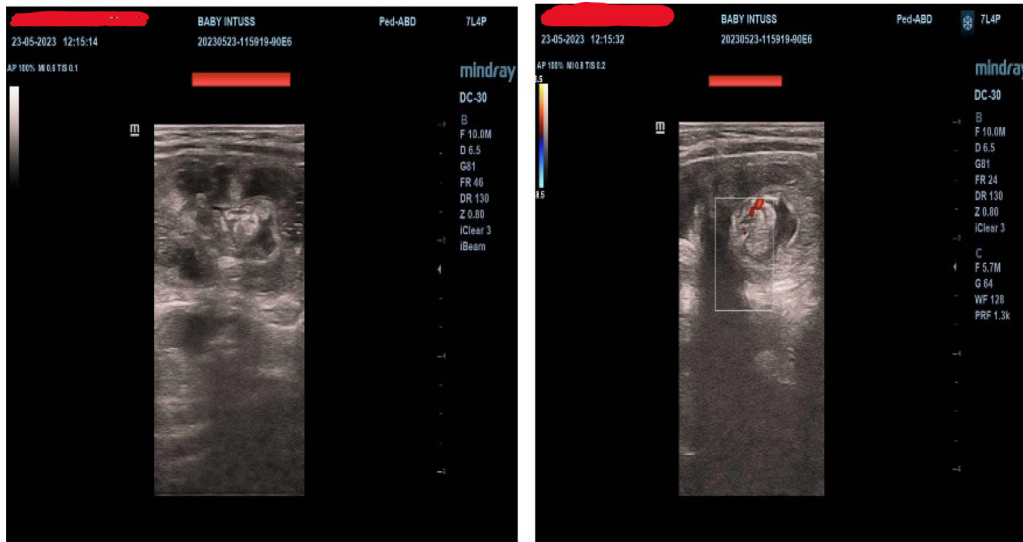


Fig. 2 – A concentric lesion with rings of alternating hypoechoic and hyperechoic layers with minimal flow on color doppler interrogation.

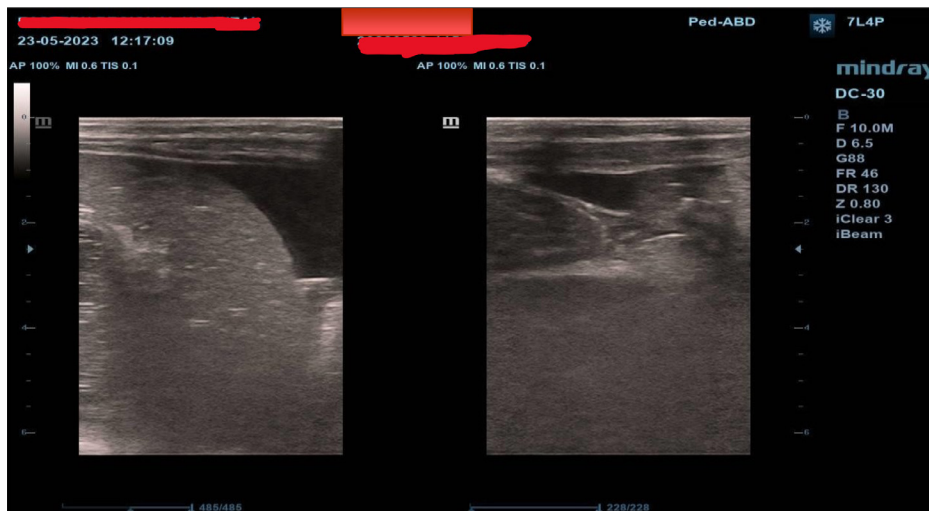


Fig. 3 – Minimal peritoneal fluid (ascites).

ual reduction) instead of attempting a nonoperative pneumatic reduction. Patient mother was informed and counselled. Patient was then prepared and was taken to the theatre for a laparotomy with manual reduction of bowel on May 23, 2023 after a consent form was issued by the medical officer and signed by the patient's mother. Intra operative findings was ileo-caeco-colic intussusception with viable bowel.

Outcome and follow-up

The surgical procedure was successful. To support the baby's recovery, a nasogastric (NG) tube was placed to facilitate en-

teral feeding and medication administration while allowing the digestive system time to heal. Subsequently, the patient was transferred to the recovery ward for close monitoring and observation. The patient's condition remained stable, and was transferred to the pediatric surgical ward on May 24, 2023, at 8:15 PM.

The patient was later reviewed at the pediatric surgical ward on May 25, 2023. During the assessment, the patient was observed lying comfortably in her cot with the nasogastric (NG) tube in place, showing no signs of respiratory distress or pain. The wound dressing was found to be clean and dry. The patient's vital signs were stable, with a satisfactory oxygen saturation level (SPO₂) of 100%. After the review, medications were switched to the oral route. Following the successful recovery and continued improvement,

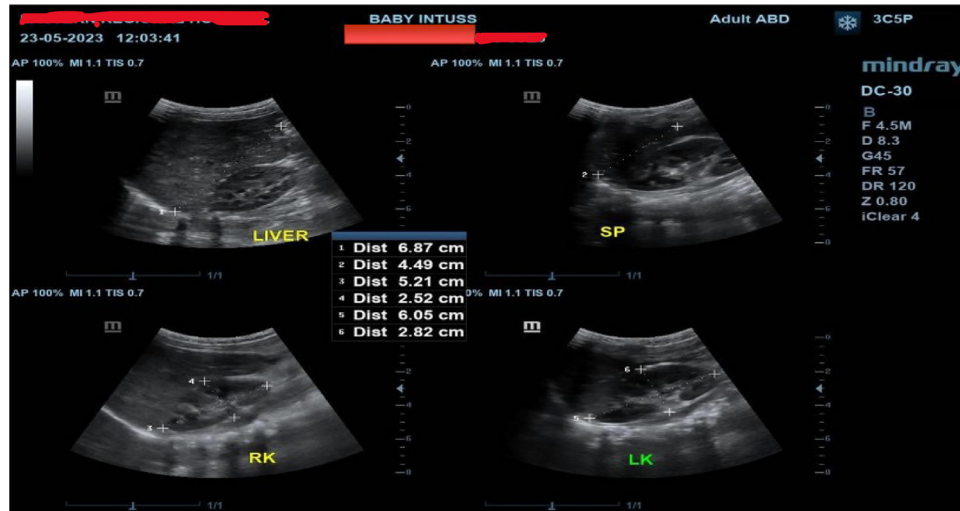


Fig. 4 – A ultrasound image of normal liver, right and left kidney and spleen.

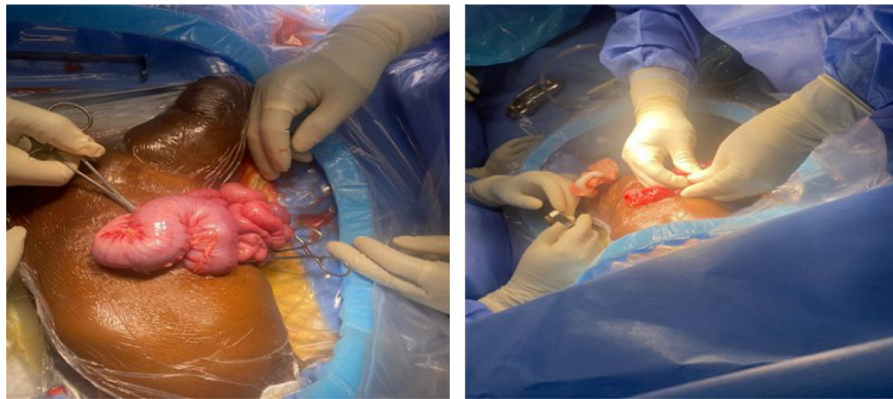


Fig. 5 – Intraoperative image of the rare case of intussusception.

the patient was discharged from the hospital on May 26, 2023.

Discussion

Approximately 1-4 out of every 2000 children may have intussusception within their first 3 years of life, with a median age ranging from 4 to 9 months. This condition is prevalent globally. About twice as much affects the male sex. This is a pediatric emergency and ranks as the second most frequent cause of gastrointestinal obstruction in young children and infants [14,15].

In Intussusception, the upstream intestinal segment is always imprisoned within the downstream segment by a turning mechanism that resembles a finger. Only 10% of children's intussusception have a pathological lead point, meaning that the majority of cases are idiopathic. Anatomical or viral factors frequently playing a role. In the case of our patient, no pathological lead point was seen (idiopathic). Idiopathic intus-

susception takes place at the location of lymphoid hyperplasia, the ileo-colic junction. Rotavirus, herpes virus, and adenovirus all point to a viral origin. Tumors, appendicitis, digestive abnormalities, and a few general disorders are other local causes [16].

Ultrasound is the preferred diagnostic modality for intussusception [10]. Although CT scans are not typically utilized to confirm a positive diagnosis of intussusception, they are nevertheless the preferred imaging modality when certain abnormalities in the abdomen are present [2].

Treatment should be made available to the patient after diagnosis; children who exhibit symptoms of shock, peritonitis, or perforation should have surgery right away. For most intussusceptions, noninvasive radiological technique is required; the most common are pneumatic enema, US guided hydrostatic enema, fluoroscopy guided hydrostatic enema, and pneumatic enema [17].

Nonsurgical radiological technique under sonographic or fluoroscopic guidance is presently the treatment of choice for intussusception in infants and children [18]. Surgical treatment is often used as the main approach in developing coun-

tries, mostly because of the delayed manifestation and accurate diagnosis [15,19]. In developed countries, the mortality rate associated with managing intussusception in infants and children is less than 1% while in developing countries, this rate is significantly higher [20].

The therapeutic approach for pediatric patients is determined on the specific form of intussusception. The most prevalent kind in children, ileocolic intussusception, can be reduced in 85%–90% of cases using an ultrasound-guided, fluoroscopic, pneumatic, or hydrostatic enema. Because there is a higher chance of recurrence in the first 24 hours, close supervision is needed [21]. Though rare in children, small bowel intussusception may typically be carefully monitored and will resolve on its own without the need for surgery. However, it has been observed that persistent small bowel intussusception is mostly accompanied with intestinal necrosis, necessitating surgical intervention. Surgical intervention is recommended in cases when enema reduction or careful surveillance proves to be ineffective, irrespective of the kind of intussusception. Delays in diagnosis and complications from intussusception have contributed to a decline in mortality over time [18].

Conclusion

Intussusception in babies is a surgical emergency that needs early diagnosis and treatment in order to prevent morbidity. This is common within the age range of 3 months to 3 years old. It is possible to diagnose the illness based on clinical indicators. A favourable diagnosis may be made by ultrasonography, and imaging plays a significant part in this process. Noninvasive radiological treatment remains the primary therapeutic choice; nevertheless, surgical intervention becomes necessary if these treatments prove ineffective. Although the morbidity and death rates associated with intussusceptions are still very low, this might be high in under-resourced settings.

Patient consent

We wish to state that patient consent was seek prior to publication of this case.

REFERENCES

- [1] Yehouenou Tessi RT, El Haddad S, Oze KR, Mohamed Traore WY, Dinga Ekadza JA, Allali N, et al. A child's acute intestinal intussusception and literature review. *Glob Pediatr Heal* 2021;8:0–4. doi:10.1177/2333794x211059110.
- [2] Attoun MA, Albalawi SMD, Ayoub A, Alnasser AK, Alkaram EH, Khubrani FA, et al. The management of intussusception: a systematic review. *Cureus* 2023;15:1–9. doi:10.7759/cureus.49481.
- [3] Das MK, Arora NK, Gupta B, Sharan A, Kameswari K, Padmalatha P, et al. Intussusception in children aged under two years in India: retrospective surveillance at nineteen tertiary care hospitals. *Vaccine* 2020;38:6849–57. doi:10.1016/j.vaccine.2020.04.059.
- [4] Fotso Kamdem A, Vidal C, Pazart L, Leroux F, Pugin A, Savet C, et al. A case-control study of risk factors for intussusception among infants in eastern France after the introduction of the rotavirus vaccine. *Vaccine* 2019;37:4587–93. doi:10.1016/j.vaccine.2019.02.053.
- [5] Zurynski Y, McIntyre P, Booy R, Elliott EJ. Paediatric active enhanced disease surveillance: a new surveillance system for Australia. *J Paediatr Child Health* 2013;49:588–94. doi:10.1111/jpc.12282.
- [6] Marsicovetere P, Ivatury SJ, White B HS. Intestinal intussusception: etiology, diagnosis, and treatment. *Clin Colon Rectal Surg* 2017;30:003–4.
- [7] Bines JE, Ivanoff B, Justice F, Mulholland K. Clinical case definition for the diagnosis of acute intussusception. *J Pediatr Gastroenterol Nutr* 2004;39:511–18. doi:10.1002/j.1536-4801.2004.tb00900.x.
- [8] Jenke AC, Klaaen-Mielke R, Zilbauer M, Heining U, Trampisch H, Wirth S. Intussusception: incidence and treatment - insights from the nationwide German surveillance. *J Pediatr Gastroenterol Nutr* 2011;52:446–51. doi:10.1097/MPG.0b013e31820e1bec.
- [9] Munden MM, Bruzzi JF, Coley BD, Munden RF. Sonography of pediatric small-bowel intussusception: differentiating surgical from nonsurgical cases. *Am J Roentgenol* 2007;188:275–9. doi:10.2214/AJR.05.2049.
- [10] Lin-Martore M, Kornblith AE, Kohn MA, Gottlieb M. Diagnostic accuracy of point-of-care ultrasound for intussusception in children presenting to the emergency department: a systematic review and meta-analysis. *West J Emerg Med* 2020;21:1008–16. doi:10.5811/westjem.2020.4.46241.
- [11] Ghrilharey RK. Surgical management of intussusception in children: a retrospective review of 212 cases. *Ann Natl Acad Med Sci* 2021;57:226–31. doi:10.1055/s-0041-1739034.
- [12] Yan J, Shen Q, Peng C, Pang W, Chen Y. Colocolic intussusception in children: a case series and review of the literature. *Front Surg* 2022;9:873624. doi:10.3389/fsurg.2022.873624.
- [13] Ajao AE, Kumolalo FO, Olulana DI, Ogunloyin OO, Lawal TA. Childhood intussusception: a multicenter study in a middle-income country. *South African J Surg* 2020;58:138–42. doi:10.17159/2078-5151/2020/V58N3A2986.
- [14] Glover-Addy H, Ansong D, Enweronu-Laryea C, Tate JE, Amponsa-Achiano K, Sarkodie B, et al. Epidemiology of intussusception in infants less than one year of age in Ghana. *Pan Afr Med J* 2021;39(8):2012–16. doi:10.11604/pamj.supp.2021.39.1.25445.
- [15] Tesfaye DD, Adem BM, Ketema I, Mehadi A, Eshetu B, Teshager T, et al. Clinical profile and treatment outcome of acute intussusception among children in eastern Ethiopia: a seven years retrospective study. *Front Pediatr* 2022;10:1–9. doi:10.3389/fped.2022.968072.
- [16] Lioubashevsky N, Hiller N, Rozovsky K, Segev L, Simanovsky N. Ileocolic versus small-bowel intussusception in children: can US enable reliable differentiation? *Radiology* 2013;269:266–71. doi:10.1148/radiol.13122639.
- [17] Plut D, Phillips GS, Johnston PR, Lee EY. Practical imaging strategies for intussusception in children. *Am J Roentgenol* 2020;215:1449–63. doi:10.2214/AJR.19.22445.
- [18] Yadav A, Regmi PR, Koirala B. The double target sign as ultrasonographic finding in a case of double intussusception: a case report ☆. *Radiol Case Reports* 2024;19:1990–3. doi:10.1016/j.radcr.2024.02.002.
- [19] Toussaint TW, Wandaogo A, Yaméogo W IC, Ouédraogo I, Ouédraogo SMF, Zampou O, et al. Acute intestinal intussusception among children under five years of age

- admitted in an Ouagadougou hospital, Burkina Faso, 2008-2013: epidemiological, clinical and therapeutic aspects. *Pan Afr Med J* 2021;39:5. doi:[10.11604/pamj.supp.2021.39.1.25270](https://doi.org/10.11604/pamj.supp.2021.39.1.25270).
- [20] Joel E, Richter JHR. Risk factors associated with increased mortality from intussusception in African infants. *Physiol Behav* 2017;176:139–48. doi:[10.1097/MPG.0000000000002487](https://doi.org/10.1097/MPG.0000000000002487). [Correspondence.](#)
- [21] Jo S, Lim IS, Chae SA, Yun SW, Lee NM, Kim SY, et al. Characteristics of intussusception among children in Korea: a nationwide epidemiological study. *BMC Pediatr* 2019;19:1–7. doi:[10.1186/s12887-019-1592-6](https://doi.org/10.1186/s12887-019-1592-6).