

See discussions, stats, and author profiles for this publication at: <https://www.researchgate.net/publication/256076542>

# Multicentric Castleman's Disease in a Ghanaian Adult

Article in *Ghana medical journal* · June 2013

Source: PubMed

---

CITATION

1

---

READS

21

4 authors, including:



**Y A Dei-Adomakoh**

University of Ghana Accra

22 PUBLICATIONS 24 CITATIONS

[SEE PROFILE](#)



**Ivy Ekem**

University of Cape Coast

32 PUBLICATIONS 168 CITATIONS

[SEE PROFILE](#)

Some of the authors of this publication are also working on these related projects:



SCD and haplotypes [View project](#)



Levels of Soluble Endothelium Adhesion Molecules and Complications among Sickle Cell Disease Patients in Ghana [View project](#)

## MULTICENTRIC CASTLEMAN'S DISEASE IN A GHANAIAN ADULT

Y. A. DEI-ADOMAKOH<sup>1</sup>, C. SEGBEFIA<sup>2</sup>, I. EKEM<sup>1</sup> and A. TAYLOR<sup>3</sup>

<sup>1</sup>Department of Haematology, University of Ghana Medical School, P. O. Box 4236, Accra, Ghana

<sup>2</sup>Department of Child Health, University of Ghana Medical School, Accra P. O. Box 4236, Ghana

<sup>3</sup>Department of Pathology, Korle Bu Teaching Hospital, Accra, Ghana

*Corresponding Author: Dr Yvonne A. Dei-Adomakoh*

*Email: deiadom@yahoo.com*

*Conflict of interest: None declared*

### SUMMARY

Castleman's disease is a rare cause of lymphoid hyperplasia that may result in localized symptoms or an aggressive, multisystem disorder that can mimic other diseases like lymphoma or tuberculosis. We describe a case of a 55-year-old Ghanaian male who was successfully diagnosed and managed for multicentric Castleman's disease with combination chemotherapy.

**Keywords:** multicentric Castleman's disease, Plasma cell, lymphadenopathy, chemotherapy, Rituximab

### INTRODUCTION

Castleman's disease, first described in 1954, is a rare disorder characterized by hyperplasia of lymphoid tissue.<sup>1</sup> Histopathologically, three sub-types are recognized: hyaline vascular (HV) variant, plasma cell (PC) variant and the mixed variant.<sup>2</sup>

Clinical presentation is varied, ranging from unicentric or localized lymph node involvement to a severe, multicentric, systemic disorder associated with constitutional signs and symptoms such as fever, night sweats, easy fatigability and anaemia.<sup>3,4</sup> With localized disease, surgical resection of the affected lymph node is usually curative. However, multicentric Castleman's disease (MCD) often requires aggressive systemic therapy.<sup>2,4</sup>

We present a patient with MCD who is in remission following treatment with multiagent chemotherapy and Rituximab (anti-CD-20 monoclonal antibody). To the best of our knowledge, this is the first report of Castleman's disease with marked systemic symptoms in Ghana.

### CASE REPORT

A 55-year-old Ghanaian male was referred to the Haematology clinic at Korle Bu Teaching Hospital, Accra for investigation of a suspected lymphoma. He presented with a 9 month history of fever, weight loss and productive cough (no haemoptysis).

On examination, he was pale and had palpable, firm, non-tender, right axillary lymph nodes; the largest measuring 2 x 2 cm. Abdominal examination demonstrated an enlarged liver (7cm below the right costal margin) and a palpable splenic tip. Respiratory and cardiovascular systems were normal.

Laboratory examination revealed normocytic, normochromic anaemia (haemoglobin 9.6g/dl) but otherwise normal blood counts (Table 1). Erythrocyte sedimentation rate was elevated (51mm/hr). Liver enzymes, serum creatinine and lactate dehydrogenase levels were normal. A bone marrow aspirate revealed elevated marrow lymphocytes comprising 30% of nucleated cells, which appeared non-malignant morphologically. Mantoux test, HIV, Hepatitis B and C viral screening were negative. Human herpes virus 8 (HHV8) testing was negative.

**Table 1** Summary of full blood count and ESR results

Index	Before chemotherapy	After chemotherapy	Reference Range
Hb (g/dl)	8.9	13.4g/dl	13.5- 18.0
MCV (fl )	81	85.0fl	80.0-96.0
MCH (pg)	29.1	28.8pg	26.0 - 32.0
WBC (x 10 <sup>9</sup> /L)	3.6	4.1 x 10 <sup>9</sup> /L	4.0 - 11.0
Platelets (x 10 <sup>9</sup> /L)	141	196 X 10 <sup>9</sup> /L	150 - 400
Reticulocyte count (%)	0.4		0.5-2.5
ESR (mm/hr)	51		0- 14

ESR = erythrocyte sedimentation rate

Computed tomography (CT) scan of the chest and abdomen were done to assess extent of disease and revealed cardiomegaly, mild bilateral pleural effusions, mediastinal lymphadenopathy and hepatosplenomegaly.

**Table 2** Summary of immunohistochemistry of lymph node biopsy

MARKERS	FINDINGS
CD13	Stained scattered plasma cells
Kappa	Stained scattered plasma cells. No light chain clonality demonstrated
Lambda	Stained scattered plasma cells. No light chain clonality demonstrated
CD3	Stained scattered T-cells in the interfollicular zones
CD20	Stained B-cells in the germinal centers and mantle zones.
Bcl-6	Stained few lymphoid cells
CD23	Stained germinal centers.
Bcl -2	Stained B-cells in the germinal centers and mantle zones
Bcl -1	(Cyclin D1): Stained no lymphoid cells
CD21	Stained germinal centers
IgD	Stained no lymphoid cells

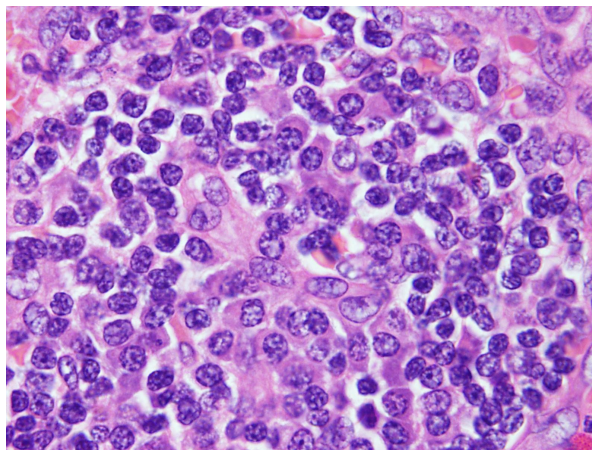
The immunohistochemistry report was similar to reactive lymphoid hyperplasia showing normal CD 20, 23, 21 and Bcl-2 staining of germinal centers. Staining of CD 138 demonstrated the presence of plasma cells and staining of both kappa and lambda light chains showed that the disease is polyclonal.

An axillary lymph node biopsy was performed and histology showed partially effaced architecture with follicles of varying sizes, expansion of the paracortex and concentric arrangement of lymphocytes around venules and plasma cells in the inter-follicular spaces. There was no evidence of a malignant lymphoma.

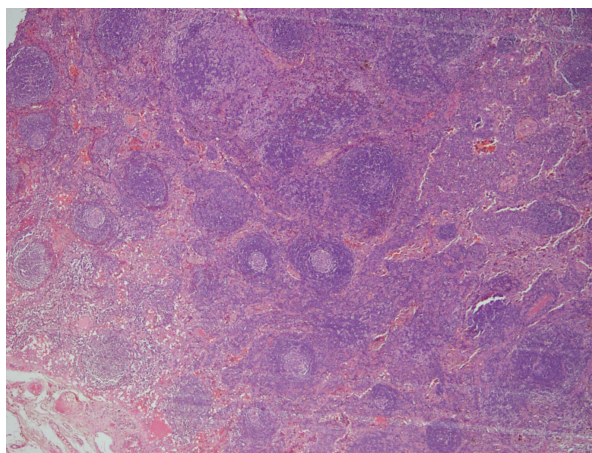
A diagnosis of Castleman's disease (PC variant) was made based on the histopathologic findings in Figures 1 and 2 and immunohistochemical test results (Table 2). The patient was started on combination chemotherapy comprising cyclophosphamide, vincristine, prednisolone, as well as rituximab, given at three weekly intervals. In total, he received six cycles of therapy.

With the commencement of chemotherapy, there was rapid improvement in his clinical symptoms and resolution of peripheral lymphadenopathy and hepatosplenomegaly.

A repeat chest x-ray after 6 cycles showed normal cardiac size and lung fields. Repeat blood counts were normal. Liver and renal function also remained normal. The patient is very well 12 months off therapy.



**Figure 1** Section showing a reactive lymph node with few plasma cells in the interfollicular zone (Magnification x 100)



**Figure 2** Section of lymph node showing partially effaced architecture with follicles of varying size scattered throughout the node. (Magnification x 4)

## DISCUSSION

The aetiology of Castleman's remains unclear although viral agents such as HHV-8 and HIV have been associated with the disease.<sup>5,6</sup> MCD has also been described in association with Kaposi sarcoma, autoimmune disorders and the POEMS (**P**eripheral polyneuropathy, **O**rganomegaly, **E**ndocrinopathy, **M**onoclonal gammopathy (M-Protein) and **S**kin signs) syndrome.<sup>2,6-8</sup>

Castleman's disease can be found throughout the body at both nodal and extranodal sites. The mediastinum and neck remain the most common sites for unicentric disease.<sup>9</sup> While Castleman's disease can occur at any age, most cases of localized disease occur in adolescents or young adults.

However, MCD commonly presents at an older age, usually in the fourth or fifth decade, as was the case in our patient.<sup>3,10</sup> No significant sex predilection has been found, regardless of the histologic type.<sup>2,9</sup>

The clinical manifestations of Castleman's disease are highly dependent on the histopathology of the lesion. The HV variant is usually associated with unicentric Castleman's disease while PC and mixed variants occur more commonly in MCD.<sup>2,11</sup>

Patients with MCD present with non-specific symptoms such as fever, weight loss and night sweats that may mimic malignant lymphoma, tuberculosis or HIV/AIDS. They may also present with organ failure.<sup>3</sup> Recent studies show that such systemic manifestations may be due to intra-lesional cytokine dysregulation involving interleukin 1 (IL-1), tumor necrosis factor alpha (TNF- $\alpha$ ), and interleukin 6 (IL-6).<sup>12</sup> Beck et al<sup>13</sup> showed that the generation of IL-6 in the germinal centers of hyperplastic lymph nodes and subsequent complex interactions with IL-1 and TNF- $\alpha$  may be the key elements responsible for the systemic manifestations of Castleman's disease.

Other clinical signs include peripheral lymphadenopathy and hepatosplenomegaly which were present in our patient. Features of POEMS syndrome may be present. Isolated case reports also recount such atypical features as peripheral neuropathy, myasthenia gravis, recurrent pleural effusion, amyloidosis, growth retardation, and nephrotic syndrome.<sup>14,15</sup>

Laboratory features are also non-specific and include high erythrocyte sedimentation rate (ESR), anaemia and hypoalbuminaemia. Anaemia may be due to the chronic nature of the disease. Lymph node biopsies and histological evaluation are essential for diagnosis of Castleman's disease and help exclude malignancy as well as other causes of hyperplasia.<sup>6</sup>

While unicentric Castleman's disease can be cured by surgical excision of the affected lymph nodes (or local radiotherapy for unresectable sites)<sup>4</sup>, MCD usually requires systemic therapy. Treatment options include corticosteroids, antiviral agents, anti-CD20 antibodies (Rituximab), anti-interleukin-6 receptor antibodies and chemotherapy<sup>5</sup>. Splenectomy may also result in improvement of symptoms.<sup>17</sup>

The use of highly active antiretroviral therapy (HAART) alone in HIV-associated MCD has resulted in complete remission in some patients.<sup>18</sup> Prompt therapy must be instituted to avoid potentially fatal complications from organ failure and infections. Complete response has been defined as the complete

disappearance of all measurable and evaluable disease.<sup>6</sup> Relapses may occur and high dose chemotherapy and autologous stem cell transplantation has been used with success.<sup>2,19</sup> There are no randomized clinical trials evaluating any of these treatment strategies.

## CONCLUSION

MCD should be considered in the differential diagnoses of patients presenting with peripheral lymphadenopathy and non-specific systemic symptoms. Early diagnosis is imperative given its progressive clinical course and increased risk for development of lymphoma. Empiric treatment options include steroids, chemotherapy and newer biologically targeted therapies like monoclonal antibodies.

## REFERENCES

1. Castleman B, Towne VW. Case records of the Massachusetts General Hospital: Case No. 40231. *N Engl J Med* 1954;250:1001-1005.
2. Dispenzieri A, Gertz MA. Treatment of Castleman's disease. *Curr Treat Options Oncol*. 2005;6:255-266.
3. Waterston A, Bower M. Fifty years of multicentric Castleman's disease. *Acta Oncol*. 2004;43:698-704.
4. de Vries IA, van Acht MM, Demeyere TB, et al. Neoadjuvant radiotherapy of primary irresectable unicentric Castleman's disease: a case report and review of the literature. *Radiat Oncol*. 2010;5:7.
5. Sunil M, Reid E, Lechowicz MJ. Update on HHV-8-associated malignancies. *Curr Infect Dis Rep*. 2010;12:147-154.
6. van Rhee F, Stone K, Szmania S et al. Castleman disease in the 21st century: an update on diagnosis, assessment, and therapy. *Clin Adv Hematol Oncol*. 2010;8:486-498.
7. Ruwan KP, Parakramawansa C, Wijeweera I et al. A case of POEMS syndrome with mixed hyaline vascular and plasma cell type Castleman's disease. *Ceylon Med J*. 2009;54:68-69.
8. Bruno C, Fleck JD, Cavaghan MK. Pituitary macroadenoma in a patient with POEMS syndrome in conjunction with Castleman disease: first report of a case and review of related literature. *Endocr Pract*. 2010;16:97-101.
9. Ye B, Gao SG, Li W et al. A retrospective study of unicentric and multicentric Castleman's disease: a report of 52 patients. *Med Oncol*. 2010;27:1171-1178.
10. Barrie JR, English JC, Müller N. Castleman's disease of the lung: radiographic, high-resolution CT, and pathologic findings. *Am J Roentgenol*. 1996;166:1055-1056.

11. Patel U, Forte V, Taylor G et al. Castleman's disease as a rare cause of a neck mass in a child. *J Otolaryngol.* 1998;27:171-173.
12. Browne WD, Lewis JJ, Filippa DA et al. The management of unicentric and multicentric Castleman's disease: A report of 16 cases and a review of the literature. *Cancer* 1999; 85: 706-17.
13. Beck JT, Hsu S, Wijdenes J, et al. Alleviation of systemic manifestations of Castleman's disease by monoclonal anti-interleukin-6 antibody. *N Engl J Med* 1994;330:602.
14. Emad A. Prolonged fever as an unusual manifestation of the hyaline vascular type of Castleman's disease in the chest: report and review of the literature. *Ann Hematol.* 1997;75:161-164.
15. Tazi I, Rachid M, Qessar A et al. A rare association of Castleman's disease and nephrotic syndrome. *Saudi J Kidney Dis Transpl.* 2011;22:116-119.
16. Summerfield GP, Taylor W, Bellingham AJ, et al: Hyaline-vascular variant of angiofollicular lymph node hyperplasia with systemic manifestations and response to corticosteroids. *J Clin Pathol* 1983; 36:1005-1011.
17. Bos MM, van den Berg LM, van Leeuwen AW et al. Splenectomy-induced long-term remission in a patient with multicentric Castleman's disease. *Neth J Med.* 2009;67:351-354.
18. Lee SM, Edwards SG, Chilton DN et al. Highly active antiretroviral therapy alone may be an effective treatment for HIV-associated multicentric Castleman's disease *Haematologica* 2010 ;95(11):1979-1981.
19. Mylona EE, Baraboutis IG, Lekakis LJ et al. Multicentric Castleman's disease in HIV infection: a systematic review of the literature. *AIDS Rev.* 2008;10:25-35. ☼