

See discussions, stats, and author profiles for this publication at: <https://www.researchgate.net/publication/310465667>

# In-vitro scavenging activity and acute toxicity study of methanol leaves extract and fractions of *Lophira lanceolata* Tiegh. Ex Keay(Ochnaceae) in rats

Article in *International Journal of Phytomedicine* · November 2016

DOI: 10.5138/09750185.1855

CITATION

1

READS

95

8 authors, including:



**Oussou N'guessan Jean-Baptiste**

Université Nangui Abrogoua

10 PUBLICATIONS 4 CITATIONS

[SEE PROFILE](#)



**Isaac Asiedu-Gyekye**

University of Ghana

52 PUBLICATIONS 142 CITATIONS

[SEE PROFILE](#)



**Benoit Banga N'Guessan**

University of Ghana

78 PUBLICATIONS 922 CITATIONS

[SEE PROFILE](#)



**Patrick Amoateng**

University of Ghana

56 PUBLICATIONS 232 CITATIONS

[SEE PROFILE](#)

Some of the authors of this publication are also working on these related projects:



Screening of Ghanaian Medicinal Plants for Antipsychotic Properties [View project](#)



In vitro and in vivo effect of nanoparticulate formulations of antimicrobials on intracellular *Leishmaniasis donovani*. [View project](#)

## *In-vitro* scavenging activity and acute toxicity study of methanol leaves extract and fractions of *Lophira lanceolata* Tiegh. Ex Keay (Ochnaceae) in rats.

Jean-Baptiste N. Oussou<sup>1,2</sup>, Isaac J. Asiedu-Gyekye<sup>2</sup>, Adou F. Yapo<sup>3</sup>, Benoit B. N'guessan<sup>1,2\*</sup>, Patrick Amoateng<sup>2</sup>, Leandre K. Kouakou<sup>1</sup>, Isaac K. Asante<sup>4</sup>, Etienne E. Ehile<sup>1</sup>

### \*Corresponding author:

Benoit B. N'guessan

<sup>1</sup>Laboratory of Physiology, Pharmacology and Phytotherapy, Nangui-Abrogoua University, 02 BP 801 Abidjan 02, Côte d'Ivoire.

<sup>2</sup>Department of Pharmacology and Toxicology, School of Pharmacy, College of Health Sciences, University of Ghana, P.O. Box LG 43, Legon, Accra, Ghana.

<sup>3</sup>Laboratory of Biochemical-Pharmacodynamics, UFR Biosciences, Felix Houphouët-Boigny University, 22 BP 582 Abidjan 22, Cocody, Côte d'Ivoire.

<sup>4</sup>Department of Plant and Environmental Biology, University of Ghana, P.O. Box LG 55, Legon, Accra, Ghana.

### Abstract

The present study aims at comparing *n-vitro* scavenging activities of methanol extract and fractions of *Lophira lanceolata* leaves, and also to study the oral acute toxicity of the ethyl acetate fraction.

Petroleum ether, dichloromethane, ethyl acetate, butanol and water fractions were prepared from the methanol extract of the plant. The scavenging activity of DPPH (2,2-Diphenyl-1-picrylhydrazyl), the total phenolic (TPC) and total flavonoid (TFC) contents of the extract and fractions were determined by spectrophotometrical methods using gallic acid (GA) and quercetin (Qu) as reference antioxidant. The fifty percent inhibitory concentration (IC<sub>50</sub>), fifty percent effective concentration (EC<sub>50</sub>) and the antiradical power (ARP) were determined for all extract and fractions. An acute toxicity study using a single oral dose of 5000 mg/kg of the ethyl acetate fraction of the plant was conducted in female Albino rats following the OECD(420) Guidelines. Blood samples were collected for hematological and biochemical analysis. Histopathological examinations of the heart, kidney and liver were performed.

The results showed that the ethylacetate fraction of *L. lanceolata* had the highest free radical scavenging activity of DPPH (IC<sub>50</sub>=1,43; EC<sub>50</sub>= 0.07 and ARP= 14,28) and also contain the highest amount of total phenols (14,4±0,02mg of GA equivalent/g of plant fraction) and total flavonoids (93,3±0,04mg of Qu equivalent/g of plant fraction) as compared to other fractions and ascorbic acid (IC<sub>50</sub>=5,82; EC<sub>50</sub>= 3.44; ARP=3,44). The hematological parameters and the lipid profile didn't show any major change compared to the control group. However, a significant increase of aspartate aminotransferase (AST, p<0.001) and alanine aminotransferase (ALT, p<0.001) showed that the ethyl acetate fraction of the methanol extract of *L. lanceolata* leaves might not totally be safe for consumption, in the conditions of our experiment.

**Keywords:** antioxidant activity, acute toxicity, hematology, biochemistry, histopathology, *Lophira lanceolata*.

### Introduction

*Lophira* belongs to the Ochnaceae family and it comprises approximately 35 genera and 600 species, thus it is widely represented in the tropics [1]. *Lophira lanceolata* is one of these species. It is a tree of 8 to 10 m tall growing in the dry wooded savanna areas and is widely distributed from West to Central African countries such as Senegal, Cameroon, Sudan and Côte d'Ivoire [2]. The tree is straight or twisted, with leaves alternate, clustered at the end of short straight branches and blade oblong-lanceolate. It has corky grey bark surface [3].

*L. lanceolata* is used, in traditional medicine, to treat several illnesses. Its Leaves are used for the management of toothache and the treatment of female infertility [4,5]. The decoction of the fresh leaves is administered orally against headaches, dysentery, diarrhea, cough, abdominal pains and hypertension [3].

Previous studies on the leaves of *L. lanceolata* have shown antihypertensive, anti-diarrheal, anti-plasmodial and antioxidant effects of the water and methanol extracts [6, 7, 8]. More recently, our research team has shown the lowering effect of the ethyl acetate fraction of *L. lanceolata* on blood pressure and heart rate of anesthetized cats [9]. The phytochemical screening of the ethanol, chloroform and petroleum ether fractions of the leaves has revealed the presence of phenols, flavonoids, glycosides, tannins

carbohydrates and sugars in these fractions [10]. An acute toxicity study reported the LD<sub>50</sub> of the ethanol, acetone, chloroform and water extracts from *L. lanceolata* [11].

Despite some few antioxidant studies on the methanol extract of *L. lanceolata* leaves, there is a need to carry out further investigations on the efficiency and safety of plants with high antioxidant potential, as recommended by the World Health Organization [12]. Antioxidants possess the ability to protect cells and tissues from damages caused by free radical and reactive oxygen species which are produced during normal oxygen metabolism or are induced by exogenous damage [13]. The mechanisms of protection of antioxidants from cells damage can be indirectly mediated by enhancing natural defence of cell and/or directly by scavenging the free radical species [14]. Natural antioxidants agents include carotenoids, vitamins, flavonoids and phenols that are microconstituents capable to prevent the destructive process caused by oxidative stress [15].

The present study was undertaken to further investigate the antioxidant potential of *L. lanceolata* leaves, by screening different fractions for the said activity so that it could serve as a basis for subsequent studies and also to further investigate the acute toxicity of the most active fraction, by analyzing the possible hematological, biochemical and histopathological changes.

## Material and methods

### Material

#### Plant material

Fresh leaves of *Lophira lanceolata* Tiegh. Ex Keay (Ochnaceae) were collected locally from the savanna region of Bouake (7°44'N; 5°04'W) in the central region of Côte d'Ivoire in July 2013. Plant was identified by late Professor Aké-Assi Laurent at the National Floristic Center of Felix Houphouët Boigny University of Cocody- Abidjan, Côte d'Ivoire, where a voucher specimen was kept (*Lophira lanceolata* Tiegh. ex Keay n 9397, December 1966, Côte d'Ivoire national herbarium). Fresh plant materials were washed with tap water and dried away from the sun for 2 weeks. They were then crushed and grounded into fine powder and stored in airtight bottles until ready for use.

#### Animals

Female albino rats (120 g–125 g body weight) were purchased from the animal house of the department of microbiology, University of Ghana. The animals were housed in cages with stainless steel grid covers and sterilized wood shaving as bedding material in a controlled environment (Temperature 25±3°C, relative humidity 60 ± 10% and light at 12h light/dark cycles). A commercial

feed and tap water were provided *ad libitum*. The animals were acclimatized for 7 days before the experiment day.

### Methods

#### Preparation of the methanol crude extract and its fractions

The method of preparation of the crude extract and its fractions has been previously described [9, 16].

Three hundred grams (300g) of air-dried powder were weighed and mixed with Methanol 80% in the ratio 1:10 (1 part of powder = 10 parts of solvent). Mixture was put in conical flasks and placed on a rotary shaker (Orbit Lab-line, Ill, USA) at 200 rpm for 24 hours at room temperature (25±3°C). The mixture was filtered on cotton wool and the residue was re-extracted twice for 6 hours. The methanol was evaporated at 50°C using a rotary evaporator (Buchi Rotavapor, Model R-210) and freeze dried using a freeze dryer (Super Modul YO 230, USA) to obtain a powder. The powder was weighed and labeled as LL<sup>CE</sup>. It was stored at 4°C in airtight bottles until ready for use. The yield of the dry extract was then calculated. Twenty grams (20g) of LL<sup>CE</sup> was dissolved in 200 ml of distilled water. The mixture was further successively partitioned (1:1, v/v) by petroleum ether (LL<sup>FPE</sup>), dichloromethane (LL<sup>FDCM</sup>), ethyl acetate (LL<sup>FEA</sup>) and saturated Butan-1-ol (LL<sup>FB</sup>). Solvents were evaporated using a rotary evaporator (Buchi Rotavapor, R-210) at 40°C. The dry extracts were weighed, labeled and stored at 4°C in airtight bottles until ready for use. The yield of these fractions was also calculated.

#### Evaluation of scavenging activity

The ability of the plant extract to scavenge DPPH free radicals was assessed according to the methods previously described [17, 18]. The stock solution of extracts were prepared in methanol to achieve the concentration of 0.1 mg/ml. Serial dilutions were made to obtain concentrations of 0.6; 1.66; 2.5; 3.3; 6.66; 10 and 16.67 µg/ml. Two ml (2ml) of each solution was mixed with 2 ml of methanol solution of DPPH (20 µg/ml). Ascorbic acid, used as a control is prepared in the same condition than extract and fractions. Control sample contained all the reagents except the extract or fractions. After 30 min incubation in darkness at room temperature (25±3°C), Absorbance (A) was recorded at 517 nm. Percentage of inhibition (I) was calculated using equation (1):

$$(1) \quad I(\%) = [(A_{\text{Control}} - A_{\text{Samples}}) / A_{\text{Control}}] \times 100$$

The fifty percent inhibitory concentration (IC<sub>50</sub>) was determined using Graph Pad software (Prism V 5.01, USA).



Fifty percent Effective Concentration ( $EC_{50}$ ) and Anti Radical Power (ARP) were calculated using formula (2) and (3) as described by [19, 20].

$$(2) \quad EC_{50} (\mu\text{g}/\mu\text{g DPPH}) = IC_{50} / [DPPH]$$

$$(3) \quad ARP = 1/EC_{50}$$

### Phytochemical screening

Secondary metabolite families were screened using methods previously described by [21, 22]

### Determination of Total Phenolic Contents (TPC)

Total phenol contents in plant extract and fractions were determined spectrophotometrically by the Folin-Ciocalteu method [18]. Extract and fractions in the concentration of 1 mg/ml in methanol were used in the analysis. The reaction mixture was prepared by mixing 0.3 ml of extract or fractions, 0.2 ml of methanol, 4.5 ml of distilled water, 0.4 ml of Folin-Ciocalteu's reagent and 0.5 ml of  $Na_2CO_3$ . The samples were thereafter incubated at room temperature for two hours. The absorbance was determined using spectrophotometer at  $\lambda_{max} = 765$  nm. The same procedure was repeated for the standard solution of gallic acid and the calibration line was constructed. Based on the measured absorbance, the concentration of phenol was read (mg/ml) from the calibration line; then the content of phenolics in extracts was expressed in terms of Gallic Acid equivalent (mg of GAE/g of extract or fractions).

### Determination of Total Flavonoid Contents (TFC)

Total Flavonoid Contents in all the extract and fractions were determined using spectrophotometric method [23]. Extract and fractions in the concentration of 1 mg/ml in methanol were used in the analysis. The reaction mixture was prepared by mixing 1 ml of the extract or fractions, 1 ml of methanol and 2 ml of  $AlCl_3$  (2%). The mixture was vortex and allows standing for an hour at room temperature. The absorbance was determined using spectrophotometer (JENWAY, Model 6305) at  $\lambda_{max} = 415$  nm. The same procedure was repeated for the standard solution of Quercetin and the calibration line was constructed. Based on the measured absorbance, the concentration of flavonoids was read (mg/ml) on the calibration line; then, the content of flavonoids in extracts was expressed in terms of Quercetin equivalent (mg of QuE/g of extract or fractions).

### Experimental animals and procedure

Rats were grouped into two groups of 5 rats each. The control group received, orally, distilled water while the treatment group was treated with  $LL^{FEA}$  with a single dose of 5000 mg/kg b.w. The animals' body weights were monitored weekly and their behaviors were observed daily for 14 days for any abnormal clinical signs such as skin changes, morbidity, aggressivity, sensitivity of the sound and pain, as well as respiratory movement. Under ether anesthesia, blood was obtained via cardiac puncture. Samples of the blood collected were aliquoted into  $K_3EDTA$ - tubes and tubes containing gel clot activator, respectively. The EDTA blood was immediately analyzed for hematological parameters using the hematology autoanalyser (Sysmex XT 2000i, Japan). The serum was prepared from gel clot activator blood using a centrifuge (Powerspin<sup>TM</sup> LX, Unico) at 4000 rpm for 5 minutes. Some electrolytes and biochemical parameters were evaluated using Eschweiler Combi Line and Hospitex Mega 200 respectively. The heart, liver and Kidneys were removed and kept in 10% buffered formalin for histopathological analysis. All experimental procedures and assays were conducted in accordance with the international guidelines for evaluating the safety of herbal medicines [24].

### Histopathological analysis of organs

After a routine procedure, the tissues were blocked in paraffin and cut to 5- $\mu\text{m}$  thickness. The tissue sections were stained with hematoxylin-eosin (H&E) and examined microscopically. The stained sections were evaluated by an experienced pathologist, who was uninformed about the groups.

### Statistical analysis

The hematological and biochemical parameters are presented as means  $\pm$  SEM and analysis for statistical differences was done using one-way analysis of variance (ANOVA). Differences were considered statistically significant at  $p < 0.05$ .

## Results

### Percent yield of plant fractions

Values for percent yield of the extracts are presented in Table 1. Dichloromethane fraction ( $LL^{FDCM}$ ) gave the lowest yield value of 6.6% while the highest yield value of 43.65% was revealed by aqueous fraction ( $LL^{FA}$ ).



**Table1.** Percent yield of methanol extract and fractions from *Lophiralanceolata*

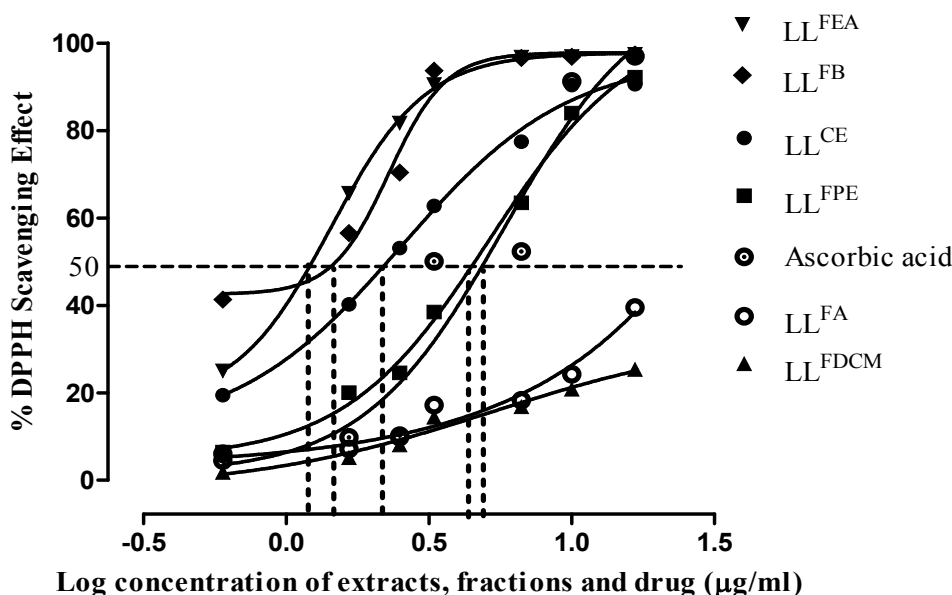
Extract and fractions	Description	Percent yield (%)
LL <sup>CE</sup>	<i>L. lanceolata</i> methanol crude extract	-
LL <sup>FPE</sup>	<i>L. lanceolata</i> petroleum ether fraction	18.9
LL <sup>FDCM</sup>	<i>L. lanceolata</i> dichloromethane fraction	6.6
LL <sup>FEA</sup>	<i>L. lanceolata</i> ethylacetate fraction	11.85
LL <sup>FB</sup>	<i>L. lanceolata</i> butanol fraction	15.6
LL <sup>FA</sup>	<i>L. lanceolata</i> aqueous fraction	43.65

### Antioxidant activity against DPPH

Figure 1 and table 2 showed DPPH radical scavenging activities of all extract and fractions from *L. lanceolata*. All of them possess scavenging properties depending on the solvent of partition, in the following decreasing order LL<sup>FEA</sup> > LL<sup>FB</sup> > LL<sup>CE</sup> > LL<sup>FPE</sup> > LL<sup>FDCM</sup> > LL<sup>FA</sup>. LL<sup>FEA</sup> has the highest maximum inhibition of DPPH (97.6 ± 0.02 %), the lowest IC<sub>50</sub> (1.43 µg/ml) and also the best anti radical power (14.28). It's followed by LL<sup>FB</sup> (IC<sub>50</sub>=2.28, EC<sub>50</sub>=0.11 and ARP=9.09) and LL<sup>CE</sup> (IC<sub>50</sub>=5.15, EC<sub>50</sub>=0.25 and ARP=8.33). LL<sup>FA</sup> and LL<sup>FDCM</sup> have the lowest radical scavenging effect with maximum inhibitions of 39.5 ± 0.21 % and 25.24 ± 0.25% respectively. In the concentration range of 0.6 to 16.67 µg/ml, all fractions, except LL<sup>FDCM</sup> and LL<sup>FA</sup> were better scavengers than ascorbic acid (IC<sub>50</sub>=5.82, EC<sub>50</sub>=0.29 and ARP=3.44).

### Total phenol (TPC) and total flavonoids (TFC) content

Results for total phenol and total flavonoid are presented in figure 2 and 3. The total phenol content of the fractions were in the following decreasing order LL<sup>FEA</sup> > LL<sup>FPE</sup> > LL<sup>CE</sup> > LL<sup>FB</sup> > LL<sup>FDCM</sup> > LL<sup>FA</sup>. Ethyl acetate fraction (LL<sup>FEA</sup>) gave the highest value for total phenol content (14.4 ± 0.02 mg of GAE/g) while the lowest value was revealed by aqueous fraction (0.134 ± 0.01 mg of GAE /g). The total flavonoid content of the fractions were in the following decreasing order LL<sup>FEA</sup> > LL<sup>FB</sup> > LL<sup>FPE</sup> > LL<sup>CE</sup> > LL<sup>FA</sup> > LL<sup>FDCM</sup>. Ethyl acetate fraction (LL<sup>FEA</sup>) gave the highest total flavonoid content (93.93 ± 0.04 mg of QuE/g) followed by Butanol fraction (LL<sup>FB</sup>) (78.31 ± 0.02) while dichloromethane fraction (LL<sup>FDCM</sup>) gave the lowest value (0.39 ± 0.03 mg of QuE/g).



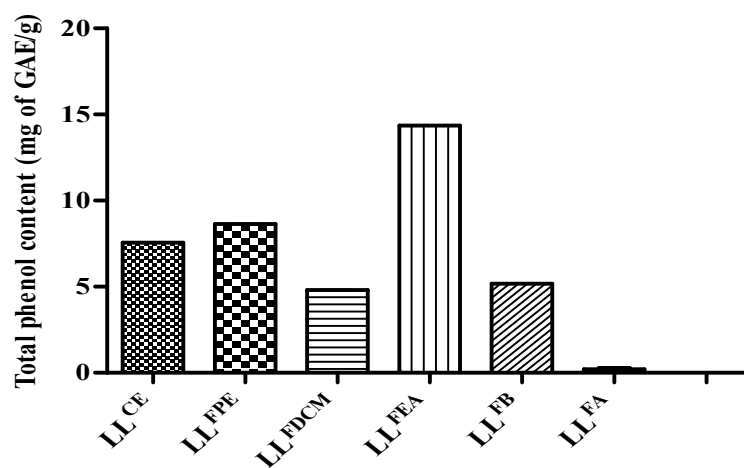
**Figure 1:** DPPH radical scavenging activity of ascorbic acid and methanol extract of *Lophira lanceolata* (Ochnaceae) leaves and its fractions.



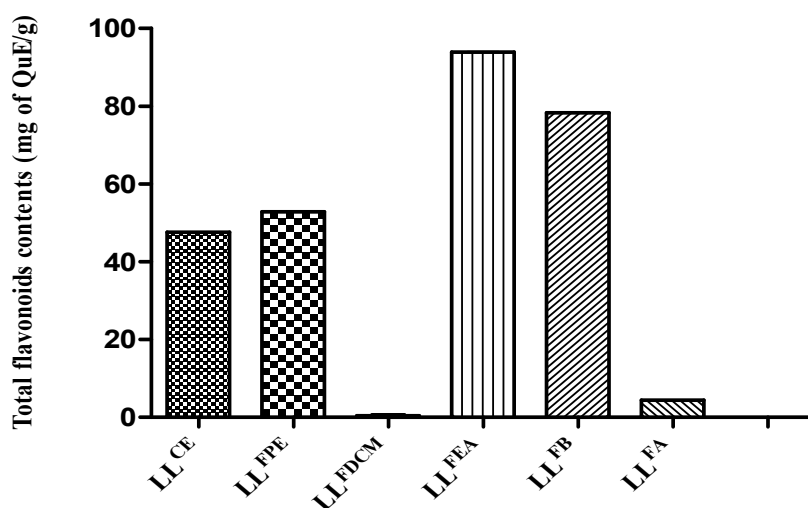
**Table 2:** Antioxidant activity parameters (IC<sub>50</sub>, EC<sub>50</sub> and ARP, n=3) of the methanol extract of *Lophira lanceolata* and its fractions

	LLCE	LLFPE	LLFDCM	LLFEA	LLFB	LLFA	Ascorbic acid
Maximum Inhibition (%)	90.6 ± 0.17	92.2 ± 0.40	25.4 ± 0.25	97.6 ± 0.02	97.3 ± 0.33	39.5 ± 0.21	97 ± 0.76
IC <sub>50</sub> (µg/ml)	2.54	5.15	-	1.43	2.28	-	5.82
EC <sub>50</sub> (µg/µg of DPPH)	0.12	0.25	-	0.07	0.11	-	0.29
ARP	8.33	4	-	14.28	9.09	-	3.44

IC: Inhibitory Concentration, EC: Effective Concentration, ARP: Anti Radical Power;



**Figure 2:** Total phenol contents of extract and fractions from *L. lanceolata*



**Figure 3:** Total flavonoid contents of extract and fractions from *L. lanceolata*



### Phytochemical Screening

Table 3 shows the results of the phytochemical screening. All the extract and fractions except LL<sup>FDCM</sup> contain tannins, phenols and

flavonoids. However, only LL<sup>CE</sup>, LL<sup>FPE</sup> and LL<sup>FA</sup> contain saponins. Neither cardiac glycosides, nor alkaloids are present in all the samples of *L. lanceolata* leaves.

**Table 3:** Phytochemical screening of methanol extract of *Lophira lanceolata* and its fractions

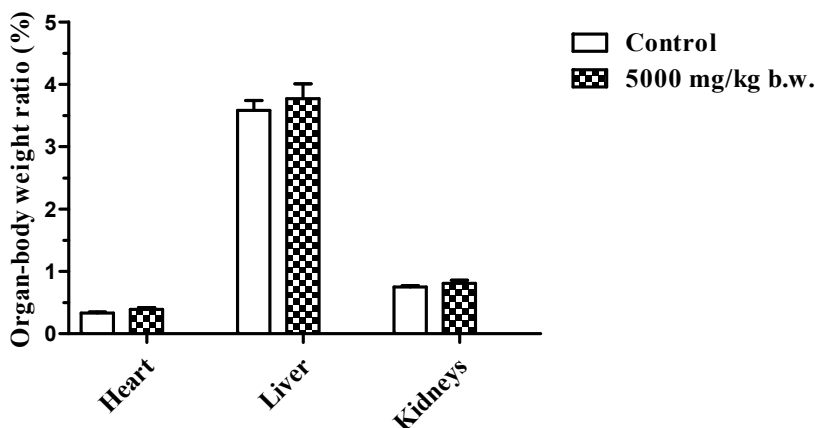
Constituents	Tests	LL <sup>CE</sup>	LL <sup>FPE</sup>	LL <sup>FDCM</sup>	LL <sup>FEA</sup>	LL <sup>FB</sup>	LL <sup>FA</sup>
Phenols	Ferric chloride test	+	+	-	+	+	+
Flavonoids	Shinoda test	+	+	-	+	+	+
Tannins	Ferric chloride test	+	+	-	+	+	+
Saponins	frothing test	+	+	-	-	-	+
Alkaloids	Mayer's test	-	-	-	-	-	-
Cardiac glycosides	Keller-Killani test	-	-	-	-	-	-

(-): absent; (+): present

### Clinical symptoms and relative organ-body weight

In the acute toxicity study, rats given high dose of LL<sup>FEA</sup> (5000mg/kg) were more agitated just after administration of the extract. This behavior ceased before the next 30 minutes. No case

of death was recorded during the 14 days of observation. The LD<sub>50</sub> was estimated to be higher than 5000 mg/kg. No significant differences are noticed in the relative organ weight of the organs (Figure 4).



**Figure 4:** Effects of the ethyl acetate fraction of *Lophira lanceolata* (LL<sup>FEA</sup>) on relative organ weight of rats

### Haematological analysis of samples

The results are presented in Table 4. There was no significant change of the haematological parameters, except the hematocrit which significantly increased by about 8% ( $p < 0.01$ ) compared to the control group.



**Table 4:** Effects of the ethyl acetate fraction (5000 mg/kg b.w.) of *Lophira lanceolata* on hematological parameters in rats.

Parameters	Groups	
	Control	5000mg/kgb.w.
WBC ( 10 <sup>9</sup> /L)	13.2 ± 1.06	13.5 ± 0,77
RBC ( 10 <sup>12</sup> /L)	8.45 ± 0.25	8.69 ± 0,53
HGB (g/dL)	14.2 ± 0.44	14.8 ± 0.27
HCT (%)	44.7 ± 0.74	48.5 ± 0.82 **
MCV (fL)	55.6 ± 1.17	56.2 ± 0.58
MCH (pg)	18.5 ± 0.36	19.6 ± 0.28
MCHC (g/dL)	34.8 ± 0.28	33.7 ± 0.38
PLT ( 10 <sup>9</sup> /L)	543 ± 40.2	620 ± 63.8
NEUT ( 10 <sup>9</sup> /L)	2.05 ± 0.06	1.91 ± 0.06
LYMP ( 10 <sup>9</sup> /L)	7.4 ± 0.4	8.52 ± 0.63
MON ( 10 <sup>9</sup> /L)	0.59 ± 0.06	0.7 ± 0.09
EOS ( 10 <sup>9</sup> /L)	1.36 ± 0.21	1.58 ± 0.13
BAS ( 10 <sup>9</sup> /L)	0.1 ± 0.007	0.12 ± 0.02

WBC: white bloodcells; RBC: redbloodcells; HGB: Hemoglobin; HCT: Hematocrit; MCV: meancorpuscular volume; MCH: mean corpuscular hemoglobin; MCHC: mean corpuscular hemoglobin concentration; LYM: Lymphocytes; MON: Monocytes; PLT: Platelet; NEUT: neutrophilis; EOS: eosinophilis; BAS: basophilis.

\*\*P < 0.01; albinos' rats (n =5/group). Data are expressed as Mean ± S.E.M.

### Biochemical analysis of samples

Table 5 and 6 show results for the biochemical test for lipid profile and liver function. Table 7 shows results obtained from the biochemical parameters used as markers for renal function. The dose of LL<sup>FEA</sup> administered had no significant effect on the lipid

profile parameters. The liver function test revealed significant increase of AST and ALT by 51.61% and 73.64% respectively (P < 0.001). There was no change in the serum levels of urea, sodium, calcium and potassium while creatinine level significantly decreased (P < 0.05) compared to control.

**Table 5:** Effects of the ethyl acetate fraction of *Lophira lanceolata* on rats' lipid profile.

Parameters	Groups	
	Control	5000mg/kgb.w.
Cholesterol (mmol/L)	2.03 ± 0.05	1.89 ± 0.06
HDL - C (mmol/L)	0.88 ± 0.06	1.3 ± 0.06
LDL - C (mmol/L)	0.9 ± 0.06	0.81 ± 0.06
Triglycerides (µmol/L)	0.58 ± 0.03	0.57 ± 0.1

HDL-C: High density lipoprotein; LDL-C: Low density lipoprotein; Albinos' rats (n =5/group). Data are expressed as Mean ± S.E.M.

**Table 6:** Effects of the ethyl acetate fraction of *Lophira lanceolata* on rats' liver function.

Parameters	Groups	
	Control	5000 mg/kg b.w.
TP (g/L)	61 ± 1.30	65.2 ± 2.82
D-BIL (µmol/l)	2.6 ± 0.4	4.8 ± 1.02
ALB (g/L)	34.4 ± 1.03	34.8 ± 1.02
ALP (U/L)	300 ± 17.1	292 ± 11.9
GGT (U/L)	10.8 ± 0.86	11.6 ± 0.92
AST (U/L)	13.6 ± 1.94	27.8 ± 0.86***
ALT (U/L)	13.6 ± 1.08	51.6 ± 0.51***

TP: total protein; T-BIL: total-bilirubin; D-BIL: direct-bilirubin; ALB: albumin; ALP: alkaline phosphatase; GGT: gamma glutamyl transferase; AST: aspartate aminotransferase; ALT: alanine aminotransferase. \*\*\*P < 0.001; Albinos' rats (n =5/group). Data are expressed as Mean ± S.E.M.



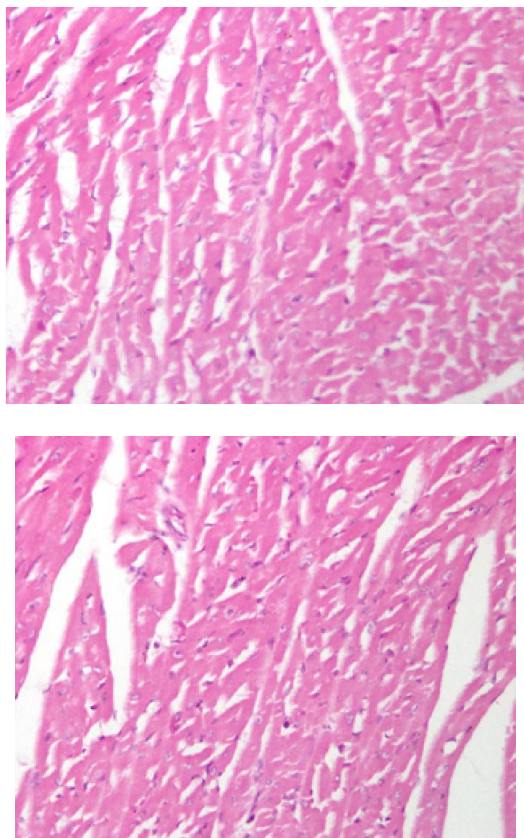
**Table 7:** Effects of the ethyl acetate fraction of *Lophira lanceolata* on rats' renal function.

Parameters	Groups	
	Control	5000 mg/kg b.w.
Na <sup>+</sup> (mmol/l)	145 ± 1.84	147 ± 1.85
K <sup>+</sup> (mmol/l)	3.8 ± 0.58	3.6 ± 0.24
Ca <sup>2+</sup> (mmol/l)	1.12 ± 0.08	1.3 ± 0.3
Creatinine (mmol/l)	61.2 ± 1.43	52 ± 3.35*
Urea (mmol/l)	7.93 ± 0.43	7.68 ± 0.31

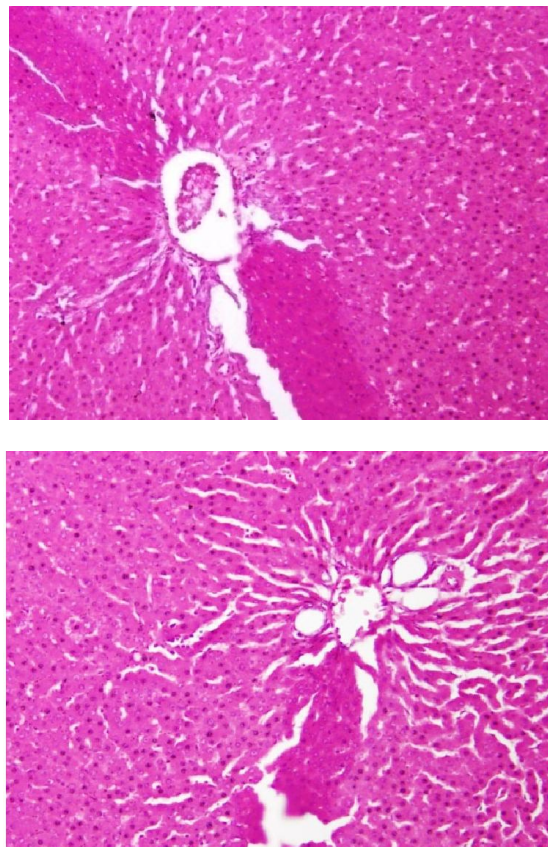
Na<sup>+</sup>: sodium ion; K<sup>+</sup>: potassium; ion Ca<sup>2+</sup>: Calcium ion. \*P < 0.05; Albinos' rats (n =5/group). Data are expressed as Mean ± S.E.M

### Histopathological analysis of organs

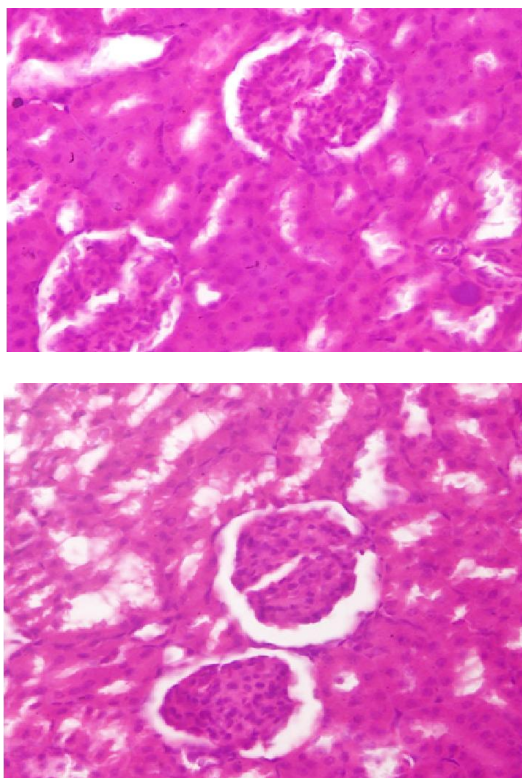
Microscopic examination of the organs in all treated groups did not revealed any structural changes (Figure 5, 6 and 7). No observable cardiomyopathy was noted in the heart, the kidneys didn't show any observable histological lesions in the glomerulus and the tubules. There were no observable histological lesions in central vein of the liver.



**Figure 5:** (40X) Micrographs of the Heart sections obtained from rats untreated (A) and rats treated with ethyl acetate fraction of *L. lanceolata* leaves (5000 mg/kg) (B)



**Figure 6:** (40X) Micrographs of the Liver sections obtained from rats untreated (A) and rats treated with ethyl acetate fraction of *L. lanceolata* leaves (5000 mg/kg) (B). CV: Central veins.



**Figure 7:** (40X) Micrographs of the Kidneys sections obtained from rats untreated (A) and rats treated with ethyl acetate fraction of *L. lanceolata* leaves (5000 mg/kg) (B). G: Glomerulus, T: Tubules.

## Discussion

Qualitative phytochemical screening of the methanol extract of *Lophira lanceolata* and its fractions revealed the presence of tannins, phenolic compounds and flavonoids and the absence of alkaloids and cardiac glycosides. This result is in accordance with those obtained by some other researchers [6, 10]. However, the quantitative analysis of the total phenol and the total flavonoid contents of *L. Lanceolata* showed that the ethylacetate fraction contains the highest amount of these two secondary metabolites. All fractions possess scavenging properties. However, apart from the dichloromethane and aqueous fractions, all other fractions have more scavenging ability than ascorbic acid. These findings are in accordance with the results found on the methanol leaves extract of *L. lanceolata*[8].

As reported in the literature, there is a high correlation between the total phenol and total flavonoid contents and the antioxidant capacity [25, 26]. This seems to be in accordance with our findings since the ethyl acetate fraction is the fraction that contains the highest amount of TPC and TFC and at the same time the fraction with the highest antioxidant ability. Phenolic compounds are potent

antioxidants because of their scavenging ability on reactive oxygen species mediated by their hydroxyl groups [26, 28]. This activity is believed to be mainly due to their redox properties, which plays an important role in adsorbing and neutralizing free radicals [29, 30].

It has been reported that bioactive fractions of various medicinal plants having free radical scavenging and antioxidant properties are useful for the prevention and treatment of cardiovascular diseases [31, 32, 33]. This could therefore justify the use of *Lophira lanceolata* in the treatment of hypertension as reported by [6, 9].

In oral acute toxicity study, single administration of 5000 mg/kg b.w. of the ethyl acetate fraction of *L. lanceolata* did not cause any death of rats during the 14 days of observation. Therefore, according to OECD's guidelines (420), the LD<sub>50</sub> of the ethyl acetate fraction might be higher than 5000 mg/kg b.w. The fraction is therefore regarded as being relatively safe or practically nontoxic and does not probably contain toxic compounds. This result is in accordance with the acute toxicity study conducted on the aqueous extract of *L. lanceolata* [11].

The assessment of hematological parameters could be used to reveal the deleterious effects of foreign compounds including plant extracts on blood constituents of animals [34]. The measured parameters didn't show any significant change, apart from the value of hematocrit. Hematocrit is a measure of the percentage of red blood cells to the total blood volume. A low value of this parameter may indicate anemia [35]. Therefore, the fraction don't cause anemia since it increases the percentage of blood cells.

The impact of the extract of LL<sup>FEA</sup> on vital organs such as liver and kidney was assessed through blood enzyme activity of AST and ALT. Under normal circumstances, these enzymes mostly reside within the cells of the liver and kidney. But when the liver or kidney is injured, these enzymes are spilled into the blood stream, and consequently their blood level rise[36]. The results showed that the leaf LL<sup>FEA</sup> affects significantly the serum level of ALT and AST suggesting that the extracts would have injured the liver and the kidney.

Creatinine and urea level serve as good indicators of the renal function [37]. Any rise in the blood of these substances levels is only observed if there is marked damage of functional nephrons [38]. The leaves *L. lanceolata* reduced significantly the serum Creatinine in this study. The reduction of serum creatinine and urea would suggest that LL<sup>FEA</sup> would not have affected negatively the renal cells.

In toxicology studies, organ weight and structural changes is an important endpoint for detecting harmful effects of chemicals [39]. The results of this study revealed that the essential organs, such as liver, kidneys and heart did not showed any significant weight and structural changes at the end of the experiment. This result suggests that LL<sup>FEA</sup> would not really cause any lesion on the analyzed organs as shown by the histopathology examination of the heart, kidney and liver in the control and treated rats revealed no visible lesion or necrotic sign. This result suggests that the ethyl acetate fraction of *Lophira lanceolata* leaves do not have toxic effect on these organs.



These results seem contrary to the significant increase of ALT and AST indicating a dysfunction of the kidney and liver. However, this change might not be of significant clinical importance.

## Conclusion

According to our findings, the ethylacetate fraction of *Lophira lanceolata* leaves showed the highest amount of total phenol and flavonoids contents. This fraction also showed the best free radical scavenging activity of DPPH. TPC and TFC contained in the leaves extract and fractions could be responsible of the antioxidant ability of *Lophira lanceolata*. In addition, the fraction seems to be non-toxic in our experiment regarding its LD<sub>50</sub> and the beneficial effects on the hematological, biochemical and histopathological parameters studied on rats.

## Abbreviations

LL<sup>CE</sup>: *Lophira lanceolata* methanol crude extract; LL<sup>FPE</sup>: *L. lanceolata* petroleum ether fraction; LL<sup>FDCM</sup>: *L. lanceolata* dichloromethane fraction; LL<sup>FEA</sup>: *L. lanceolata* ethyl acetate fraction; LL<sup>FB</sup>: *L. lanceolata* butanol fraction; LL<sup>FA</sup>: *L. lanceolata* aqueous fraction; DPPH: 2, 2-diphenyl-1-picrylhydrazyl; IC: Inhibitory Concentration; EC: Effective Concentration; ARP: Anti Radical Power; GA: Gallic Acid; Qu: Quercetine; TPC: Total Phenol Contents; TFC: Total Flavonoid Contents.

## References

- [1]. White L, Abernethy K. *Guide de la végétation de la Réserve de la Lopé*. Libreville: ECOFAC Gabon 1996; 224 p.
- [2]. Adjahoun ES, Ake AL. Contribution au recensement des plantes médicinales de Côte d'Ivoire (Tome 1), Centre National de Floristique, Abidjan, Côte d'Ivoire 1979; 356 p.
- [3]. Arbonier M. Arbres, arbustes et lianes des zones sèches d'Afrique de l'ouest. CIRAD, MNHN, UICN2000; 425-427.
- [4]. Adjahoun EJ, Akéassi L, Floret JJ, Ginko S, Koumare M, Ahyi AMR, Raynal J. Médecine traditionnelle et pharmacopée : contribution aux études ethnobotaniques et floristiques au Mali, Paris, ACCT 1981; 291 p.
- [5]. Ghogomu RT, Sondengam BL, Martin MT, Bodo B. Lophirones D and E: two new cleaved biflavonoids from *Lophira lanceolata*. *J Nat Prod*. 1989; 52: 284.
- [6]. Kouakou K L, Bléyé NM., Oussou NJ-B, Konan BA, Amonkan KA, Abo KJ-C, Yapo AP, Ehilé EE. Effects of leaf decoction from *Lophiralanceolata* Tiegh. Ex Keay (Ochnaceae) on arterial blood pressure and electrocardiogram in anesthetized rabbits. *Pharma innovation* 2013; 2 (9) 66-73.
- [7]. Igboeli N, Onyeto CA, Okorie AN, Mbaoji FN, Nwabunike IA, Alagboso DI. Antidiarrheal activity of methanol leaf extract of *Lophira lanceolata* Tiegh (Ochnaceae), *Merit Res. J. Environ. Sci. Toxicol*. 2015; 3(4): 059-064.
- [8]. Onyeto CA, Akah PA, Nworu CS, Okoye TC, Okorie NA, Mbaoji FN, Nwabunike IK, Okumah N, Okpara O. Antiplasmodial and antioxidant activities and methanol extract of the fresh *Lophira lanceolata* (Ochnaceae). *Afri J Biotechnol*. 2014; 13 (16): 1731-1738.
- [9]. Oussou NJ-B, Eric Boakye-G, Kouakou KL, N'guessan BB, Amoateng P, Yapo AF, Asiedu-Gyekye IJ, Ehilé EE. Comparative effect of different extracts and fractions from *lophiralanceolata* tiegh. Ex keay (ochraceae) leaves on arterial blood pressure and heart rate in anaesthetized cats, *WJPPS*. 2015; 4(11): 55-68.
- [10]. Audu SA, Mohammed I, Kaita HA. Phytochemical screening of the leaves of *Lophira lanceolata* (Ochnaceae). *Life Sci J* 2007; (4):75-79.
- [11]. Audu SA, Abdulraheem OR, Sule IM, Ilyas M, Haruna AK, Sikira AS. Acute toxicity studies of *Lophira lanceolata* leaf extract. *RJPBCS*. 2011; 2(1): 629-636.
- [12]. WHO. Promotion du rôle de la médecine traditionnelle dans le système de santé. Stratégie de la région africaine 2001; pp. 17-19.
- [13]. Martinez-Valverde I, Periago MJ, Ros G. Significadonutricional de los componentesfenolicos de la dieta. *ArchLatinoamNutr* 2000; 50: 5-18.
- [14]. de Groot H, Rauen U. Tissue injury by reactive oxygen species and the protective effects of flavonoids. *FundamClinPharmacol* 1998; 12:249-55.
- [15]. Branien AL. Toxicology and biochemistry of butylated hydroxyanisole and butylated hydroxytoluene. *J Am Oil Chem Soc* 1975; 52(2):59-63.
- [16]. Zirihi GN, Kra AKM, Bahi C, Guédé-Guina F. Plantes médicinales immunostimulantes: critères de sélection, techniques rapides d'extraction des principes actifs et méthodes d'évaluation de l'activité immunogène. *Rev Pharm MédTrad Afr*. 2003; 17: 131-8.



- [17]. Brand-Williams W, Cuvelier ME, Berset C. Use of free radical method to evaluate antioxidant activity. *Lebensmittel-Wissenschaft und-Technol* 1995; 28:25–30.
- [18]. Bursal E, Gulcin I. Polyphenol contents and in vitro antioxidant activities of lyophilized aqueous extract of kiwifruit (*Actinidiadeliciosa*). *Food Res Int*. 2011; 44:1482–1489.
- [19]. Kroyer GT. Red clover extract as antioxidant active and functional food ingredient. *Innovat Food SciEmerg Tech*. 2004; 5: 101-105.
- [20]. Prakash D, Upadhyay G, Gupta C, Pushpangadan P, Singh KK. Antioxidant and free radical scavenging activities of some promising wild edible fruits. *Int Food Res J*. 2012; 19 (3):1109-1116.
- [21]. Harborne JB. *Phytochemical methods* Second edition, By Chapman and Hall, London and New York 1984; 37(3):19-25.
- [22]. Bekro Y, Bekro J, Boua BB, Tra-Bi F, and Ehilé EE. Etude ethnobotaniqueet screening phytochimique de *Caesalpinibenthamiana* (Baill.) HerendetZarrucchi (Caesalpinaceae). *Sci& Na*2007; 2(4): 217-225.
- [23]. Park YK, Koo MH, Ikegaki M, Contado JL. Comparison of the flavonoid aglycone contents of *Apismelliferapropolis* from various regions of Brazil. *ArqBiolTecnol*1997;40, 97-106.
- [24]. OECD. Organization for Economic Cooperation and Development Guidelines, for *Testing of Chemicals:Acute Oral Toxicity-Fixed Dose Procedure*, 2001; 420 P.
- [25]. Shariffar F, Dehghn-Nudeh G, Mirtajaldini M. Major flavonoids with antioxidant activity from *Teucriumpolium* L. *Food Chem* 2009; 112:885–888.
- [26]. Khan RA, Khan MR, Sahreen S. Assessment of flavonoids contents and in vitro antioxidant activity of *Launaeaprocumbens*. *Chem Central J* 2012; 6:43.
- [27]. Cao G, Sofic E, Prior RL. Antioxidant and pro-oxidant behavior of flavonoids: Structure activity relationships. *Free Rad Biol Med*2009; 22:749–760.
- [28]. Mateji JS, D ami AM, Mihajilov-KrsteV TM, Ran elovi VN, Krivošej Z, Marin PD. Total phenolic and flavonoid content, antioxidant and antimicrobial activity of extracts from *Tordylium maximum*, *J App Pharm Sci*2013; 3 (1): 055-059.
- [29]. Yingming P, Ping L, Hengshan W, Min L. Antioxidant activities of several chinese medicinal herbs. *Food Chem*2004; 88: 347-350.
- [30]. Louli V, Ragoussis N, Magoulas K. Recovery of phenolic antioxidants from wine industry by products. *BioresourTechno*2004;92, 201–208.
- [31]. Ranelletti FO, Maggiano N, Serra FG. Quercetin inhibits p21-ras expression in human colon cancer cell lines and in primary colorectal tumors. *Inter J Cancer*1999; 85: 438-445.
- [32]. Langley-Evans C. Antioxidant potential of black and green tea determined using the ferric reducing power (FRAP) assay. *Intl J Food Sci Nu*2000; 51:181–188.
- [33]. Alasalvar C, Karamac M, Amarowicz R, Shahidi F. Antioxidant and antiradical activities in extracts of *Hazelnut kernel* (*Corylusavellana* L.) and hazelnut green leafy cover. *J Agric Food Chem*2009; 54:4826-4832.
- [34]. Oyedemi SO, Bradley G, AfolayanAJ. Toxicological effects of the aqueous extract of *Strychnoshenningsii*Gilg in Wistar rats. *J Nat Pharm*2010; 1(1): 33-39.
- [35]. Stephen HR, Reich PR. *Hematology*. Pathologic basis for clinical practice, Third edition Little Brown, 2000; 460 p.
- [36]. Ghasi S, Egwuibe C, Achukwu PU, Onyeanusu JC. Assessment of the medical benefit in the folkloric use of *Bryophyllum Pinnatum* leaf among the Igbos of Nigeria for the treatment of hypertension. *Afr J Pharm Pharmacol* 2011; 5(1): 83-92.
- [37]. Hilaly E, Israeli ZH, Lyoussi B. Acute and chronic toxicological studies of *Ajuvaiva* in experimental animals. *J Ethnopharmacol*. 2004; 91(1): 43-50.
- [38]. Lameire N, Biesen VW, Vanholder R. Acute renal failure. *The Lancet* 2005; 365 (9457): 417-430.
- [39]. Sellers RS, Morton D, Michael B. Society of Toxicology Pathology position paper: organ weight recommendations for Toxicology studies. *Toxicol Pathol* 2007; 35(5): 751-755.

