

**PREVALENCE OF NEUROABNORMALITIES IN PRETERM
NEONATES: A STUDY USING ULTRASONOGRAPHY AT THE
KORLE-BU TEACHING HOSPITAL**

JONATHAN KELVIN SEMETEY

(10434066)

**A DISSERTATION TO BE SUBMITTED IN PARTIAL FULFILMENT
TOWARDS THE AWARD OF MASTER OF SCIENCE DEGREE IN
MEDICAL ULTRASONOGRAPHY**

**DEPARTMENT OF RADIOGRAPHY
SCHOOL OF ALLIED HEALTH SCIENCES, COLLEGE OF HEALTH
SCIENCES, UNIVERSITY OF GHANA**



JULY 2014

DECLARATION

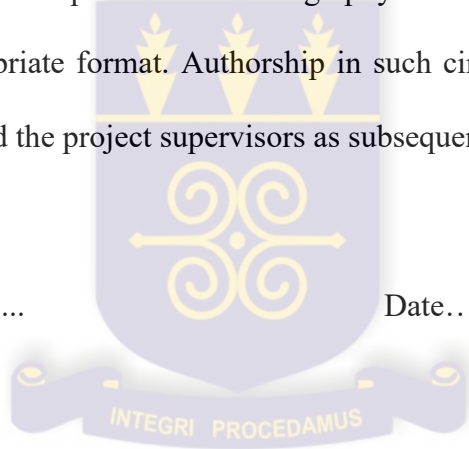
I JONATHAN KELVIN SEMETHEY do hereby declare that this thesis which is being submitted in fulfillment of the requirements for the degree of Master of Science in Medical Ultrasonography is the result of my own project performed under supervision, and that except where otherwise other sources are acknowledged and duly referenced, this work has not previously been accepted in substance for any degree and is not being concurrently submitted in candidature for any degree

I hereby give permission for the Department of Radiography to seek dissemination/publication of the dissertation in any appropriate format. Authorship in such circumstances to be jointly held between me as first author and the project supervisors as subsequent authors.

Signed

(10434066)

Date.....



Signed

(Dr. V.K. Hewlett)

Date.....

Signed

(Dr. S. Anim-Sampong)

Date.....

Signed

(Dr. S. Opoku-Head of Department)

Date.....

DEDICATION

This work is dedicated to God who granted me knowledge, understanding and wisdom for the purpose of preserving human life.

I also dedicate it to my spouse (Mrs. Janet Semetey) and all my children (Jonathan, Julius and Janelle) for their steadfastness and support throughout this work.

Finally, this dedication is extended to all the participants in this study.




ACKNOWLEDGEMENT

I acknowledge with gratitude the Lord's provision for carrying out this work.

I also acknowledge the scientific and academic support of my supervisors: Dr. Vincent Kwaku Hewlett and Dr. Samuel Anim-Sampong.

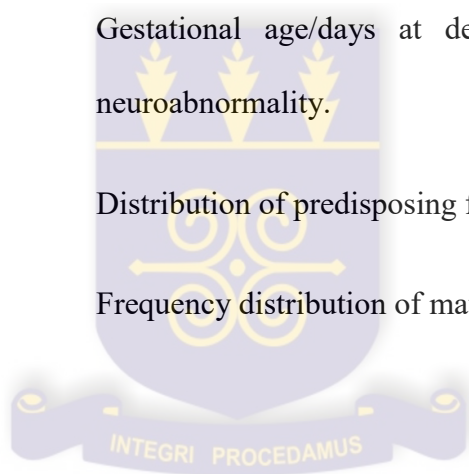
The inputs of Dr. A.H. Scakey and Prof. B.Q. Goka of the Child Health Department, Korle-Bu Teaching Hospital are very much acknowledged.

Finally, my profound gratitude and acknowledgement goes to all the doctors, nurses and all the staff at the Neonatal Intensive Care Unit of Korle-Bu Teaching Hospital.



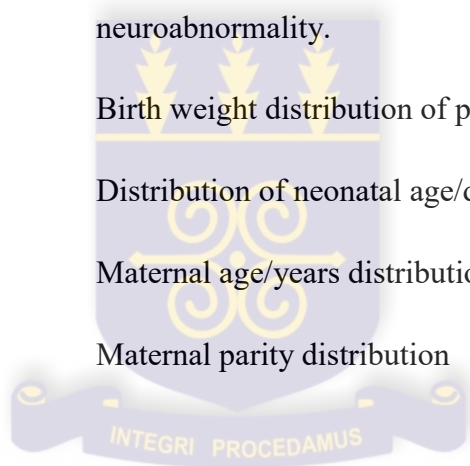
LIST OF FIGURES

- Figure 3.1 Parasagittal ultrasound image of the neonatal brain.
- .Figure 3.2 Coronal ultrasound image of the neonatal.
- Figure 4.1 A bar chart depicting the prevalence of neuroabnormalities in preterm neonates .
- Figure 4.2 Distribution of hydrocephalus location
- Figure 4.3 Gestational age/days at delivery and the presence of neuroabnormality.
- Figure 4.4 Distribution of predisposing factors to preterm delivery.
- Figure 4.5 Frequency distribution of maternal educational level.



LIST OF TABLES

Table 3.1	Technical specification of sonoscape SSI 6000
Table 4.1	Demographics
Table 4.2	Types of hydrocephalus
Table 4.3	Gestational age/weeks at delivery
Table 4.4	Apgar score for participants diagnosed of neuroabnormality and participants without neuroabnormality
Table 4.5	Association (Odd ratio) between PROM and neuroabnormality.
Table 4.6	Birth weight distribution of participants.
Table 4.7	Distribution of neonatal age/days at scan time.
Table 4.8	Maternal age/years distribution
Table 4.9	Maternal parity distribution



LIST OF ABBREVIATIONS

ACOG	American College of Obstetricians and Gynecologists
AIUM	American Institute of Ultrasound in Medicine
ALARA	As Low As Reasonably Achievable
CF	Calcarine Fissure
CM	Arnold-Chiari Malformation
CP	Cerebral Palsy
CT	Computer tomography
HIV	Human Immunodeficiency Virus
ICH	Intracranial Haemorrhage
IVH	Intraventricular Haemorrhage
MRI	Magnetic Resonance Imaging
NICU	Neonatal Intensive Care Unit
NINDS	National Institute of Neurological Disorders and Stroke
PIH	Pregnancy Induced Hypertension
POF	Posterior Occipital Fissure
PROM	Premature Rupture of Membranes
PVEs	Periventricular Echodensities
PVH	Periventricular Haemorrhage
PVL	Periventricular Leukomalacia
SEH	Subependymal Haemorrhage
SCD	Sickle Cell Disease
SF	Sylvian Fissure
USB	Universal Serial Bus

VGA

Vein of Galen Aneurysm

WHO

World Health Organisation



ABSTRACT

Introduction: Over the years, ultrasound imaging has been used to diagnose neurological abnormalities of neonates in general and premature infants in particular. This is because the anatomy of the neonatal brain can be demonstrated on ultrasound images with high precision. Neonatal sonography is possible because the fontanelles of the skull allows ultrasound beam to penetrate to the brain tissue. In Ghana, little or no data is available on the prevalence of neuroabnormalities in premature babies.

Aim: To determine the prevalence of neurological abnormalities in preterm neonates at the Korle-Bu Teaching Hospital.

Methodology: The study was done at the NICU of the Korle-Bu Teaching Hospital using a 2D mobile ultrasound machine with Doppler application (SonoScape SSI-6000, 2012). Purposive sample size was determined by the formula: $N = X_p t$ (where X_p is preterm neonates admitted daily, t is sampling time and N is sample size). The cranial ultrasound was performed through the anterior fontanelle of the preterm babies in the incubator or baby cot. The brain was examined and the neurosonographic findings recorded. Data collected was analyzed using computer software, Microsoft Excel for windows 2007.

Results: The prevalence of preterm neuropathologies was %15 (18) of the sample size of 120. Neuroabnormalities of preterm neonates studied were numerically significant in neonates delivered at lower gestational age (<30weeks).

Conclusion: The study showed 15% prevalence rate of brain abnormalities. Also an association was established between PROM and premature neonatal neuropathologies.

TABLE OF CONTENTS

Declaration	i
Dedication	ii
Acknowledgement	iii
List of figures	iv
List of tables	v
List of abbreviations	vi
Abstract	viii
CHAPTER ONE: INTRODUCTION	
1.1 Background	1
1.2 Statement of the problem	3
1.3 Significance of the study	4
1.4 Aim	4
1.5 Specific objectives	4
CHAPTER TWO: LITERATURE REVIEW	
2.1 Introduction	5
2.2 Preterm neonatal neurosonography	6

2.3	Neuropathologies of preterm neonates	8
2.4	Arnold Chiari malformation	8
2.5	Intracranial haemorrhage	10
2.6	Pathophysiology of PVH	10

CHAPTER THREE: METHODOLOGY

3.1	Introduction	11
3.2	Study design	11
3.3	Study setting	11
3.4	Study duration	12
3.5	Sample size	12
3.6	Sampling method	13
3.7	Inclusion criteria and exclusion criteria	13
3.8	Equipment	13
3.9	Recruitment procedure	14
3.10	Ultrasound examination technique	15
3.11	Data management and analysis	17
3.12	Risk management	18
3.13	Quality assurance	19
3.14	Ethical consideration	19

CHAPTER FOUR: RESULTS

4.1	Introduction	20
4.2	Demographics	20
4.3	Prevalence of neuroabnormality	22
4.3.2	Prevalence of hydrocephalus	23

CHAPTER FIVE: DISCUSSION

5.1	Introduction	31
5.2	Demographics	31
5.3	Presence or absence of neuroabnormality	31
5.4	Hydrocephalus	37
5.5	Delivery at low gestational age	39
5.6	Birth weight and apgar score of participants	40
5.7	Predisposing factors for preterm delivery	40
5.8	Premature rupture of membranes	41

CHAPTER SIX: CONCLUSION

6.1	Introduction	43
6.2	Recommendation	45
6.3	Limitation	45

Reference	47
Appendix I: Budget	51
Appendix II: Participants information sheet	52
Appendix III: Participants assent form	54
Appendix IV: Demographics	55
Appendix V: Ethical clearance	58

CHAPTER ONE

INTRODUCTION

1.1 BACKGROUND

Over the years, neurosonography has been used to diagnose neurological abnormalities of neonates in general and premature infants in particular. This is because the morphology of the neonatal brain can be demonstrated on ultrasound images with high precision at lower cost. Neonatal neurosonography is possible because the fontanelles of the skull allows ultrasound beam to be transmitted through the brain tissue. Neurosonography is the use of ultrasound to produce images of the central nervous system for diagnostic purposes.

Neonates refer to infants in the first 28 days of life (Queensland Maternity and Neonatal Clinic Guidelines, 2011). Preterm neonates are infants whose birth occurs at less than 37 completed weeks (259 days of gestation) and have higher rates of neurological disorders, including cerebral palsy and sensory deficits (Beck *et al.*, 2009; Lewis and Chamberlain, 1990). Cerebral palsy is a neurological disorder that affects muscle tone and coordinated movement in affected infants. It is caused by brain damage occurring during foetal development process. Some of the neurological deficits on affected infants include impaired speech, hearing, movement and intelligent quotient. There are three types of cerebral palsy, namely; spastic cerebral palsy, athetoid cerebral palsy and ataxic cerebral palsy (Bachrach, 2012). It is therefore important to ascertain the underlying causes or predisposing factors of these neurological abnormalities in preterm neonates.

According to Chau *et al.* (2009), prenatal infections and hypotension are associated with an increased risk of brain injury in the premature newborns. This could be a factor aside many prenatal causes of neurological abnormalities in the preterm neonate. Even though the risk factors for premature delivery are known to be infections which in some cases are preventable, many cultural and economic reasons in Ghana hinder eradication or reduction interventions. Thus, preterm delivery according to the World Health Organisation (WHO) statistics is a medical challenge which may remain so for many years as reported (WHO, 2009).

In another work, the WHO enumerated the causes of death in newborns. The report further explained that premature birth is caused by conditions among others like foetal asphyxia and infection, accounting for 80% of deaths among neonates born before term. Indeed, the report underscores the increasing rate of preterm delivery in most developing countries (including Ghana) and further identified it as the second leading cause of death among children less than five years of age (WHO, 2012). This statistics had prompted the need for more dedicated approach to preterm neonatal research in general and neuroabnormalities in particular in a setting such as Ghana, making use of less costly but effective diagnostic procedure like ultrasound imaging. In doing so however, the sonographic screening must follow guidelines as prescribed by the American Institute of Ultrasound in Medicine (AIUM, 2009).

In England and Wales in the UK, Willacy (2010) reported that 11657 preterm infants were born at <33 weeks of intrauterine gestation. The report further explained that over 90% of those neonates who survived may present with hidden disabilities which was also in agreement with Graziani *et al.* (1990). In Ghana, little or no statistics is available on neurosonographic findings

pertaining to the prevalence of abnormalities in preterm neonates. However, anecdotal report indicates that neuropathologies had increased over the years.

The study ascertained the prevalence of neurological conditions that affect neonates in general and preterm babies in particular. Some of these pathologies include; germinal matrix haemorrhage, congenital malformation (agenesis of corpus callosum, Arnold-Chiari malformations, Dandy-Walker syndrome, holoprosencephaly and hydranencephaly, vein of Galen aneurysm), intracranial cysts, neoplasms and inflammatory disease of the brain and meninges. These abnormalities may lead to serious neurological deficits and even death.

1.2 STATEMENT OF THE PROBLEM

WHO reports have shown an increasing trend in preterm birth rates in most countries including Ghana and has further identified it as the second leading cause of death in children less than five years (WHO, 2012). Therefore, identification of conditions necessitating preterm mortality required investigations. Also, available data on neurological findings in other jurisdictions were skewed to studies from autopsy and in cases where sonography was used, intracranial haemorrhage dominated the studies. Finally data on neurosonographic findings in preterm neonates is absent in Ghana

1.3 SIGNIFICANCE OF THE STUDY

Ultrasound imaging of the neonatal brain in other jurisdictions had proven to be capable of diagnosing neurological abnormalities. Since preterm deliveries also occur in Ghana, the above approach could be replicated in Ghana. For these reasons there was the need to study the prevalence of neurological abnormalities in preterm neonates using ultrasound imaging.

Neurosonography is non-invasive with capability of diagnosing pathologies with high precision at lower cost. The study's outcome added to the knowledge base of the profession and also serves as a reference database on which future studies could be based.

1.4 AIM

The study was aimed at assessing the prevalence of neurological abnormalities related to premature neonates using ultrasonography

1.5 SPECIFIC OBJECTIVES

The study objectives included:

- determination of the prevalence of neurological abnormalities related to preterm neonate using ultrasonography
- identification of the regions within the brain where these abnormalities mostly occurred
- establishment of gestational age at delivery in which these abnormalities are predominant.
- identification of predisposing factors related to neurological abnormalities of preterm neonates.

CHAPTER TWO

LITERATURE REVIEW

2.1 INTRODUCTION

Assessment of neuroanatomical structures like insula, Sylvian fissure (SF), parieto-occipital fissure (POF) and Calcarine fissure (CF) are possible during prenatal ultrasound examination (Alonso *et al.*) In addition, other important structures such as the lateral ventricles, choroid plexus, falx cerebri, septum cavum pellucidum, and cerebellum can equally be assessed in details during intrauterine life of the foetus (Correa *et al.*, 2006).

According to Romosan *et al.*, (2009), 68% of all chromosomally normal fetuses with a major malformation were detected before birth and 37% were diagnosed before 22 weeks of intrauterine gestation. An image display ultrasound technology such as ‘OmniView’ can be used to visualize standard sagittal and coronal planes in the brain according to Rizzo *et al.*, (2011) who demonstrated that the use of ultrasound imaging in assessing and diagnosing neurological abnormalities could even be traced to routine anomaly antenatal scan which primarily focuses on determining foetal abnormalities in the second trimester and beyond. All these sonographic evaluations are possible because neurosonography had proven to be equally accurate compared to MRI in diagnosing intracranial abnormalities in foetus (Malingier *et al.*, 2004). There was also an account that, though intraventricular haemorrhage (IVH) was known to occur after birth, documentary evidence showed that in-utero occurrence was possible (Malingier *et al.*, 2004). In-utero occurrence of IVH may account for a significant number of neonates delivered before term.

Therefore, assessing the preterm neonate using ultrasound imaging has been a routine practice in the past in many jurisdictions even though its application in diagnosis and management of such neonates is not so in Ghana. This can be attributed to lack of dedicated equipment (neuro-specific) and competent sonographers. All these sonographic evaluations are possible because neurosonography had proven to be equally accurate compared to more sophisticated equipment like MRI (Magnetic Resonance Imaging) in diagnosing intracranial abnormalities in foetus (Malinger *et al.*, 2004).

2.2 PRETERM NEONATAL NEUROSONOGRAPHY

According to Clair *et al.* (1984) neurosonography is an established diagnostic technique used in the evaluation of intracranial anatomy and pathology in fetuses and neonates. This and other studies confirmed the use of sonography in the diagnosis and management of intracranial haemorrhage (ICH), and subependymal haemorrhage (SEH), hydrocephalus and miscellaneous ventricular anomalies, and acute problems such as intraventricular haemorrhage (IVH) and posthaemorrhagic hydrocephalus (Judy *et al.*, 2003). Pidcock *et al.* (1990) also found the presence of moderate to severe periventricular echogenicities (PVEs) with large cyst formation, which presented positive and negative predicting values of 90% and 93% respectively. According to the study, the presence of moderate to severe PVEs with large cyst formation was the most sensitive and specific neurosonographic findings for predicting cerebral palsy (CP). Thus, other sonographic features of the brain in preterm neonates can be used to predict future complications.

According to Whitaker *et al.* (2011), preterm neonates diagnosed of germinal matrix or IVH using ultrasound imaging of the brain had increased risk for major depressive and obsessive disorders in adolescent age, compared to those without any abnormality.

A study conducted in Uganda concluded that the prevalence rate of ICH among preterm neonates was 17% as compared to previous studies which found prevalence of ICH between 10 to 70% depending on the gestational age and weight of neonates (Muganga, 2009). In particular the germinal matrix is a zone for neonatal glial cells production and proliferation, and is highly vascular and metabolically active area in the developing brain. Lying beneath the ependyma of the lateral ventricles, it is a common site for ICH as well as the subarachnoid space and the cerebella (Muganga, 2009).

Even though earlier works (Judy *et al.*; 2003; Muganga, 2009) sought to ascertain neurological abnormalities among premature neonates, all efforts were geared towards ICH to the extent that little research was carried out on other conditions such as congenital malformations, periventricular leukomalacia (PVL), neoplasm and inflammatory disease of the brain and meninges. However, this development is acceptable since ICH is the commonest cause of morbidity and mortality in the preterm neonate, accounting for 30% (Muganga, 2009).

Maternal infection during pregnancy was found to be a risk factor for the development of PVL (Steneva *et al.*, 1997). Another study by Kamuzaki *et al.*, (2002) suggested that, disturbed placental circulation underlies the development of PVL in the majority of cases with prenatal and perinatal brain injury. However, more examination of the placenta is required in explaining the pathophysiology of PVL. Perlman (1996) concluded that preterm infants born to mothers with premature rupture of membranes (PROM) and/or chorioamionitis seem to be at an increased risk

for development of PVL. It is also known that there is statistical significance in the incidence of brain injury due to chorioamnionitis leading to an increase of PVL (Xu, 2012). Even though the findings were in agreement with earlier publication by the author careful evaluation is required.

2.3 NEUROPATHOLOGIES OF PRETERM NEONATES

The neuroabnormalities common to preterm neonates include ICH, PVL, neoplasm and Arnold-Chiari malformation (ACM). Others are inflammatory disease of the brain and the meninges, hydrocephalus and Dandy-Walker syndrome. For purposes of completeness it is important to discuss some of the common conditions like ACM, ICH and PVL.

2.3.1 Arnold Chiari Malformation

The location of part of the cerebellum below the foramen magnum is termed Arnold Chiari malformation and commonly called Chiari malformation (CM). It is a structural defect in the cerebellum, the part of the brain that controls balance. According to the National Institute of Neurological Disorders and Stroke (NINDS), the cerebellum and parts of the brain stem normally sit in an indented space at the lower posterior aspect of the skull, above the foramen magnum (NINDS, 2013).

The causes of ACM include congenital CM which is initiated by genetic mutations or lack of proper nutrients in maternal diet. It can also be acquired if cerebrospinal fluid is drained excessively from the lumbar or thoracic regions of the spine either to injury, exposure to harmful substances or infection (NINDS, 2013). ACM is classified as type I, type II, type III and type IV.

Type I involves the extension of the cerebellar tonsil into the foramen magnum without involving the brain stem (NINDS, 2013). It is the common form of CM and is usually first

noticed in adolescents or adulthood, often by accident during an examination for another condition. According to the NINDS, it is the only type of CM that can be acquired (NINDS, 2003). Type II is a classical form of CM and involves the extension of both cerebellar and brain stem tissue into the foramen magnum. The cerebellar vermis may be only partially complete or absent. Type II CM is usually accompanied by myelomeningocele (NINDS, 2013; Volpe, 1981).

Type III is the most serious form of CM. The cerebellum and brain stem herniated through the foramen magnum and into the spinal cord. Part of the brain's fourth ventricle may also protrude into the spinal cord. Type III CM causes severe neurological defects (NINDS, 2013; Volpe, 1981).

Type IV involves an incomplete or underdeveloped cerebellum. In this rare form of CM the cerebellar tonsils are located in a normal position but parts of the cerebellum are missing and portions of the skull and spinal cord may be visible (Volpe, 1981)

Symptoms of CM includes; neck pain, balance problems, muscle weakness, difficulty in swallowing, ringing or buzzing in the ear, hearing loss, vomiting, insomnia, depression and headache (NINDS, 2013).

2.3.2 Intracranial Haemorrhage

Various pathologies of neurological origin were described by Volpe (1984). ICH is however a major cause of morbidity and mortality in preterm neonates. It occurs mostly in low birth weight (< 1.50kg) and below 32 weeks of gestation (Mack *et al.*, 1981). The four important and clinically recognized types of ICH are periventricular haemorrhage (PVH), subarachnoid

haemorrhage, subdural haemorrhage and intracerebellar haemorrhage (Muganga, 2009; Allan *et al.*, 1980).

2.3.2.1 Pathophysiology of Periventricular Haemorrhage

The germinal matrix is the common site for bleeding in the preterm neonate. The germinal matrix is highly vascular and present in premature babies but not full term infants (Muganga, 2009). Vessels in the germinal matrix are composed of a single layer of fragile endothelial cells which are prone to rupture in case of changes in blood volume and flow (Muganga, 2009; Volpe *et al.*, 1981; Sherman and Rosenberg, 1994). According to Muganga (2009) several factors including hypoxia or ischemia is thought to cause hypoperfusion and venous distention followed by increased vascular pressure and resultant rupture of vessels in the germinal matrix.

CHAPTER THREE

METHODOLOGY

3.1 INTRODUCTION

This Chapter deals with the measures, procedures and action taken in order to comply with protocols and ethical issues regarded in the ethical clearance. It also deals with techniques used in the actual ultrasound scanning such as sonographic positioning, technique and equipment used.

3.2 STUDY DESIGN

A quantitative cross-sectional study was adopted for this research work. This design was chosen because of the limited study time, coupled with the fact that the design did not require a follow-up study, and finally because it is relatively less costly and often representative of a population, rather than a smaller sub-population. Maternal and preterm neonatal demographics were obtained from answered self-administered questionnaire and from the folders of participants. Intracranial ultrasonography was done under strict sonographic guidelines to determine the prevalence of neuroabnormalities in the population.

3.3 STUDY SITE

The study was done at the Korle-Bu Teaching Hospital (KBTH) which has a 2000 bed capacity. The hospital's Neonatal Intensive Care Unit (NICU) serves as a national referral centre for preterm and full term neonates from all over the country. The Unit admits both preterm and full term neonates. KBTH is also the centre for research and has strict guidelines that scrutinize studies of this nature before approval is given. This made the study setting more appropriate,

compared to other health facilities in the country. The Unit offers both basic resuscitation and advanced care to high risk preterm neonates. The preterm babies are kept in incubators till they are able to withstand external life. This made the setting convenient place for this study so that any emergency situation could be curtailed easily.

3.4 SAMPLE POPULATION

The sample population of this study consisted of preterm neonates aged between 2 days to 14 days and referred to NICU of KBTH. The population did not include preterm neonates presenting with obvious neurological defects.

3.5 SAMPLE SIZE

A sample size of 120 was obtained representing about 80% of the sample population of approximately 150 per the available statistics at the NICU. Due to the choice of the cross sectional design approach for this work, all preterm neonates admitted at the NICU during the study period were purposively included. Available data at NICU indicated an average of 8-10 neonatal admissions daily, out of which 4-5 were preterm. For a sample duration of 30days, a sample size of 120 was obtained with an average of 4 neonate scans/day using the formula:

$$N = X_p t \quad 3.1$$

where X_p is the number preterm neonates scanned daily, t is sampling time and N is sample size.

3.6 SAMPLING METHOD

All prospective preterm neonates referred to the NICU during the 30 days period of the study were purposively sampled and used in the study. Legible participants were identified based on a set of inclusion and exclusion criteria.

3.7. INCLUSION AND EXCLUSION CRITERIA

3.7.1 Inclusion Criteria

All preterm neonates less than 37 completed weeks of gestation referred to the Unit were included in the study. Also, only neonates of consented mothers or caretakers were included in the study.

3.7.2 Exclusion Criteria

All preterm neonates with obvious neurological malformation (e.g. anencephaly, meningocele, encephalocele and hydraencephaly) were excluded in the study.

3.8 EQUIPMENT

A high resolution real-time mobile ultrasound machine SonoScape SSI-6000 (2012-Year of Manufacture) with dedicated settings for neurosonography and Doppler application was used. It has a sector, linear, curvilinear probes of frequency range, 2-12MHz for high resolution image. The technical specifications of the SonoScape SSI-6000 are presented in Table 3.1.

Table 3.1: Technical specifications of sonoscape SSI 6000

Types of probes and geometries	Probe/transducer frequency range
Convex	2 – 5MHz
Linear	7-12MHz
Phased array	4MHz
Transvaginal	10-12Mhz
Probe geometries	Curvilinear, linear, sector

3.9 RECRUITMENT AND SCAN PROCEDURES

Per the requirements of the inclusion criteria, recruitment of eligible participants was done at the NICU. The mothers were briefed about the study before enrollment was done. Neonates whose mothers or caretakers consented were enrolled on the day of hospital admission. Neonatal and maternal demographics were obtained through folders and questionnaire respectively. The preterm infant's age in days at the time of ultrasound examination was also recorded.

Cranial ultrasound scan was done on neonates whose mothers or caretakers consented. Every scan was done under strict aseptic technique to prevent cross infection. An alcoholic based gel with 99.9% efficacy (pharmaderm) was used for hands and probe cleaning after each scan. The gel is a potent antifungal, antibacterial and antiviral hand disinfectant. According to Llewellyn-Jones (1994), preterm neonates are susceptible to hypothermia because they have less brown fat which impairs thermoregulation. The ultrasound gel was therefore kept warm by placing it in warm water to attain a temperature similar to the neonates' environment to prevent hypothermia. A digital thermometer was used to determine the temperature of the gel.

3.10 ULTRASOUND EXAMINATION TECHNIQUE

All babies were scanned in the supine position or any other position that did not disturb the environment of the neonates. The orientation of the probes was adjusted in all circumstances in order to obtain symmetry of the cranial structures. The warm gel (35⁰C) was applied in more quantity to the fontanelle before scanning to reduce excessive exertion of pressure to brain during the scanning process.

Cranial ultrasound was performed through the anterior fontanelle of the preterm babies' lying in incubators or baby cots. A 7-12 MHz linear transducer was used to examine the superficial structures of the brain while a 4 MHz phase array transducer was used to assess deeper structures. A neuro-specific transducer/probe was used to assess the deep structure such as the cerebellum, midbrain, ventricles and periventricular structures. Both superficial and deep brain ultrasound assessment was coupled with Doppler examination of the intracranial vasculature.

The images (Fig. 3.1- 3.2) included the following anatomical structures in accordance with AIUM Practice Guidelines, 2009.

- Frontal lobe and frontal horn of the lateral ventricles.
- Caudothalamic groove and basal ganglia.
- Bodies of lateral and third ventricles.
- Cavum septum pellucidum, corpus callosum and portions of the frontal and parietal lobes.
- Temporal and occipital lobes, fourth ventricle, cerebellum and cisterna magna.

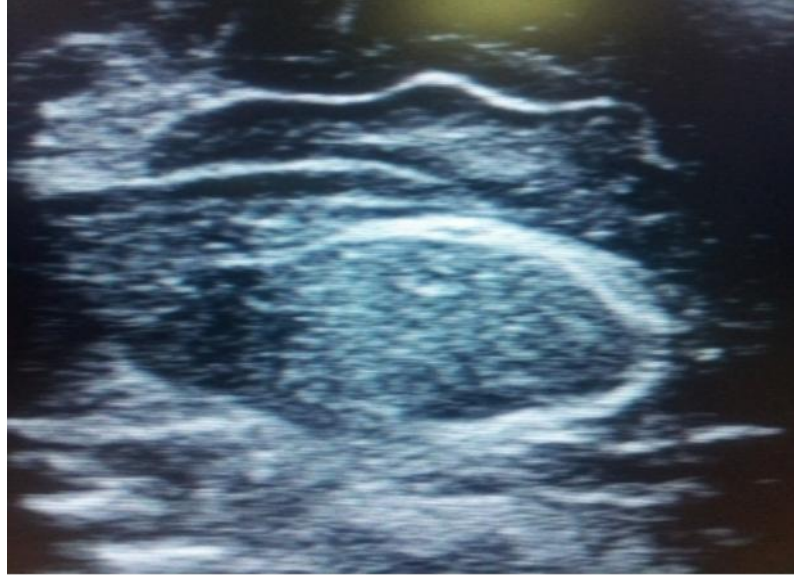

Fig. 3.1: Parasagittal image of neonatal brain (source: participant's data)

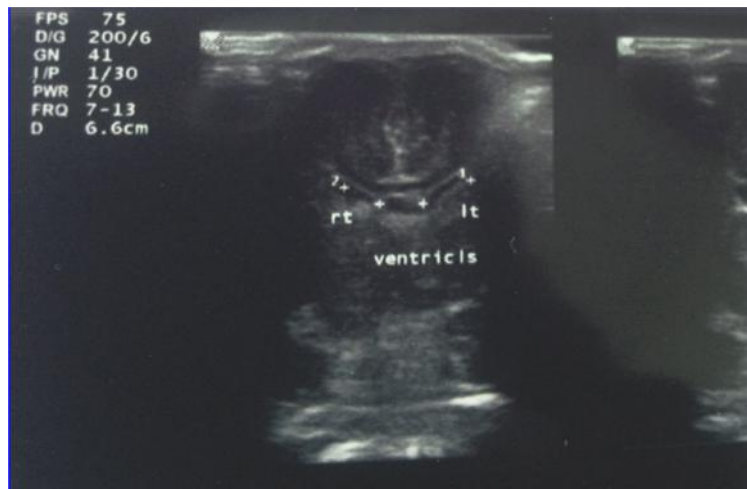

Figure 3.2: Coronal image of neonatal brain (source: participant's data)

Coronal and parasagittal scans were done and corresponding images with labels and measurements were recorded on USB devices or printed. An average of 6 scans involving 3 coronal images (frontal, middle and posterior) were taken for each preterm neonate. The sagittal images included median sagittal and two parasagittal images each for left and right lobes of the brain.

The frontal horn diameter and the atrium (the largest portion of the lateral ventricles) were measured. In the new born, up to 3mm is normal, 4-6m constitutes mild dilation, 7-10mm moderate dilation and greater than 10mm marked dilatation. The third ventricle was measured in its transverse diameter on coronal plane which must be less than 4mm in the new born, as reported by Muganga (2009). All images were assessed by a consultant radiologist to confirm the findings which were recorded on a section of the questionnaire labeled 'ultrasound findings' for analysis.

3.11 DATA MANAGEMENT AND ANALYSIS

The data collected was analysed and Odd Ratios (OR) were calculated for all maternal variables obtained during antenatal period to determine the association between preterm delivery and

development of neuroabnormality. The maternal variables included parity, preeclampsia, PROM, sickle cell disease (SCD), infection and multiple pregnancy ('twining'). Independent variables such as type of delivery, age at scan time and birth weight were also represented in tabular form with respective percentages. The prevalence of neurological abnormality was determined by dividing the total number of neonates with neurological abnormality by the total number of participants in the study.

3.12 RISK MANAGEMENT

- Endotracheal tube could get dislodged if head was moved too drastically: This was overcome by scanning gently.
- Infection can spread from one patient to another: This was overcome by cleaning hands in-between scans with an alcoholic based sanitizer; pharmaderm gel (has 99.9% capability of killing infectious pathogens). The probes were also cleaned thoroughly the same gel.
- Thermoregulation in the premature baby is poor and becomes more susceptible to hypothermia: To prevent hypothermia, the ultrasound gel was warmed by immersing a container of gel in warm water until it attained a temperature equivalent to the neonates' environment (operational temperature of the incubator) and the neonates were scanned in their cots while adequately covered.
- Pulse oxymeter was used to determine the oxygen concentration before, during and after each scan: Blood oxygen concentration was not affected in all circumstances by the scanning procedure.
- The brain could be damaged if excessive pressure was used on fontanelles: This was overcome by using gentle touch for transfontanelle scanning

- The procedure might cause thermal burns but this rarely occurs: There was no documented long term effect on neonates. The ALARA principle (As Low As Reasonably Achievable) was adopted to reduce the scan time per area to prevent heat burn.
- Participants diagnosed of neuroabnormalities were referred for paediatric management.

3.13 QUALITY ASSURANCE

The ultrasound machine was checked regularly for electrical safety and image quality assurance. High image quality was achieved by setting correct grey scale (brightness and contrast) in accordance with ultrasound guidelines. The images were reviewed by a consultant radiologist for confirmation of diagnosis. For reproducibility, the review was supported by USB storage devices.

3.14 ETHICAL CONSIDERATIONS

Ethical clearance was obtained in writing from the Ethics and Protocol Review Committee of the University of Ghana School of Allied Health Sciences. The Department of Child Health, KBTH also gave approval for the performance of the research study after formal presentation of the study and grant of SAHS ethical approval or clearance. An informed consent sheet was signed or thumb printed by mothers or caretakers prior to the study and information so obtained were be handled confidentially. A copy of the consent form was made available to consenting mothers on request.

The mothers of participants were informed of their right to withdraw from the study at any time. The participants were not subjected to discrimination and received normal attention and care as

other patients on the ward. All information solicited from preterm babies and mothers were handled confidentially. Consenting mothers were made aware that any ethical violation by the investigator could be reported to the Ethical and Protocol Committee.

CHAPTER FOUR

RESULTS

4.1 INTRODUCTION

This Chapter deals with findings of the study in respect of the stated objectives of the study. The results are presented in the form of tables and graphs, and summarized using frequencies, count, mean and standard deviation. Odd ratio was also used to determine the association of selected variables.

4.2 DEMOGRAPHICS

A sample size of 120 was obtained representing about 80% of the sample population of approximately 150. The participants consisted of 72 males and 48 females representing 60% and 40% respectively (Table 4.1). The modes of delivery Caesarian section (CS) formed 45% (54) and spontaneous vaginal delivery (SVD) represented 55% (66) of participants.

Table 4.1: Gender and modes of delivery

Demographic variable		Number of participants	Percentage %
Gender	Male	72	60.0
	Female	48	40.0
	Total	120	100.0
Mode of delivery	Caesarian section	54	45.0
	Spontaneous vaginal delivery	66	55.0
	Total	120	100.0

4.3 PREVALENCE OF NEUROABNORMALITY

A 15% prevalence rate of preterm neonatal neuropathologies in general and hydrocephalus in particular was determined in this study (Figure 4.1).

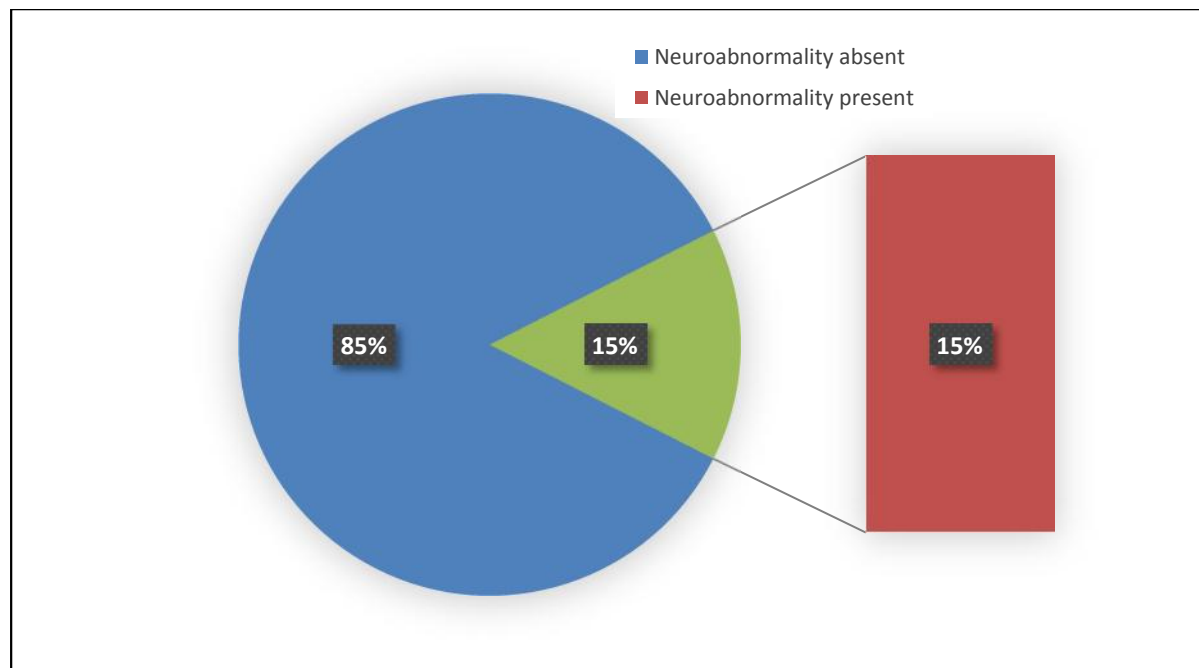


Fig. 4.1: Prevalence of preterm neonatal neuropathologies

More neonates ($n=102$, 85%) had normal brain ultrasound examination. The fewer 18 (15%) neonates were diagnosed of neuroabnormality. No other neuropathologies such as ICH, vein of Galen aneurysm VGA, CM, and PVL were found in this study.

4.3.1 Prevalence of Hydrocephalus

Hydrocephalus was sonographically detected as the neuroabnormality in the preterm neonates. The statistical distribution of the two types of hydrocephalus presented by the neonates was based on the extent of ventricular dilatation (Table 4.2).

Table 4.2: Types of hydrocephalus

Type of hydrocephalus	No. of participants	%
-----------------------	---------------------	---

Mild	12	66.7
Severe	6	33.3
Total	18	100

The location of hydrocephalus was also ascertained among the various ventricles (lateral, third and fourth ventricles) as shown below in Figure 4.2.

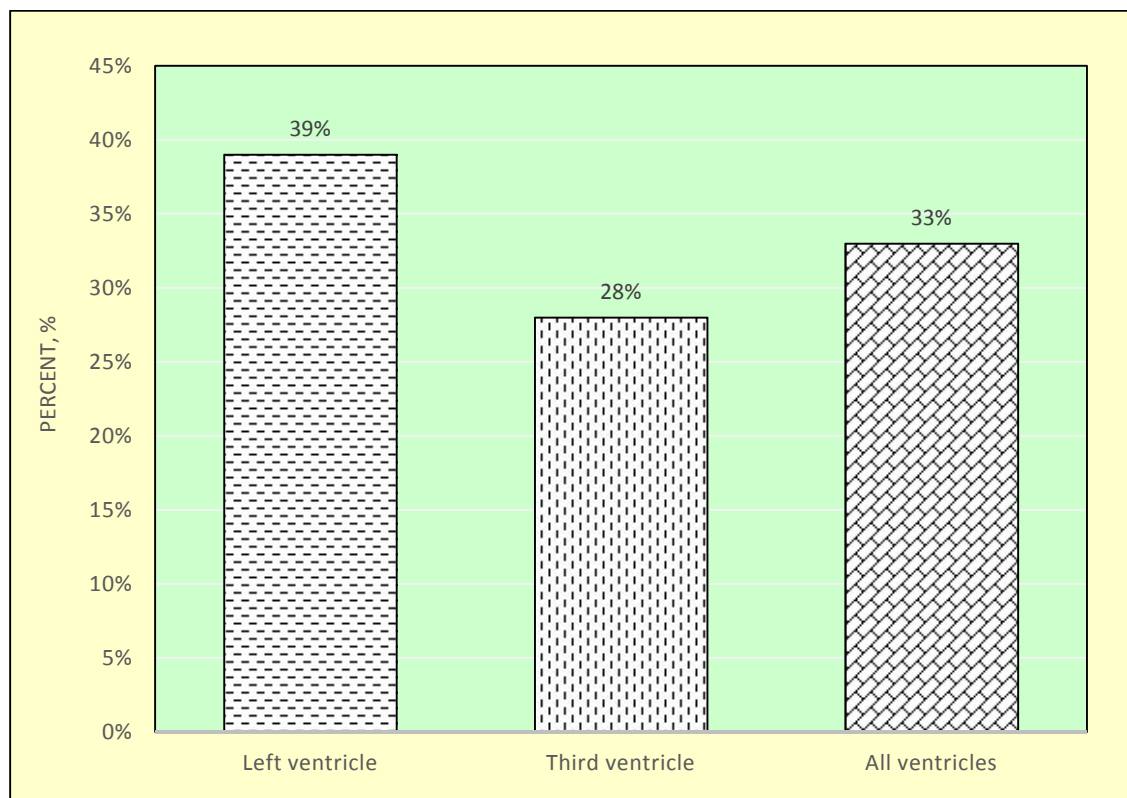


Fig. 4.2: Distribution of hydrocephalus location

Mild hydrocephalus was more prevalent (66.7%) and found in the lateral (39%) and third ventricles (28%). Severe hydrocephalus was less prevalent (33.3%) and consisted dilatation in all the four ventricles with cerebral atrophy. The contribution by all ventricles was 33%.

The frequency table of gestational age with corresponding percentages is shown in Table 4.3 below. The mean gestational age of the neonates was 30.85 ± 0.13 weeks.

Table 4.3: Gestational age/weeks at delivery

Gestational age/days at delivery	Class midpoint	Frequency	Percentage %
25-27	26	12	10
28-30	29	24	20
31-33	32	66	55
34-36	35	18	15
Total		120	100

Eighty four (84) representing 70% and 36 (30%) of participants were delivered above and below 30 weeks gestational age respectively.

Preterm neonates delivered after 30 weeks of gestation had no neuroabnormality on ultrasonography. However, all neonates diagnosed of brain abnormality were between 25-30 weeks old. Thus, the tendency of preterm neonates to suffer neuroabnormality was higher if delivery occurred below 30 weeks of gestational age. Accordingly, 100% (18) of participants diagnosed of a neuroabnormality (hydrocephalus) were delivered below 30 weeks of gestation. Six (33.3%) neonates were delivered at 25-27 weeks of gestation while 12 (67.7%) and 102 (85%) of them were born at 28-30 weeks and 31-36 weeks of gestation respectively.

The apgar score for participants diagnosed of neuroabnormality presented in Table 4.4. The 1-minute apgar score for participants diagnosed of cerebral abnormality showed that 7 (38.9%) premature newborns scored 2 while 11 (61.1%) preterm neonates scored 3. The 5-minutes apgar

score also recorded 8 (44.4%) and 10 (55.6%) participants scoring 2 and 4 respectively. Thus, the mean apgar score for 1 and 5-minutes were 2.5 and 3 respectively. The apgar score for participants without neuroabnormality is also shown in Table 4.4.

Table 4.4: Apgar score for participants diagnosed of neuroabnormality and participants without neuroabnormality.

Neuroabnormality	Time	No. of participants	Score	Percent, %
		7	2	38.9
Presence of neuroabnormality (<i>n</i> =18)	1 min	11	3	61.1
	5 mins	8	2	44.4
		10	4	55.6
		60	6	58.2
Absence of neuroabnormality (<i>n</i> =102)	1 min	42	6	41.2
		22	7	21.6
	5 mins	80	8	78.4

The 1-minute apgar score for participants diagnosed of cerebral abnormality showed that, 7 (38.9%) premature newborns scored 2 while 11(61.1%) preterm neonates scored 3. The 5-minutes apgar score also recorded 8 (44.4%) and 10 (55.6%) of participants scoring 2 and 4 respectively. Hence the mean apgar score for 1 and 5-minutes were 2.5 and 3 respectively.

The 1-minute apgar score of participants without cerebral abnormality showed that, 60 (58.8%) premature newborns scored 6 while 42(41.2%) preterm neonates scored 7. The 5-minutes apgar score also recorded 22 (21.6%) and 80 (78.4%) of participants scoring 7 and 8 respectively. Hence

the mean apgar score for 1 and 5-minutes among participants with normal ultrasound scan of the brain were 6.5 and 7.5 respectively. All neonates diagnosed of a neuroabnormality (hydrocephalus) were delivered below 30 weeks of gestation. In particular, 6 (33.3%) participants were delivered at 25-27 weeks of gestation. Also, 12 (67.7%) preterm neonates were born at 28-30weeks of gestation. Premature neonates delivered at 31-36weeks of gestation were 102 (85%).

The study also showed the distribution of predisposing factors of preterm delivery as depicted in the chart (Figure 4.3).

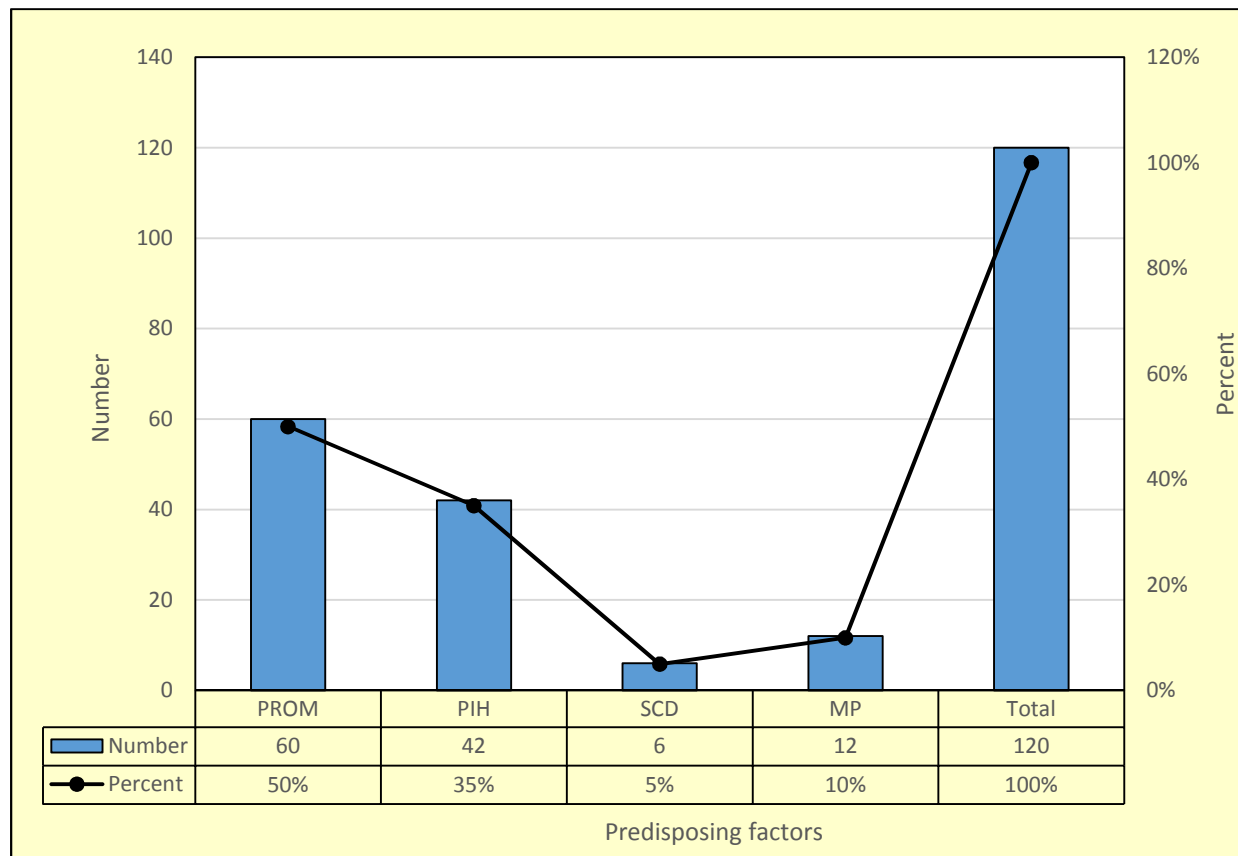


Figure 4.3: Distribution of predisposing factors of preterm delivery

Statistically, the study investigated the association or relationship between the predisposing factors of premature delivery and the development of neuroabnormalities. As seen in Table 4.5,

the Odd Ratio (OR) at 95% confidence level calculated for PIH, SCD and MP were < 1 which indicated no association with neuroabnormality.

Table 4.5: Association between PROM and development of neuroabnormality via Odd Ratio

Predisposing factors		Odd Ratio		
PROM		6.33 > 1		
PIH		0.20 < 1		
SCD		0.00 < 1		
MP		0.00 < 1		
Exposure to RROM				
	Neuroabnormality present	Neuroabnormality absent	Total	
Exposed to PROM	15	45	60	
Unexposed to PROM	3	57	60	
Total	18	102	120	

The only association was established between PROM and development of neuroabnormality where a 6.33 > 1 OR was estimated.

4.3.2 Birth Weight Distribution

The frequency distribution of the participants' birth weight are represented in Figure 4.4. The birth weight of participants ranged from 0.5kg to 2.1kg. The mean birth weight of participants

was $1.22 \pm 0.13\text{kg}$. The mean birth weight of neonates delivered at gestational age of 25 weeks to 30 weeks was $0.87 \pm 0.11\text{kg}$. The mean birth weight of neonates delivered at older gestational ages (31-36 weeks) was higher at $1.66 \pm 0.36\text{kg}$, and no neuroabnormalities were detected in neonates born at this age range.

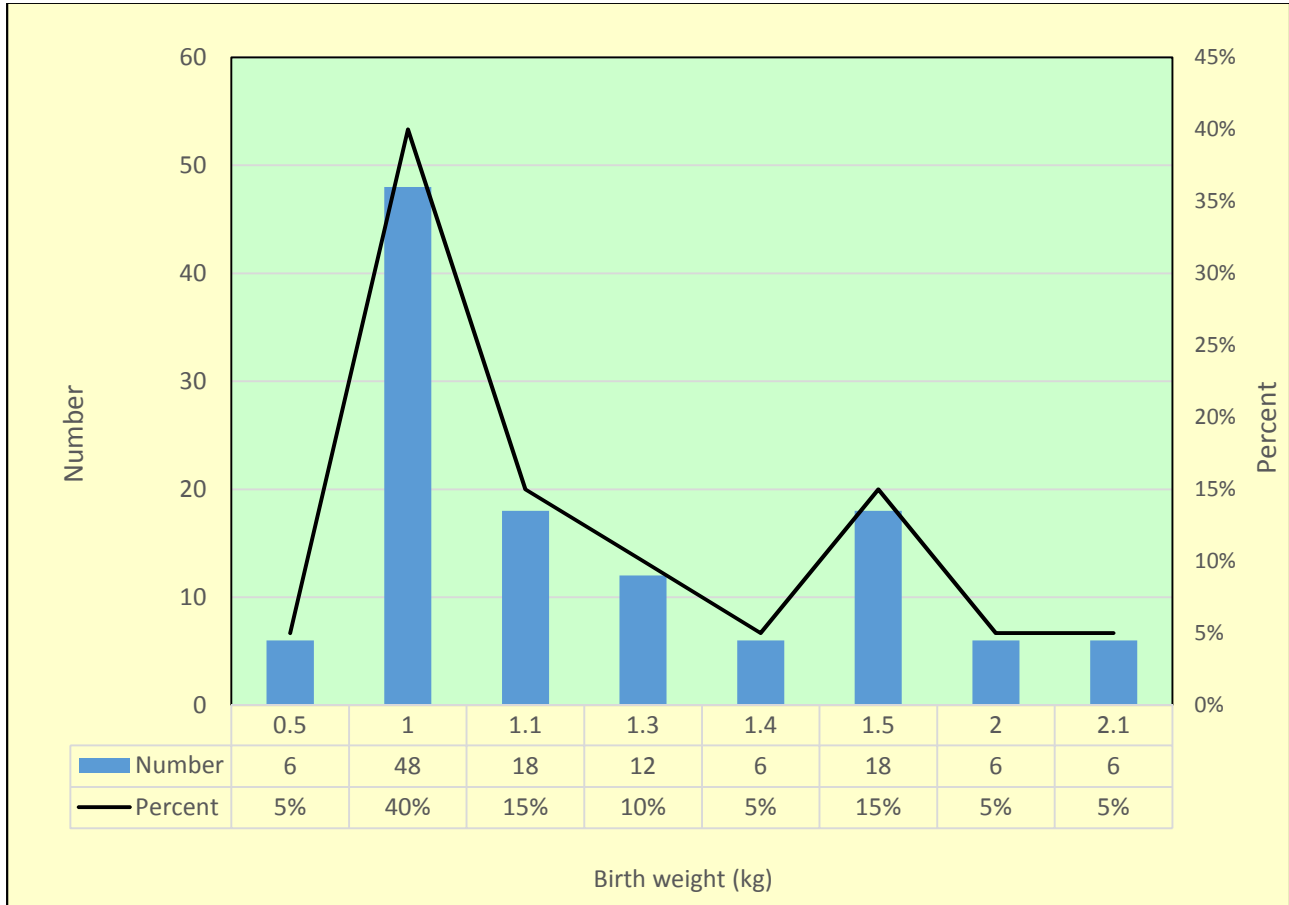


Fig.4.4: Frequency variation of neonates' birth weight

In general, it was observed that the lower the gestational age at delivery, the smaller the birth weight and greater the chances of developing neuroabnormalities.

The neonatal age at scan time were varied from age 2-14days. The median age of participants at scan time was 7 days. The age distributions at scan time presented in Table 4.7 showed that 30 (25%) preterm neonates were scanned within the first 3 days of life, while 57 (47.5%) were scanned from 4 to 7 days of neonatal life, and 33 (27.5%) examined from day 8 to 14.

Table 4.6: Distribution of neonatal age at scan time

Age (days) at scan time	Frequency	Percentage %
2	24	20
3	6	5
4	15	12.5
5	6	5
6	12	10
7	24	20
8	7	5.8
9	5	4.2
10	3	2.5
13	6	5
14	12	10
Total	120	100

More neonates ($n=60, 72.5\%$) neonates were scanned within the first 7 days of neonatal life.

4.3.3 Maternal Demographics Distribution

The distribution of maternal age (years) of consenting mothers is shown in Table 4.8. The mean maternal age was 27 ± 7 years. Teenage mothers constituted 20% of the population while 106 (80%) were aged over 20 years. The largest population of mothers were aged 30-34 years. The level of education of consenting mothers were analysed in the study. The results (Table 4.9) indicated that majority ($n=53$, 44.2 %) were primary school graduates while 36 (30%) and 12 (10%) had education at the secondary and tertiary levels respectively. Mothers with non-formal education were 19 (15.8%). The educational demographics however had no bearing on the outcome of this study.

Table 4.7: Distribution of maternal age and levels of education

Age/years	Class midpoint	Number of participants	Percentage %	
15-19	17	24	20.0	
20-24	22	23	19.2	
25-29	27	25	20.8	
30-34	32	29	24.2	
35-39	37	19	15.8	
Total	135	120	100	
Levels of education				
	Non-formal	Primary	Secondary	Tertiary
Number	19	53	36	12
Percentage, %	15.8	44.2	30.0	10.0

The statistical distribution of the maternal parity is shown in Table 4.9

Table 4.8: Maternal parity distribution table

Parity	Frequency	Percentage %
1	48	40
2	24	20
3	25	20.8
4	23	19.2
Total	120	100

From Table 4.9, 40% of consenting mothers had single parity and 20% had two. Mothers presenting a parity of 4 were the least ($n=23$, 19.2%). None of the participating mothers had a history of any infection during the antenatal period as was determined by the self-administered questionnaire. Though infection is known to be a risk factor in preterm delivery, its association with neuroabnormality in premature neonates could not be established in this study.

CHAPTER FIVE

DISCUSSION

5.1 INTRODUCTION

This Chapter deals with detailed explanation of the study findings in respect of the stated objectives. The discussions are presented in relation to the findings of previous studies and what pertains in this study.

5.2 DEMOGRAPHICS

A sample size of 120 (80%) was obtained from a sample population of 150. The participants consisted of 72 (60%) males and 48 (40%) females and respectively as shown in (table 4.1). The Caesarian section (CS) mode of delivery formed 45% ($n=54$) and spontaneous vaginal delivery (SVD) represented 55% ($n=66$) of participants.

The study highlighted some important findings which included 15% prevalence of neuroabnormalities in preterm babies. This agreed with the indications of Beck *et al*, (2009) that premature neonates are more susceptible to neuroabnormalities. The observation that hydrocephalus formed 100% of ultrasonographically detected abnormalities is contrary to other studies (Muganga, 2009) which showed 17% prevalence of haemorrhage in preterm infant. The lateral and the third ventricles formed 67% and 33% of hydrocephalus location respectively among participants. The study also found an association between PROM at preterm and the presence of neuropathology in the premature newborn though the strength of relationship was not determined. Finally, it was found out that 100% (18) of preterm babies diagnosed of neurological abnormality were delivered below 30 weeks of gestation and had mean birth weight of 0.87 ± 0.11 kg compared to 1.66 ± 0.36 kg birth weight for premature neonates delivered

beyond 30weeks. According to Beck *et al*, (2011) preterm neonates delivered below 37 completed weeks have high rate of developing neurological defects including hydrocephalus.

5.3 PRESENCE OR ABSENCE OF NEUROABNORMALITY

The presence of a structural neurologic defect as determined by ultrasound imaging in 15% of the participants (in this study) may result in permanent or temporal physical disabilities such as impaired vision, hearing, motor functions, etc depending on the extent of damage to the cerebral parenchyma. On the other hand, Willacy (2010) has argued that the absence of a cerebral abnormality does not guarantee total freedom from future defects. This finding is suggestive that the 85% defect-free neonates detected via cranial ultrasonography will require monitoring on regular basis to identify or rule-out possible future abnormalities such as hydrocephalus. Routine clinical and ultrasonographic assessment may be adopted as regular monitoring mechanisms. The 67% of participants diagnosed of mild hydrocephalus may progress to severe hydrocephalus if the causative agent persists. For example, choroid plexus carcinoma causing over production of cerebrospinal fluid (CSF) may result in unresolved hydrocephalus if no intervention is made over a period of time. Also, occlusion of the CSF circulatory foramina (aquiduct of Sylvius, foramen of Luschka and foramen of Magendie) may cause persistent hydrocephalus. It may also be resolved such that normal ventricular images may be obtained in future ultrasound or other imaging modalities such as CT scan and MRI.

5.4 HYDROCEPHALUS

Hydrocephalus is the dilation of the cerebral ventricles due to CSF accumulation of in the ventricles, which according to NINDS (2013) and Carey *et al.*, (1994), the balance between production and absorption of CSF is critically important to maintain optimum ICP. Generally, infants have cranial bones that are not fused at the sutures at birth and hence any ICPs resulting from CSF accumulations will result in commensurate expansion of the cranial cavity to accommodate its contents. In this study, neonates diagnosed of hydrocephalus ($n=18$) were likely to undergo similar pathophysiological processes.

Until the completion of this research study, no available data showed the prevalence rate of hydrocephalus in preterm babies using ultrasound imaging in Ghana. The 15% prevalence of hydrocephalus in preterm babies established in this study is relatively higher compared to 0.05% - 0.08% reported in certain European countries and the USA (Hydrocephalus Up-to-date, 2013). The result is however lower in respect of the 20% determination by Sajjadian *et al.*, (2011) where weekly ultrasound examination of participants' brains were made for year, contrary to a one-time neurosonographical examination in this study. As reported in the published literature, a high prevalence of more than 6000 new cases of infant hydrocephalus have been estimated annually in East Africa (Warf BC & East African Neurosurgical Research Collaboration, 2010).

All the participants diagnosed of neurological defect suffered hydrocephalus in mild (67%) and severe (33%) forms. In mild hydrocephalus where the lateral ventricular diameter at the atrium is $>4\text{mm}$ and $<7\text{mm}$, any of the four ventricles may be dilated depending on the site of blockage if the cause is obstruction. According to Hakim *et al.*, (1976), the intracranial pressure (ICP) may not be so significant to cause any neurological dysfunction. However, moderate increase in ICP may result in mental changes. Irrespective of the CSF roles, the 33% premature neonates

diagnosed of severe hydrocephalus (diameter of lateral ventricular at the atrium >10mm) in this study presented with deteriorating vision and motor functions as a result of cerebral atrophy.

Over production of CSF by the choroid plexus can also result in hydrocephalus. Gopal *et al.*, (2008) have reported that choroid abnormalities such as papilloma/carcinoma may trigger excessive synthesis of CSF beyond the normal capacity of the ventricles. Occlusion of the foramina of Lushka by a choroid plexus carcinoma may result in hydrocephalus, and defective control system for CSF production could also lead to persistent positive feedbacks such that regulation of CSF synthesis becomes virtually non-existent. However, the results of this study showed that the choroid plexus in the hydrocephalus-diagnosed participants were found to be sonographically normal even though the CSF synthetic control mechanisms could not be assessed to determine the presence or otherwise of a defect. In particular, the 39% of hydrocephalus found in the lateral ventricles could be explained by the fact that the choroid plexus responsible for CSF production is found mainly at the lateral walls of lateral ventricles of the brain. In particular, any total or partial occlusion of the cerebral aqueduct of Sylvius results in dilatation of the ventricles (Hydrocephalus-Up To Date, 2013)

Intraventricular haemorrhage (especially in the lateral ventricles) is also known to cause hydrocephalus (Muganga, 2009; Sajjadian *et al.*, (2011). This study however showed that no detections of ICH. This is because the optimal timing for periventricular or intraventricular haemorrhage in the preterm, according to Rumack *et al.*, (1985) is 3 to 7 days with a follow up scan at 14 days. Accordingly, it can deduced from the results of this study that 27.5% of premature neonates were scanned after 7th day of life. In particular, since ICH mostly occurs in the first 3 days of life in preterm neonates it might have resolved before the scans were done

after the optimum occurrence period, if detected, In another scenario, the scans might have been done prior to the occurrence of ICH. It was observed that 67% ($n=12$) of the neonates diagnosed of hydrocephalus were scanned after the optimal scan time (3 to 7 days of life) for preterm neonates. This might be as a result of complicated subependymal haemorrhage leading to hydrocephalus. Thus, it is likely to detect hydrocephalus sonographically in preterm neonates if the brain examinations are done after 7 days of the neonate's life.

5.5 DELIVERY AT LOW GESTATIONAL AGE

From the study, 70% ($n=84$) and 30% ($n=36$) of preterm neonates were delivered above and below 30 weeks of gestational age respectively while 50% ($n=18$) out of the 36 neonates delivered at gestational age below 30 weeks were diagnosed of hydrocephalus. However none of the preterm neonates delivered above 30 weeks was diagnosed of any neuroabnormality. The study further established a conceptual relationship which showed that lower gestational ages at delivery presented with a higher likelihood of detecting cerebral abnormality (hydrocephalus) in preterm neonates. Thus, premature delivery 30 weeks are more likely to develop neuroabnormalities.

5.6 BIRTH WEIGHT AND APGAR SCORE OF PARTICIPANTS

In this study the mean birth weights of participants delivered at gestation age 25 to 30 weeks and 30 and beyond were $0.86 \pm 0.11\text{kg}$ and $1.66\text{kg} \pm 0.36\text{kg}$ respectively. These values are consistent with the findings of Mack *et al.* (1981) that low birth weight (less than 1500 grams) neonates are susceptible to ICH and this normally occurs 32 weeks of gestation. Hence, this study affirms that low birth weight ($<1\text{kg}$) neonates are prone to neuroabnormalities in general and hydrocephalus in particular. Furthermore, the concept that lower birth weights are associated

with lower apgar scores and higher tendencies of developing cerebral abnormality/hydrocephalus as observed in this study are confirmed by Mack *et al.* (1981).

5.7 PREDISPOSING FACTORS FOR PRETERM DELIVERY

According to Muganga (2009) many predisposing factors for preterm delivery and corresponding cerebral complications include infection, SCD, multiple pregnancy (twin gestation), PROM and PIH. A study among African-American women showed that the presence of sickle cell trait was associated with preterm delivery (Bryant *et al.*, 2007), while Hillier *et al.*, (1995) earlier reported the association of bacteria with preterm delivery (Hillier *et al.*, 1995). However, previous studies did not link any of these predisposing factors to any form of cerebral abnormality on sonographic imaging. On the contrary, the 6.33 OR estimated in this study showed an association between PROM and neuroabnormality/ hydrocephalus.

5.8 PREMATURE RUPTURE OF MEMBRANES

PROM is the rupture of chorioamniotic membrane before the onset of labour (ACOG, 1998), and it is the leading cause of preterm delivery. It is called preterm and designated as pPROM if it occurs before 37 completed weeks of gestation (ACOG, 1998). According to the literature, pPROM is generally present in about 1% of all pregnancies and found to be associated with 30 to 40% of preterm delivery. This study established that 50% of preterm neonates suffered pPROM resulting in premature delivery by either CS or SVD. It is however in sharp contrast with the 2.8% pPROM prevalence rate reported in a study by Smith *et al.*, (2005).

CHAPTER SIX

CONCLUSION, RECOMMENDATIONS AND LIMITATIONS

6.1 INTRODUCTION

The prevalence of neuroabnormalities in preterm neonates using ultrasound imaging was studied at the NICU of KBTH. The study was aimed at determining the prevalence of neuroabnormalities in premature newborns which required a determination of the prevalence of neurological abnormalities related to preterm neonate using ultrasonography, identification of the regions within the brain where these abnormalities mostly occurred, ascertaining the gestational age at delivery in which these abnormalities are predominant, and finally identification of predisposing factors related to cerebral abnormalities of preterm neonates.

6.2 CONCLUSION

In respect of the study objectives, a 15% prevalence of neuroabnormalities in preterm babies was established by this study, although other defects such as ICH, PVL, CM, were not detected. The main neuroabnormality detected via ultrasonography was hydrocephalus which constituted 100% of cerebral abnormality. The lateral and the third ventricles constituted 67% and 33% of hydrocephalus locations respectively among the participants.

The study also established an association between PROM at preterm and the presence of neuropathology generally and particularly hydrocephalus in premature newborns (OR=6.33>1). This may be due to the reduction or absence of collagen in chorioamniotic membrane and single epithelial layer of the cerebral vasculature found mostly in the germinal matrix of the preterm neonates. The assumption is that, rupture of blood vessels in the germinal matrix of the unborn baby, triggers preterm rupture of chorioamniotic membranes leading to premature delivery

though the actual pathophysiological processes are not yet understood. Records established that ICH could occur in-utero hence the tendency of post-haemorrhagic hydrocephalus could better explain the relationship between pPROM and hydrocephalus in the “born-too-soon babies”.

Finally, the study concludes that 100% of the preterm babies diagnosed of neurological abnormality via ultrasonography were delivered below 30 weeks of gestation with mean birth weight of 0.83 ± 0.11 kg compared to 1.66 ± 0.36 kg birth weight for premature neonates delivered beyond 30weeks. Also, the mean apgar score at 1 and 5-minutes for the hydrocephalus neonates were 2.5 and 3 respectively which were below average with the maximum score of 10. The mean apgar score for neonates with ventricular dilatation were above average, recording 6.5 and 7.5 for 1 and 5-minutes respectively. Thus, it can be concluded that premature babies born at 30 weeks of gestation have low apgar score and extremely low birth weight, and hence more susceptible to neuroabnormalities or hydrocephalus specifically as determined in this study.

6.3 LIMITATIONS OF THE STUDY

- Due to time constrain in performing the study, sonographical examinations were performed once without follow up. Hence adoption of a cohort study design may improve the accuracy of the study.
- Perinatal laboratory and other clinical records for the mothers were not sufficient, resulting in loss of significant information were missed.

6.4 RECOMMENDATION

Consequent to the observations and outcomes of associated with this work, the following recommendations are suggested

- A neuro-specific ultrasound imaging equipment dedicated to providing ultrasonographic imaging of neonates at NICU of Korle-Bu Teaching Hospital may be deployed to help early diagnosis of any cerebral abnormality.
- A follow up study is required to assess the progress of participants diagnosed of brain defects.
- Training of pediatric neurosurgeons may help reduce cerebral defects such as hydrocephalus. This is because earlier surgical intervention can be done to prevent complications. Currently, hydrocephalus in preterm neonates can only be surgically corrected after such newborns are over a year old, a procedure which could be done just early if expertise is available.
- Inclusion of perinatal laboratory findings and vital clinical information of mothers in neonates' folder may help to improve the reliability of maternal demographics obtained in future studies.
- Routine neuroscan for all preterm neonates may be adopted by the NICU.
- A qualified sonographer may be stationed at the NICU to routinely examine the brain of all preterm neonates.

REFERENCES

Allan WC, Roveto CA, Sawyer LR, Courtney SE, (1980). Sector scan ultrasound imaging through anterior fontanelles. www.earlyhumandev.com/article/0378...4/references

Alonso M, Borenstein M, Grant G, Narbona I, Azumendi G. (2010). Depth of brain fissures in normal fetuses by prenatal ultrasound between 19 and 30 weeks of gestation. Available at www.wileyonlinelibrary.com

American College of Obstetricians and Gynecologists (ACOG); Premature rupture of membranes; Technical Bulletin.No.115.April 1998.

American Institute of Ultrasound in Medicine (2009). American Institute of Ultrasound in Medicine (AIUM) guidelines for neurosonography, Resolution18

Bachrach SJ. (2012); Cerebral palsy. Available at www.KidHealth.org

Beck, S. Wojdyla, D. Say, L. Betran, P. Merialdi, M. Requejo, JH. Reubens, C. Menon, R. & Van Look PFA. (2009). Worldwide incidence of preterm birth: a systematic review of maternal mortality and morbidity. Available at www.who.int/bulletin/volumes/88/1/08-062554/en/-57k.

Bryant AS, Cheng YW, Lyell DJ, Laros RK, Caughey AB; Presence of sickle cell trait and preterm delivery among African-American women; *Obstetric & Gynecology*, 2007; April;109 (4):870-4.

Carey CM, Tullous MW, Walker MI: Hydrocephalus: Etiology, Pathologic Effects, Diagnosis and Natural History. Pediatric Neurosurgery. 3ed, Cheek WR (Ed), 1994

Chau V, Poskitt KJ, McFadden DE, Bowen-Roberts T, Synnes A, Brant R, Sargent MA, Soulikias W & Miller SP. (2009). Effects of chorioamnionitis on brain development and injury in the premature newborns. Available at www.ncbi.nlm.gov/pubmed/19743455

Clair MR, Zalneraitis EL, Baim RS, Goodman K, Perkes EA. (1984). *Neurosonographic Recognition of Subependymal Cysts in High-Risk Neonates*. Available at www.ajronline.org

Correa F, Lara C, Bellver J, Remohi J, Pellicer A, Serra V. (2006). Examination of the foetal brain by transabdominal three-dimensional ultrasound: potential for routine neurosonographic studies; Accessed from www.interscience.wiley.com.

Gopal P, Parker JR, Debski R & Parker JC: Choroid plexus carcinoma; Archives of pathology and laboratory medicine, August, 2008; Vol 132. No.8, pp.1350-1354.

Hakim S, Venegas JG, Burton JD: The physics of the cranial cavity, hydrocephalus and normal pressure hydrocephalus: mechanical interpretation and mathematical model. *Surgical Neurology* 1976, 5(3): 187-210.

Hillier SL, Nugent RP, Eschenback DA, Krohn MA, Gibbs RS, Martin DH, Cotch MF et al: Association between Bacterial Vaginosis and Preterm Delivery of a Low-Birth-Weight Infants; *English Journal of Medicine*; December 28, 1995; 333:1737-1742.

Hydrocephalus-Up To Date, 2013, Available at www.uptodate.com/.../hydrocephalus.

Judy LL, Broyles RS, Pritchard MA and Engle WD. (2003). The Value of Neurosonography in Predicting Subsequent Cognitive and Motor Development in Extremely Low Birth Weight Neonates, *Journal of Perinatology*, 23:629-634.

Kumazaki K, Nakayama M, Sumida Y, Ozono K, Mushiake S, Suehara N, Wada Y, Fujimura M. (2002). Placental features in preterm infants with periventricular leukomalacia. Available at www.ncbi.nlm.nih.gov/pubmed/11927710.

Lewis and Chamberlain (1990). *Obstetrics by ten teachers*, 15th Ed., page 298.

Llewellyn-Jones, D (1994). *Obstetrics and Gynaecology*, 6th Ed. Chapter 28, page 201

Mack LA, Wright K, Hirsch JH, Alvord EC, Guthrie RD, Shuman WP, Rogers JV & Bolender NF. (1981). Intracranial Haemorrhage in preterm infants: accuracy of sonographic evaluation. *American Journal of Radiology*, 137:245-250

Malinger G, Ben-Sira L, Lev D, Ben-Aroya Z, Kidron D, Lerman-Sagie T. (2004). Fetal brain imaging: a comparison between magnetic resonance imaging and dedicated neurosonography. Available at www.interscience.wiley.com

Muganga, P (2009). Prevalence of Intracranial Haemorrhage at Cranial Ultrasound among Neonates in Special Care Unit at Mulago Hospital. Available at: www.docs.mak.ac.ug/.../Main20%.

National Institute of Neurological Disorders and Stroke (NINDS, 2013). “Chiari malformation Fact Sheet, Publication No. 13-4839

Parry S, Strauss JF; Premature rupture of fetal membranes. Available at <http://www.nejm.org/doi/full/10.1056/NEJM199803053381006>.

Perlman, J.M (1996). Bilateral cystic periventricular leukomalacia in the preterm infant: associated risk factors. Available at: www.ncbi.nlm.nih.gov/m/pubmed/8657521/?i=3&from=/11927710/related

Pidcock FS, Graziani LJ, and Stanley C. (1990), Neurosonographic features of periventricular echodensities associated with cerebral palsy: www.ncbi.nlm.gov/pubmed/2407818.

Queensland Maternity and Neonatal Clinic Guidelines (2011). Neonatal resuscitation; Available at <http://www.health.gld.gov.au/qcg>

Rizzo G, Capponi A, Pietrolucci ME, (2011). An algorithm based on OmniView technology to reconstruct sagittal and coronal planes of the foetal brain from volume data sets acquired by three-dimensional ultrasound. Accessed from www.wileyonlinelibrary.com.

Romosán G, Henriksson E, Rylander A, Valentin L. (2009). Diagnostic performance of routine ultrasound screening for foetal abnormalities in an unselected Swedish population in 2000-2005, Accessed from www.interscience.wiley.com

Rumack C M , Manco-Johnson M L, Manco-Johnson M J, Koops B L , Hathaway W E and Appareti K; Timing and course of Neonatal Intracranial Haemorrhage Using Real-time ultrasound. *Radiology* 1985;154:101-105

Sajjadian N, Fahhrai H, JahadiR: Incidence of intraventricular hemorrhage and post hemorrhagic hydrocephalus in preterm infants. *Acta medica Iranica* 48 (4); 260-2.

Sherman, N.H, Rosenberg H.K (1994). *Ultrasound Essentials for imaging neonatal brains*, Diagnostic Imaging 1994;16:108-115

Smith G, Rafuse C, Anand N, Brennan B, Connors G, Crane J, Fraser W... & Walker M: Prevalence, management, and outcomes of preterm prelabour rupture of membranes of women in Canada. Available at <http://www.ncbi.nlm.nih.gov/m/pubmed/16100631/>

Steneva KN, Muller M, Plath C, Bartolomaeus G, Uhlemann M, (1997). Ultrasound and clinical studies of periventricular leucomalacia in high risk newborns II. Perinatal risk factors. Available at www.ncbi.nlm.nih.gov/m/pubmed/9173766/?i=1&from=/9173766/related

Warf BC & East African Neurosurgical Research Collaboration; Pediatric hydrocephalus in East Africa: prevalence, causes, treatments, and strategies for the future; *World Neurosurgery*; 2010, April; 73(4): 296-300.

Whitaker, AH. (2011). Neonatal head ultrasound abnormalities in preterm infants and psychiatric disorders. Available at: <http://archpsyc.jamanetwork.com/Mobile?article.aspx?articleid>

Willacy, H. (2010). Premature babies and their problems, Available at www.patient.co.uk/doctor/premature

World Health Organisation (2012). Born too soon: the global action report on preterm birth,
Available at www.who.int/maternal.../born_too_soon/

World Health Organisation (2012). Newborns: reducing mortality, Fact sheet N*333;
Available at www.who.int/mediacentre/.../fs333/

.
Xu L.P, (2012). Effects of chorioamnionitis on brain injury in preterm infants, [http://
www.ncbi.nlm.nih.gov/m/pubmed/22989433/?i=4&from=/11927710/related](http://www.ncbi.nlm.nih.gov/m/pubmed/22989433/?i=4&from=/11927710/related)

**Prevalence of Neuroabnormalities in Preterm Neonates; a Study using Ultrasonography
at the Korle-Bu Teaching Hospital.**

Purpose of the study

The purpose of the study is to find out how many preterm neonates at the NICU suffer one form of neurological defect or the other. This will help in the management of cases if diagnosed early. This study will further enhance the use of sonography in the detection neurological defects in neonates.

Study procedure

A mobile ultrasound machine will be transferred to NICU of KBTH where scanning of the neonates will be done. Cranial ultrasound will be done on the recruited neonates under aseptic practice. The ultrasound gel will be warmed to attain a temperature similar to the environment of the neonate to prevent hypothermia in the neonates. The neonates will be scanned in the supine position or any position that deemed convenient to neonate by the investigator.

Risk to the patient

The procedure can cause thermal burns but these rarely occur. There no documented long term effect to the neonates.

Patient's right

The patient has the right to withdraw from the study at any time. The patient will receive the normal treatment as other patients on the ward. The patient will not pay for the examination throughout the period of the study. Any ethical violation by the investigator can be reported to the SAHS Ethics and Protocol Committee, College of Health Sciences, University of Ghana.

APPENDIX III: CONSENT FORM

I------(participant and or the next of kin) understand that am been asked to take part in the study to determine the prevalence of neurological defects in preterm neonates with sonography at the Korle-bu Teaching Hospital.

I have been informed that by joining this study, my child will not be exposed to any risk and will be managed exactly like non participants.

I am free to with to withdraw my consent at any time. All information obtained from me will be treated confidentially. I understand that by signing this sheet I have given my informed consent and the information obtained from this investigation will be used in this study. A copy of this form is available to me on request.

Signature/ thumb print of participant or next of kin

Witnessed by-----

Signature of investigator-----

Date-----

APPENDIX IV: QUESTIONNAIRE

SECTION A: MATERNAL DEMOGRAPHICS

1. Maternal tribe (-----). State as appropriate.
2. Age 16-20 () 20-25 () 26-30 () 31-35 () 36-40 () 41-45 () 46-50 ()
(Tick as appropriate)
3. Educational level: none () JHS () SHS () College () 1st Degree () 2nd Dgree ()
3rd Degree ().
4. Parity 1 () 2 () 3 () 4 () 5 () 6 () 7 () specify ()
5. Maternal HIV status: reactive () non reactive () don't know ()
6. Maternal HBsAg status: reactive () non reactive () don't know ()
7. Any maternal infection during prenatal period? Yes () No ()
8. If the answer for question 7 is "Yes", specify the infection.....
9. State any history of non-communicable disease(s) eg, PIH, Diabetes, Hypertension etc----

SECTION B: FOETAL DEMOGRAPHICS

1. Gestational age in weeks at delivery: 28-30 () 31-33 () 34-36 ()
2. Mode of delivery: caesarian section () vaginal ()
3. Foetal weight at delivery ----- Weight at scan time-----
4. Apgar score in 1minute----- 5minutes-----

5. Any resuscitation just after delivery? Yes () No ()
6. If the answer to question 4 is “Yes”, specify what was done-----
7. Is the neonate having any physical defect? Yes () No ()
8. If the answer to above question is Yes, then specify the defect-----

SECTION C: NEUROSONOGRAPHIC FINDINGS

1. Age in days of the neonate at which the sonographic examinations is done?-----
2. Number of images taken? -----
3. Diameter of anterior horn of lateral ventricles: Left----- Right-----
4. Third ventricular diameter-----
5. Neurosonographic findings: Normal scan() Abnormal ()
6. If abnormal state the specific abnormality-----
7. State the location of the abnormality-----
8. If haemorrhage, state the grade-----
9. If CM state the type-----
10. Specify any other finding (s)-----

APPENDIX V

**SCHOOL OF ALLIED HEALTH SCIENCES
COLLEGE OF HEALTH SCIENCES
UNIVERSITY OF GHANA
ACADEMIC AFFAIRS**

**Phone: +233-0302-687974/5
Fax: +233-0302-688291**

**My Ref. No. SAHS/ 10434066
Your Ref. No.**



P. O .Box KB 143
Korle Bu
Accra
Ghana

2nd April, 2014.

Mr. Jonathan Kelvin Semetey,
Dept. of Radiography,
SAHS,
Korle Bu.

Dear Mr. Semetey,

ETHICS CLEARANCE

Ethics Identification Number: SAHS – ET. /10434066/AA/1A/2013-2014.

Following a meeting of the Ethics and Protocol Review Committee of the School of Allied Health Sciences held on Monday 24th March, 2014, I write on behalf of the Committee to approve your research proposal as follows:

TITLE OF RESEARCH PROPOSAL: "Prevalence of Neuroabnormalities in Preterm Neonates: A Study Using Ultrasonography at Korle-Bu Teaching Hospital"

This approval requires that you submit six-monthly review reports of the protocol to the Committee and a final full review to the Committee on completion of the research. The Committee may observe the procedures and records of the research during and after implementation.

Please note that any significant modification of the research must be submitted to the Committee for review and approval before its implementation.


You are required to report all serious adverse events related to this research to the Committee within seven (7) days verbally and fourteen (14) days in writing.

As part of the review process, it is the Committee's duty to review the ethical aspects of any manuscript that may be produced from this research. You will therefore, be required to furnish the Committee with any manuscript for publication.

Please always quote the ethical identification number in all future correspondence in relation to this protocol.

Thank you.

Yours sincerely,



Dr. Michael Mark Addae
(Chairman, Ethics and Protocol Review Committee)

cc Dean
Co-ordinator/HoD, Dept. of Radiography
Senior Assistant Registrar