

See discussions, stats, and author profiles for this publication at: <https://www.researchgate.net/publication/334069787>

# Bevacizumab versus ziv-aflibercept in branch retinal vein occlusion

Article in *Indian Journal of Ophthalmology* · July 2019

DOI: 10.4103/ijoo.IJO\_1532\_18

CITATIONS

0

READS

30

5 authors, including:



**Imoro Zeba Braimah**

University of Ghana

17 PUBLICATIONS 47 CITATIONS

[SEE PROFILE](#)



**Jay Kumar Chhablani**

University of Pittsburgh

357 PUBLICATIONS 1,969 CITATIONS

[SEE PROFILE](#)

Some of the authors of this publication are also working on these related projects:



Optic neuropathy [View project](#)



Combined Hamartoma of Retina and Retinal Pigment Epithelium [View project](#)

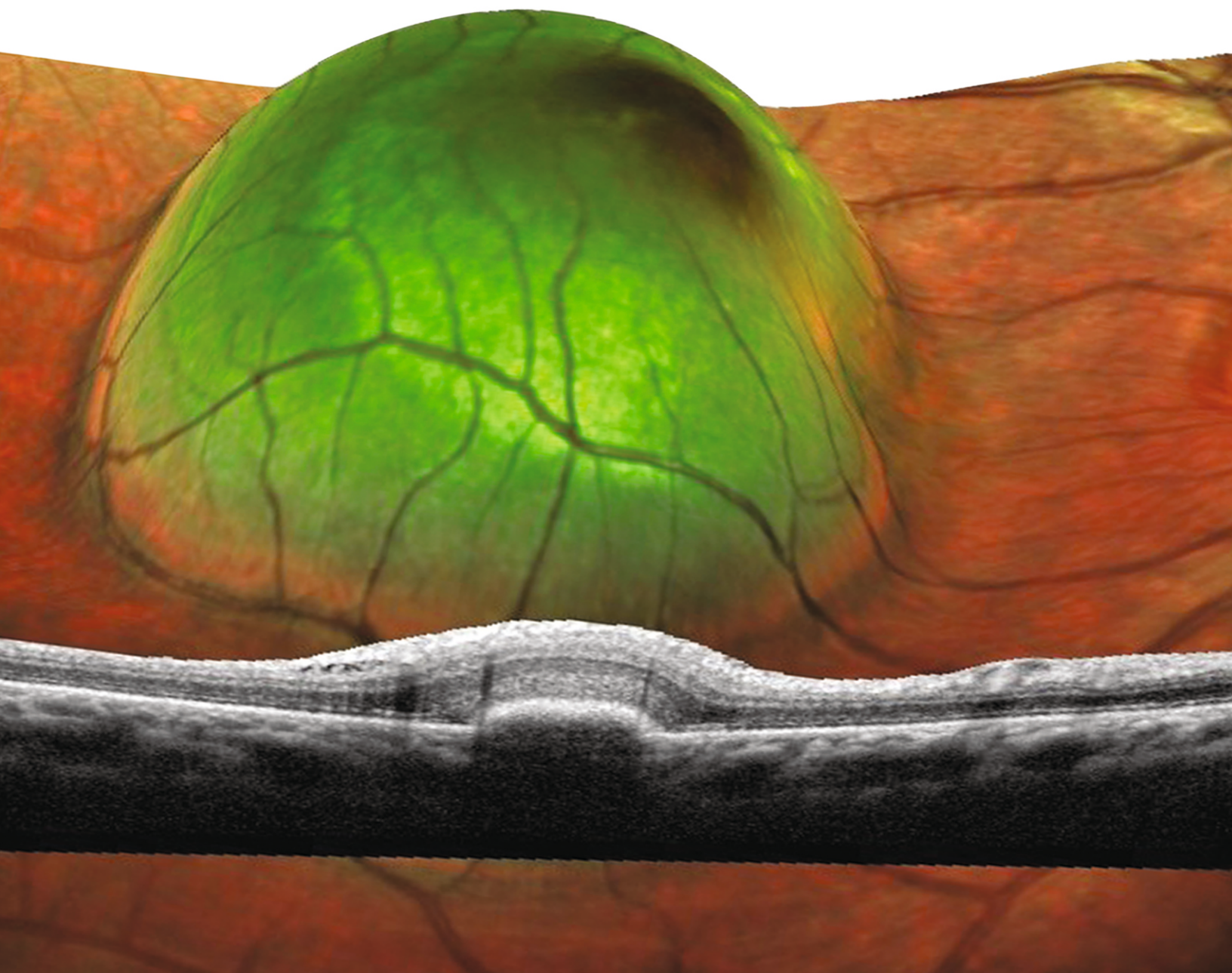
# ijo

## Indian Journal of Ophthalmology



official journal of  
ALL INDIA OPHTHALMOLOGICAL SOCIETY

ISSN : 0301-4738  
Vol 67, Issue 07, July 2019



 Wolters Kluwer



Open access at  
<http://www.ijo.in>

Learn ● Educate ● Evolve

Medknow

## Bevacizumab versus ziv-aflibercept in branch retinal vein occlusion

Imoro Z Braimah<sup>1,2</sup>, Sumit Randhir Singh<sup>3,4</sup>, Bhushan Uplanchiwar<sup>3</sup>, Ahmad M Mansour<sup>5,6</sup>, Jay Chhablani<sup>3</sup>

**Purpose:** To compare the effectiveness of treatment with intravitreal bevacizumab (IVB) and ziv-aflibercept (IVZ) in patients with macular edema (ME) post-branch retinal vein occlusion (BRVO). **Methods:** Patients with treatment naïve ME post-BRVO were included retrospectively if they received either IVB (0.05 ml/1.25 mg) or IVZ (0.05 ml/1.25 mg) monotherapy with a follow up of 12 months. **Results:** Thirty-two and 17 eyes received IVB and IVZ, respectively. The mean improvement in best corrected visual acuity (BCVA) was  $0.36 \pm 0.3$  logarithm of minimum angle of resolution (logMAR) in the IVB group and  $0.27 \pm 0.3$  in the IVZ group ( $P = 0.35$ ). The mean change in central macular thickness was  $178.9 \pm 180.9$  and  $173.5 \pm 344.4 \mu\text{m}$  in IVB and IVZ groups, respectively ( $P = 0.94$ ). The mean number of injections was higher in the IVB group ( $4.0 \pm 1.8$ ) compared with  $1.82 \pm 0.8$  in the IVZ group ( $P < 0.0001$ ). The IVZ group had significantly fewer number of visits ( $P < 0.0001$ ) and longer maximum treatment-free intervals ( $P = 0.0081$ ). **Conclusion:** IVZ appears to be cost-effective with the similar visual outcome and less number of visits in comparison to IVB.

**Key words:** Branch retinal venous occlusion, bevacizumab, Ziv-aflibercept, macular edema, optical coherence tomography

Branch retinal vein occlusion (BRVO) is the most common type of retinal vein occlusion with a reported prevalence rate of 4.42 cases per 1000.<sup>[1]</sup> The cause of significant visual loss in the majority of the patients is because of macular edema (ME) or macular ischemia.<sup>[1]</sup> Vascular endothelial growth factors (VEGF) have been proven to play an important role in the pathogenesis of ME in BRVO.<sup>[2]</sup> Anti-VEGF agents such as aflibercept (IVA), bevacizumab (IVB), and ranibizumab (IVR) have been found to be safe and effective in the treatment of BRVO.<sup>[3-6]</sup> IVB has been used as an off-label drug for the treatment of ME in BRVO with successful functional and anatomic outcomes through 6–24 months.<sup>[4,5,7-9]</sup>

Ziv-aflibercept is an intravenous formulation approved for the treatment of metastatic colorectal cancer<sup>[10]</sup> and there are few reports of the safety and efficacy of intravitreally administered off-label intravitreal ziv-aflibercept (IVZ) in patients with BRVO.<sup>[11-13]</sup> IVZ is a similar molecule to IVA with a higher osmolality in IVZ leading to concerns of intraocular toxicity.<sup>[14]</sup> A head-to-head comparison of IVA and IVB in treatment naïve BRVO cases with ME showed no significant differences in best corrected visual acuity (BCVA), central macular thickness (CMT), and mean number of injections at 12 months.<sup>[15]</sup> IVA has been found to prolong the interval of treatment after switching therapy from IVB or IVR in eyes with

ME associated with BRVO.<sup>[16,17]</sup> Few reports have also shown the clinical outcomes of IVZ through 1 year.<sup>[11,12]</sup> However, a comparison between IVB and IVZ has not been reported in the literature.

The cost of IVA and IVR per dose are \$1850 and \$1170, respectively, while that for off-label IVB and IVZ are \$50 and \$30 per dose, respectively.<sup>[14,18]</sup> However, both IVB and IVZ require compounding before ocular use.<sup>[13]</sup> IVB is the most commonly used anti-VEGF worldwide for the treatment of retinal vascular diseases including ME associated with BRVO.<sup>[19]</sup> IVZ has a similar cost to IVB and could be used as an alternative if found to be safe and efficacious as IVB. In view of the rising cost of treatment with anti-VEGF agents, treatments that are relatively cost-effective are needed. The purpose of this study is to compare the effectiveness of treatment with IVB and IVZ monotherapy in patients with ME secondary to BRVO through 12 months.

### Methods

In this retrospective two-center comparative interventional study, patients with ME associated with BRVO who had been treated with intravitreal monotherapy of either IVB (1.25 mg/0.05 mL) or IVZ (1.25 mg/0.05 mL) from January 2014 to April 2017 were included. A total of 12 (BVZ group) and 7 (IVZ group) patients were treated in Lebanon and the remaining patients were treated in India. Institutional review

This is an open access journal, and articles are distributed under the terms of the Creative Commons Attribution-NonCommercial-ShareAlike 4.0 License, which allows others to remix, tweak, and build upon the work non-commercially, as long as appropriate credit is given and the new creations are licensed under the identical terms.

For reprints contact: reprints@medknow.com

Cite this article as: Braimah IZ, Singh SR, Uplanchiwar B, Mansour AM, Chhablani J. Bevacizumab versus ziv-aflibercept in branch retinal vein occlusion. Indian J Ophthalmol 2019;67:1109-13.

#### Access this article online

Website:

www.ijo.in

DOI:

10.4103/ijo.IJO\_1532\_18

#### Quick Response Code:



<sup>1</sup>Department of Surgery, School of Medicine and Dentistry, University of Ghana, <sup>2</sup>Eye Centre, Korle-Bu Teaching Hospital, Korle-Bu, Accra, Ghana, <sup>3</sup>Smt. Kanuri Santhamma Centre for Vitreo-Retinal Diseases, L V Prasad Eye Institute, Hyderabad, <sup>4</sup>Retina and Uveitis Department, GMR Varalakshmi Campus, LV Prasad Eye Institute, Hanumanthawaka Junction, Visakhapatnam, Andhra Pradesh, India, <sup>5</sup>Department of Ophthalmology, American University of Beirut, <sup>6</sup>Department of Ophthalmology, Rafik Hariri University Hospital, Beirut, Lebanon

**Correspondence to:** Dr. Jay Chhablani, Smt. Kanuri Santhamma Centre for Vitreo-Retinal Diseases, L V Prasad Eye Institute, Banjara Hills, Hyderabad - 34, India. E-mail: jay.chhablani@gmail.com

**Manuscript received:** 30.10.18; **Revision accepted:** 07.02.19



board approval was obtained from both participating centers, and the study adhered to the tenets of Declaration of Helsinki. Written informed consent was obtained from all the study patients.

Eligible patients were those who were treatment-naïve with ME secondary to BRVO treated with either IVB or IVZ monotherapy with a minimum follow up of 12 months. All patients with ME secondary to BRVO who were treated previously, those with a follow up of <12 months, uncontrolled systemic parameters, and advanced glaucoma were excluded from this study.

All patients underwent complete ocular examination including BCVA, anterior segment, and dilated fundus examination using slit-lamp biomicroscopy and indirect ophthalmoscopy. Early Treatment Diabetic Retinopathy Study (ETDRS) R chart (Precision Vision, La Salle, Illinois, USA) was used to assess BCVA in Lebanon while Snellen charts were used in India. CMT on optical coherence tomography (OCT) was measured using three-dimensional OCT-2000 FA plus Topcon (Topcon, Tokyo, Japan) in both the centers and Cirrus HD-OCT (Carl Zeiss Meditec, Dublin, California, USA) in India. Fundus fluorescein angiography (Zeiss Visupac® FF4 and FF450-plus, Carl Zeiss, Dublin, CA) was done in cases with persistent macular edema, suspicion of neovascularization or vitreous hemorrhage.

Aliquots of IVB and IVZ were prepared using techniques described earlier and were discarded at 2 weeks if unused.<sup>[13]</sup> Intravitreal injections were given after instillation of povidone iodine. No preinjection and postinjection antibiotics were used. Re-treatment was required in cases of persistence or recurrence of the intraretinal or subretinal fluid (IRF/SRF) on OCT scan, CMT >250  $\mu\text{m}$ , and reduction in BCVA by  $\geq 0.1$  logMAR. Follow-up visits included monthly visit till the complete anatomical success (no subretinal or intra-retinal fluid and/or CMT  $\leq 250$   $\mu\text{m}$ ) then 2 monthly visit for next 4 months, followed by 3 monthly till 1 year. In case of recurrence, monthly follow-up visits were done, till the complete anatomical success. Any ocular or systemic side effects were noted and were considered injection or procedure related if occurred within 1 month of intravitreal injections.<sup>[20]</sup>

Macular laser photocoagulation was considered as rescue treatment in situations such as suboptimal response or recurrence of ME. The decision regarding retreatment was as per the discretion of the treating physician. The suboptimal response was defined as BCVA of  $\leq 20/40$ , persistence of IRF/SRF, or presence of leakage in fluorescein angiography (if performed). Recurrence was defined as CMT  $\geq 250$   $\mu\text{m}$ , presence of IRF/SRF, and/or reduction in BCVA  $\geq 0.1$  logMAR in the patients with documented dry macula previously. PASCAL (Pattern Scan Laser; Optimedica Corp., Santa Clara, California, USA), a 532 nm frequency-doubled (Nd: YAG) laser was used for administration of laser with a 10 ms exposure.<sup>[21,22]</sup> Laser application was done using contact lens with a spot magnification factor of 1 at the areas of leakage on FFA, 500  $\mu\text{m}$  away from the center of FAZ or to areas of retinal thickening based on clinical assessment.

#### Statistical analysis

SPSS V.24 (IBM, Chicago, Illinois, USA) was used for statistical analysis. Visual acuities were converted to logarithm of

minimum angle of resolution (logMAR) for statistical analysis. Categorical variables were compared using Chi-square test and continuous variables were compared using independent *t*-test. The effectiveness of treatment between these two treatment regimens was compared using the following outcome measures: the mean BCVA change in logMAR, mean number of injections, mean number of visits, and the maximum treatment-free interval through 1 year. A *P* value of <0.05 was considered statistically significant.

## Results

Forty-nine eyes of 49 patients with a mean age of  $57.2 \pm 11.4$  years (IVB:  $54.2 \pm 9.1$ ; IVZ:  $58.8 \pm 14.5$  years) were included in this study. Thirty-two eyes received IVB, whereas 17 eyes received IVZ. The duration of the disease was  $2.9 \pm 1.6$  and  $3.1 \pm 1.2$  months in BVZ and IVZ groups, respectively (*P* = 0.65). The mean baseline BCVA (logMAR) was 0.61 (Snellen's equivalent 20/80) in the IVB and 0.63 (Snellen's equivalent 20/85) in the IVZ group (*P* = 0.78). The mean baseline CMT was 481.7  $\mu\text{m}$  in the IVB group and 460  $\mu\text{m}$  in the IVZ group (*P* = 0.94). The baseline clinical characteristics such as age, gender, BCVA, and CMT were comparable between the two groups [Table 1].

The mean ( $\pm$ standard deviation) number of injections through 12 months were  $4.0 \pm 1.8$  in the IVB group compared with  $1.82 \pm 0.81$  in the IVZ group (*P* < 0.0001). Overall, comprising both groups, there was significant improvement in the BCVA (logMAR) at 12 months compared with baseline ( $0.19 \pm 0.39$  vs  $0.63 \pm 0.53$ ) (*P* < 0.0001) and also there was significant reduction in the CMT at 12 months ( $297.2 \pm 136.4$  vs  $474.0 \pm 205.4$ ) (*P* < 0.0001). The mean improvement in BCVA at 12 months was  $0.36 \pm 0.3$  in the IVB group and  $0.27 \pm 0.3$  in the IVZ group (*P* = 0.35). The mean change in CMT was  $178.9 \pm 180.9$   $\mu\text{m}$  in the IVB group and  $173.5 \pm 344.4$   $\mu\text{m}$  in the IVZ group (*P* = 0.94). IVZ treatment group had a significantly fewer number of visits (*P* < 0.0001) and longer duration of treatment-free interval (*P* = 0.0081) as shown in Table 1. Age, gender, treatment given, baseline CMT, and the number of intravitreal injections were not significantly associated with the change in BCVA at 1 year except for the baseline BCVA (*P* < 0.0001). Representative cases are shown in Figs. 1 and 2.

Thirteen eyes received focal (grid) laser photocoagulation due to suboptimal response or recurrence of macular edema in the group that received IVB. Prior to laser, the mean number of injections was  $2.4 \pm 0.7$  in the BVZ group. There was a statistically significant change in mean ( $\pm$ SD) BCVA ( $0.29 \pm 0.19$  logMAR; *P* = 0.01) and CMT ( $242.8 \pm 192.0$   $\mu\text{m}$ ; *P* = 0.02) in 13 eyes which received rescue focal laser. The mean number of injections and maximum treatment-free interval were  $5.5 \pm 1.9$  and  $4.17 \pm 1.47$  months, respectively. Post-grid laser photocoagulation, repeat intravitreal injections were given after at least 3 months based on BCVA and CMT. One eye each from IVB and IVZ groups had sector laser photocoagulation because of associated vitreous hemorrhage and presence of retinal neovascularization, respectively. There were no ocular or systemic adverse events related to intravitreal injections.

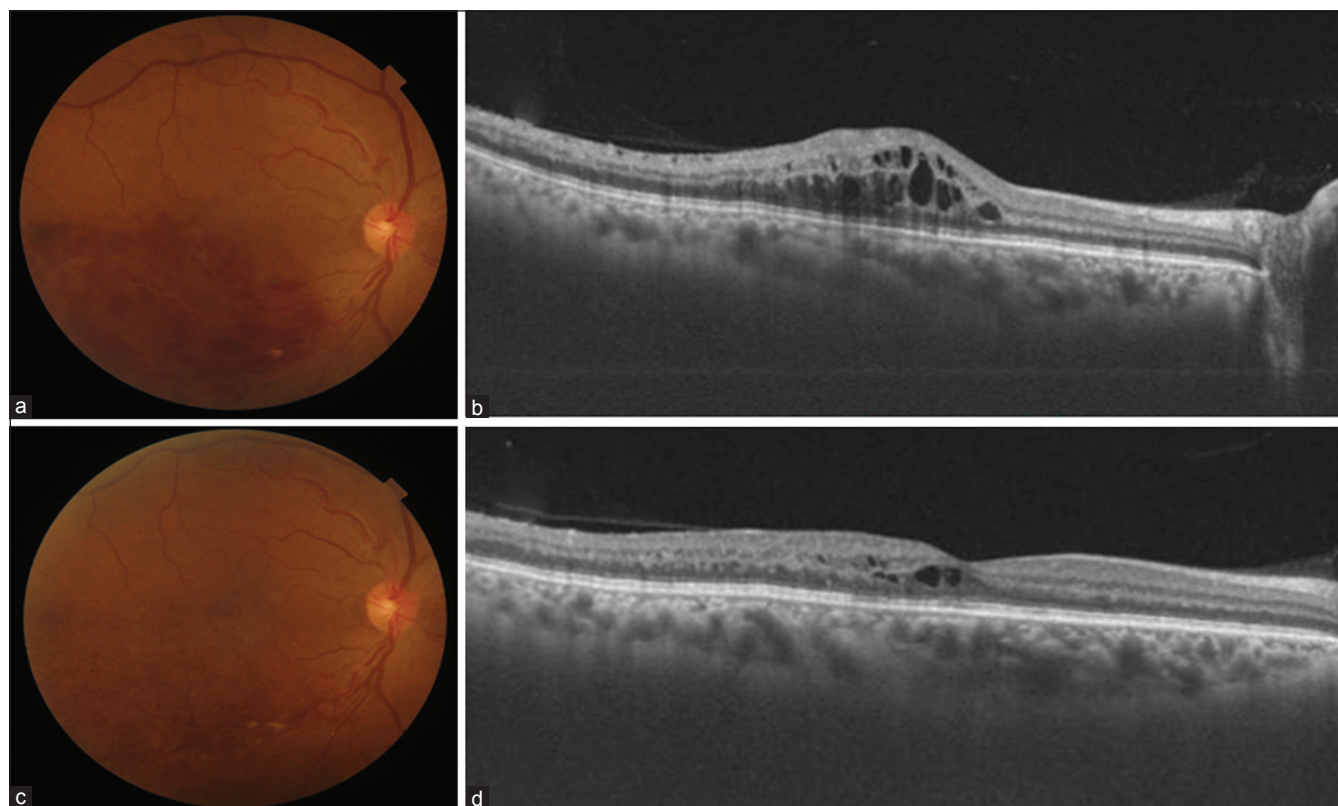
## Discussion

In this retrospective comparative interventional study, we found no difference in the anatomic and visual outcomes at

**Table 1: Clinical characteristics of eyes (including BCVA in the logarithm of minimum angle of resolution; logMAR; CMT with macular edema secondary to branch retinal vein occlusion treated with bevacizumab (IVB) and ziv-aflibercept (IVZ) through 12 months**

| Parameters                                   | IVB                | IVZ                     | P value    |
|----------------------------------------------|--------------------|-------------------------|------------|
| Total number of eyes                         | 32                 | 17                      | (2-tailed) |
| Age, mean±SD (range; years)                  | 54.2±9.1 (54-60.5) | 58.76±14.52 (51.3-66.2) | 0.18       |
| Sex (male/female)                            | 17/15              | 9/8                     |            |
| Baseline BCVA (logMAR), mean±SD              | 0.61±0.50          | 0.63±0.62               | 0.78       |
| Final BCVA (logMAR), mean±SD                 | 0.13±0.34          | 0.31±0.48               |            |
| Change in BCVA at 12 months                  | -0.36±0.3          | -0.27±0.3               | 0.35       |
| Baseline CMT (mean±SD; μ)                    | 481.7±168.2        | 460±274.5               | 0.94       |
| Final CMT (mean±SD; μ)                       | 303±112.5          | 286.5±177.6             |            |
| CMT change at 12 months                      | 178.9±180.9        | 173.5±344.4             | 0.94       |
| Total number of injections, mean±SD          | 4.0±1.8            | 1.82±0.81               | <0.0001    |
| Total number of visits, mean±SD              | 8.7±2.1            | 5.0±1.2                 | <0.0001    |
| Maximum treatment-free interval (mean±SD; m) | 5.0±1.6            | 6.4±1.9                 | 0.008      |

BCVA: best corrected visual acuity, CMT: central macular thickness, IVB: intravitreal bevacizumab, IVZ: intravitreal ziv-aflibercept, m: months, SD: standard deviation

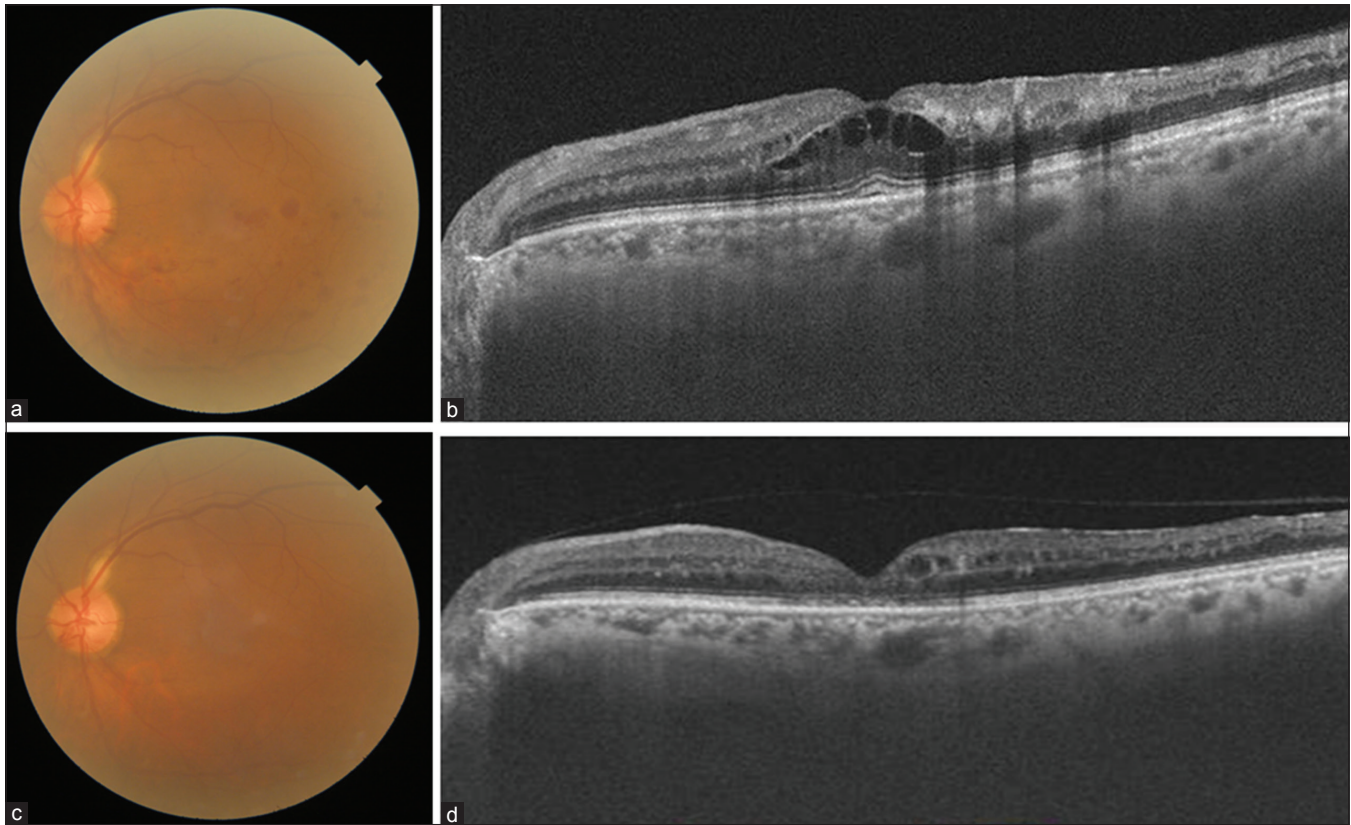


**Figure 1:** (a) Fundus photograph of a 57-year-old female with the presence of dilated, tortuous vein and multiple superficial hemorrhages in inferotemporal quadrant suggestive of branch retinal vein occlusion. Best corrected visual acuity (BCVA) was 20/60 in the right eye and optical coherence tomography (OCT) showed cystoid spaces and macular edema (b). Post two intravitreal bevacizumab (IVB) injections, BCVA improved to 20/50. Fundus photograph showed resolving retinal hemorrhages (c) and few cystoid spaces with nearly resolved macular edema (d) at 6 months

1 year, among patients with branch retinal vein occlusion who received IVB compared with IVZ. However, patients who received IVZ compared with IVB significantly received a fewer mean number of injections (1.8 vs. 4.0), required fewer number of hospital visits (5.0 vs. 8.7), and had a longer treatment-free interval (6.4 months vs. 5.0 months).

Studies have shown good visual and anatomical outcomes in ME associated with BRVO with both IVB and IVZ.<sup>[4,8,9,11,12]</sup> However, there are no studies comparing IVB and IVZ in BRVO-related ME. Ehlers *et al.* have reported significant improvement in BCVA (20/137 to 20/96;  $P = 0.05$ ), CMT (425 μm to 289 μm;  $P < 0.001$ ) with a mean of 2.5 IVB injections





**Figure 2:** (a) Fundus photograph of 63-year-old male with the presence of inferotemporal branch retinal vein occlusion and best corrected visual acuity of 20/60. Optical coherence tomography (OCT) showed cystoid macular edema (CME), hard exudates, and shallow neurosensory detachment (NSD) (b). Post three intravitreal ziv-aflibercept injections at 1, 7, and 11 months, BCVA improved to 20/50. Fundus photograph showed resolved hemorrhages (c) while OCT showed foveal thinning, few cystoid spaces with disrupted ellipsoid zone (d) at month 14

in previously treated eyes with BRVO-related ME through 9 months.<sup>[4]</sup> Hikichi *et al.* in their study of 105 treatment naïve eyes with ME due to BRVO reported a significantly improved visual outcome (logMAR  $0.64 \pm 0.24$  to  $0.34 \pm 0.21$ ) at 2 years with a mean of  $3.8 \pm 1.5$  IVB injections.<sup>[9]</sup>

Chan *et al.* have shown successful outcomes of IVZ in treatment naïve eyes with BRVO-related ME. In the 11 eyes treated through 12 months, best corrected visual acuity (BCVA) improved significantly ( $0.33 \pm 0.22$ ;  $P < 0.05$ ) with  $3.3 \pm 1.6$  mean number of injections on PRN protocol.<sup>[12,16]</sup> Paulose *et al.* in a small series of nine eyes of persistent or recurrent ME because of RVO (both branch and central) reported modest improvement in BCVA ( $\Delta = -0.29$  logMAR;  $P = 0.13$ ) with a significant reduction in CMT ( $604 \pm 199 \mu\text{m}$  to  $351 \pm 205 \mu\text{m}$ ;  $P = 0.02$ ) at 4 months.<sup>[11]</sup>

Though IVA and IVZ share same molecular structure, the difference exists in the osmolarity (IVA: 300 mOsm/kg vs IVZ: 1000 mOsm/kg) owing to the difference in purification methods and use of different buffer solutions.<sup>[14]</sup> Studies have shown the comparable results of IVA with IVB in BRVO and few of them showed increased treatment interval with IVA in patients with insufficient response to IVB even if the visual outcomes were not different.<sup>[15-17]</sup> Wang *et al.* did not find any significant difference in the visual and anatomic outcomes (BCVA, CMT, and mean number of injections) in a retrospective study of 50 eyes with ME associated with BRVO treated with IVA and IVB.<sup>[15]</sup> Switching to IVA in patients of ME related to BRVO with insufficient response to IVB or IVR has shown a significant increase in injection

interval (5.0–8.3 weeks at month 12;  $P = 0.002$ ). However, there was no significant improvement in BCVA and CMT.<sup>[16]</sup> Direct extrapolation of treatment response with IVA to IVZ may be difficult in view of different dosages (IVA: 2 mg vs. IVZ: 1.25 mg) and the difference in osmolarity.<sup>[14]</sup>

The overall cost of treatment with intravitreal anti-VEGF agents includes the cost of transport to the hospital, hospital user fees, cost of investigations such as OCT, fluorescein angiography, cost of the anti-VEGF drug, and time spent by the patient and the attendant. The cost of compounded IVB and IVZ per dose is almost similar (\$50 and \$30 per dose, respectively).<sup>[13,18]</sup> There are higher cost implications involved in using IVA or IVR as compared with IVB or IVZ which can be up to 20–30 times.<sup>[23]</sup> Van Asten *et al.* have shown that the preference of IVA over IVB in neovascular age-related macular degeneration (n-AMD) leads to annual overspending to the tune of €335 million in Europe.<sup>[24]</sup> In this study, patients with BRVO had on average two injections of IVZ compared with four injections of IVB at 1 year making IVZ even a cheaper alternative to IVB. The use of IVZ in the treatment of patients with BRVO may reduce the cost of treatment at 1 year by 50% compared with IVB. This can benefit the patients especially in developing and low-middle-income countries where insurance coverage is very limited. A reduction in the number of hospital visits among patient receiving IVZ can lead to further cost savings. In this study, we found that patients with BRVO who received IVZ had on average five hospital visits during

1 year compared with eight hospital visits among those who received IVB.

Study limitations include small sample size with an uneven distribution of patients in both the groups (IVB = 32; IVZ = 17) and outcome analysis at only 1 year. Being a retrospective study, we could not include the patients who did not come for the follow-up but had a good visual outcome. Therefore, we may have probably included only patients who had a poor outcome and needed further treatment. As the dose for IVZ (1.25 mg) is less than approved IVA (2 mg), therefore, a bi-monthly protocol could not be followed. Mean number of injections were relatively less in both groups and the results bear a resemblance to other real-life studies on anti-VEGF therapy in ME secondary to BRVO.<sup>[4,9,12]</sup> Moreover, this study has been done in two different populations. Therefore, the ethnic variation also needs to be kept in mind before analyzing the results.

## Conclusion

In conclusion, IVZ appears to be cost-effective with a similar visual outcome and less number of visits in comparison with IVB. Our study supports IVZ as a low-cost alternative to approve IVA in a real-life situation. However, a head-to-head comparison between these two molecules is needed to arrive at a conclusion.

## Financial support and sponsorship

Nil.

## Conflicts of interest

There are no conflicts of interest.

## References

- Rogers S, McIntosh RL, Cheung N, Lim L, Wang JJ, Mitchell P, *et al.* The prevalence of retinal vein occlusion: Pooled data from population studies from the United States, Europe, Asia, and Australia. *Ophthalmology* 2010;117:313-9.e1.
- Koss MJ, Pfister M, Rothweiler F, Michaelis M, Cinatl J, Schubert R, *et al.* Comparison of cytokine levels from undiluted vitreous of untreated patients with retinal vein occlusion. *Acta Ophthalmol* 2012;90:e98-103.
- Clark WL, Boyer DS, Heier JS, Brown DM, Haller JA, Vittit R, *et al.* Intravitreal aflibercept for macular edema following branch retinal vein occlusion: 52-week results of the VIBRANT study. *Ophthalmology* 2016;123:330-6.
- Ehlers JP, Decroos FC, Fekrat S. Intravitreal bevacizumab for macular edema secondary to branch retinal vein occlusion. *Retina* 2011;31:1856-62.
- Rabena MD, Pieramici DJ, Castellarin AA, Ma'an AN, Avery RL. Intravitreal bevacizumab (Avastin) in the treatment of macular edema secondary to branch retinal vein occlusion. *Retina* 2007;27:419-25.
- Campochiaro PA, Heier JS, Feiner L, Gray S, Saroj N, Rundle AC, *et al.* Ranibizumab for macular edema following branch retinal vein occlusion: Six-month primary end point results of a phase III study. *Ophthalmology* 2010;117:1102-12.e1.
- Parodi MB, Iacono P, Bandello F. Subthreshold grid laser versus intravitreal bevacizumab as second-line therapy for macular edema in branch retinal vein occlusion recurring after conventional grid laser treatment. *Graefes Arch Clin Exp Ophthalmol* 2015;253:1647-51.
- Abegg M, Tappeiner C, Wolf-Schnurrbusch U, Barthelmes D, Wolf S, Fleischhauer J. Treatment of branch retinal vein occlusion induced macular edema with bevacizumab. *BMC Ophthalmol* 2008;8:18.
- Hikichi T, Higuchi M, Matsushita T, Kosaka S, Matsushita R, Takami K, *et al.* Two-year outcomes of intravitreal bevacizumab therapy for macular oedema secondary to branch retinal vein occlusion. *Br J Ophthalmol* 2014;98:195-9.
- Perkins SL, Cole SW. Ziv-aflibercept (Zaltrap) for the treatment of metastatic colorectal cancer. *Ann Pharmacother* 2014;48:93-8.
- Paulose R, Chhablani J, Dedhia CJ, Stewart MW, Mansour AM. Intravitreal ziv-aflibercept for macular edema following retinal vein occlusion. *Clin Ophthalmol* 2016;10:1853-8.
- Chan EW, Eldeeb M, Dedhia CJ, Mansour A, Chhablani J. One-year treatment outcomes of ziv-aflibercept for treatment-naïve macular oedema in branch retinal vein occlusion. *Acta Ophthalmol* 2018;96:e256-7.
- Singh SR, Dogra A, Stewart M, Das T, Chhablani J. Intravitreal Ziv-Aflibercept: Clinical Effects and Economic Impact. *Asia Pac J Ophthalmol (Phila)* 2017;6:561-8.
- Mansour AM, Al-Ghadban SI, Yunis MH, El-Sabban ME. Ziv-aflibercept in macular disease. *Br J Ophthalmol* 2015;99:1055-9.
- Wang JK, Su PY, Hsu YR, Chen YJ, Chen FT, Tseng YY. Comparison of the efficacy of intravitreal aflibercept and bevacizumab for macular edema secondary to branch retinal vein occlusion. *J Ophthalmol* 2016;2016:8421940.
- Wirth MA, Becker MD, Graf N, Michels S. Aflibercept in branch retinal vein occlusion as second line therapy: Clinical outcome 12 months after changing treatment from bevacizumab/ranibizumab—a pilot study. *Int J Retina Vitreous* 2016;2:20.
- Tagami M, Sai R, Fukuda M, Azumi A. Prolongation of injection interval after switching therapy from ranibizumab to aflibercept in Japanese patients with macular edema secondary to branch retinal vein occlusion. *Clin Ophthalmol* 2017;11:403-8.
- Mansour AM, Ashraf M, Dedhia CJ, Charbaji A, Souka AA, Chhablani J. Long-term safety and efficacy of ziv-aflibercept in retinal diseases. *Br J Ophthalmol* 2017;101:1374-6.
- Shah GK, Stone TW, eds. 2017 Global Trends in Retina Survey: 14. Chicago, IL: American Society of Retina Specialists; 2017.
- Singh SR SM, Chattannavar G, *et al.* Safety of 5914 intravitreal ziv-aflibercept injections. *Br J Ophthalmol* 2018. pii: bjophthalmol-2018-312453. doi: 10.1136/bjophthalmol-2018-312453.
- Kozak I, Luttrull JK. Modern retinal laser therapy. *Saudi J Ophthalmol* 2015;29:137-46.
- Donati S, Barosi P, Bianchi M, Al Oum M, Azzolini C. Combined intravitreal bevacizumab and grid laser photocoagulation for macular edema secondary to branch retinal vein occlusion. *Eur J Ophthalmol* 2012;22:607-14.
- Ross EL, Hutton DW, Stein JD, Bressler NM, Jampol LM, Glassman AR. Cost-effectiveness of aflibercept, bevacizumab, and ranibizumab for diabetic macular edema treatment: Analysis from the diabetic retinopathy clinical research network comparative effectiveness trial. *JAMA Ophthalmol* 2016;134:888-96.
- van Asten F, Michels CT, Hoyng CB, van der Wilt GJ, Klevering BJ, Rovers MM, *et al.* The cost-effectiveness of bevacizumab, ranibizumab and aflibercept for the treatment of age-related macular degeneration—A cost-effectiveness analysis from a societal perspective. *PLoS One* 2018;13:e0197670.